

Renal pseudoenlargement secondary to retroperitoneal liposarcoma

GARY J. WHITMAN, MD; SCOTT A. WEGRYN, MD; GARY K. LAMMERT, MD

■ A case of renal pseudoenlargement caused by a large retroperitoneal mass is reported. An intravenous urogram showed apparent enlargement of the right kidney and a normal left kidney. Computed tomography showed a normal-sized right kidney. The discrepancy was due to magnification produced by marked anterior displacement of the right kidney by a retroperitoneal liposarcoma.

□ INDEX TERMS: RETROPERITONEAL NEOPLASMS; LIPOSARCOMA □ CLEVE CLIN J MED 1992; 59:640-642

UNILATERAL SMOOTH enlargement of a kidney is seen in a wide variety of renal conditions; however, physicians should be aware that processes which displace the kidney can manifest radiographically as apparent unilateral renal enlargement. We report a case of renal pseudoenlargement caused by a large retroperitoneal mass.

CASE PRESENTATION

A 62-year-old white Brazilian man with a history of coronary artery disease presented with epigastric pain, night fever, loss of appetite, and a weight loss of 6 kg over a 6-week period. Physical examination revealed a nontender right upper abdominal mass. The patient did not complain of flank pain.

Excretory urography was performed (*Figure 1*). The scout film (plain film taken before the injection of

contrast) showed inferomedial displacement of the hepatic flexure of the colon, suggesting organomegaly or mass. The right psoas muscle was obscured. The 20-minute film showed marked enlargement of the right renal outline with mild enlargement of the pelvicaliceal system, compared with the opposite side. Bowel loops were displaced inferior to the lower renal margin, suggesting the presence of an abnormal mass.

Computed tomography (CT) revealed a very large retroperitoneal mass displacing the right kidney anteriorly (*Figure 2*). CT-guided biopsy of the mass revealed a sarcoma. The patient underwent surgery, and the mass, a well-differentiated liposarcoma, was nearly totally resected. Postoperative radiation therapy was administered; however, a large local recurrence was detected 23 months after the original surgery.

DISCUSSION

The differential diagnosis for a unilateral, smooth, enlarged kidney on an excretory urogram includes acute glomerulonephritis,¹ acute suppurative pyelonephritis, acute ureteral obstruction, renal vein thrombosis, acute arterial infarction,² and compensatory hypertrophy.³ Apparent unilateral renal enlargement may

From the Department of Radiology, The Cleveland Clinic Foundation.

Address reprint requests to G.K.L., Department of Radiology, The Cleveland Clinic Foundation, 9500 Euclid Avenue, Cleveland, OH 44195.

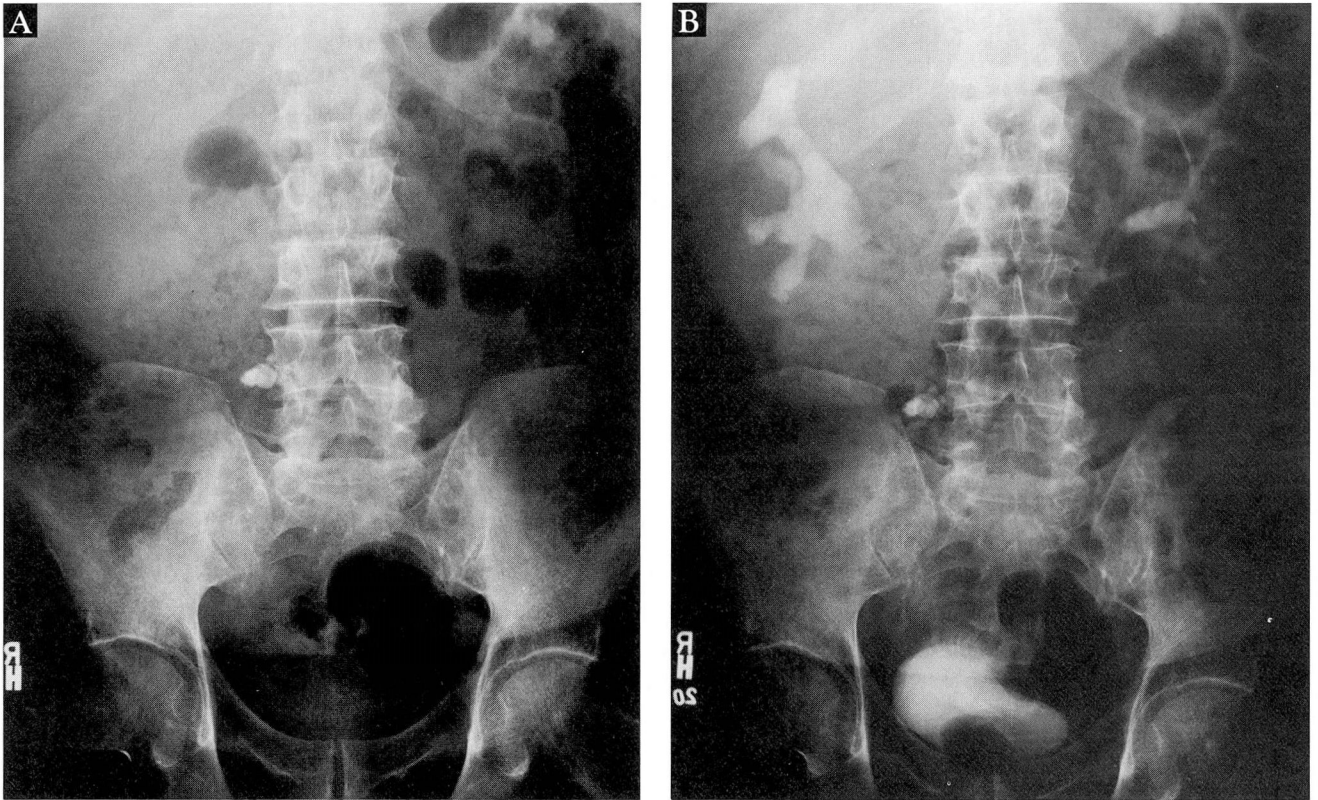


FIGURE 1. Excretory urogram in a 62-year-old white male. Scout film (A) shows inferomedial displacement of the hepatic flexure of the colon. The right psoas muscle is obscured. A calcified mesenteric lymph node is also seen. The 20-minute film (B) shows marked enlargement of the right renal outline with mild pelvicectasis. The left kidney is normal.

be caused by extrinsic masses that displace the kidney, resulting in magnification or pseudoenlargement. This phenomenon has been described in patients with retroperitoneal lymphoma, pancreatic pseudocyst,⁴ hepatomegaly,⁵ and retroperitoneal hemorrhage.⁴

Liposarcomas are a common form of soft-tissue sarcoma with a propensity to occur in the retroperitoneum and the extremities.⁶ They arise from mesenchymal cells and can develop virtually anywhere in the body.⁷ Histologically, liposarcomas are divided into five types: well-differentiated, myxoid, round cell, pleomorphic, and mixed forms. The myxoid type is the most common.⁸

CT is useful in preoperative and postoperative evaluation of liposarcomas. It provides for accurate staging. In addition, attenuation values may correlate with the histologic type (ie, masses with low attenuation represent well-differentiated liposarcomas, whereas masses with high attenuation represent myxoid sarcomas). CT evaluation for local recurrence and response to therapy is well established.^{6,9}

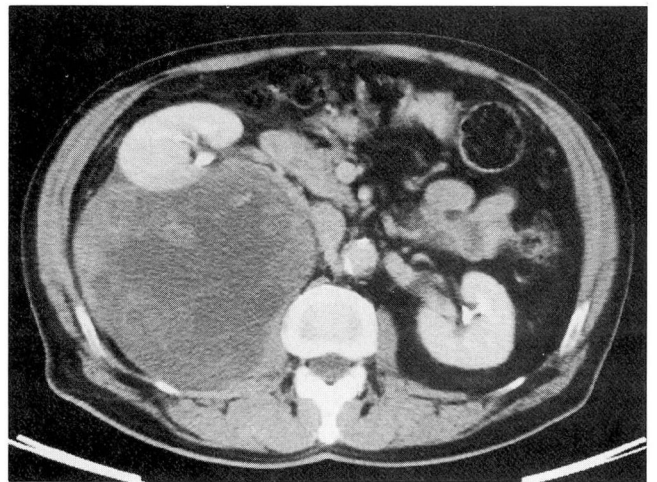


FIGURE 2. Contrast-enhanced CT shows a large heterogeneous retroperitoneal soft-tissue mass displacing the right kidney anteriorly and abutting the right psoas muscle.

Liposarcomas may be well encapsulated, tending to displace rather than invade adjacent structures; they may also merge with adjacent fat or invade local structures, such as muscle.⁹ In this case, the majority of the

tumor appeared well circumscribed on CT, abutting the right psoas muscle. During surgery, the mass was noted to be adherent to the psoas muscle, but pathological examination identified no frank invasion.

REFERENCES

1. Chesney RW, O'Regan S, Kaplan BS, Nogrady MB. Asymmetric renal enlargement in acute glomerulonephritis. *Radiology* 1977; **122**:431-434.
2. Davidson AJ. *Radiology of the Kidney*. Philadelphia: WB Saunders Company, 1985:255-298.
3. Ekelund L, Gothlin J. Compensatory renal enlargement in older patients. *AJR* 1976; **127**:713-715.
4. Levine E, Maklad NF, Bigongiari LR. Renal pseudoenlargement due to masses in posterior pararenal space. *Urology* 1979; **13**:572-574.
5. Nathan H, Zerbino V. Rotation and forward displacement of the right kidney in hepatomegaly. *Anat Clin* 1985; **7**:137-141.
6. deSantos LA, Ginaldi S, Wallace S. Computed tomography in liposarcoma. *Cancer* 1981; **47**:46-54.
7. Cotran RS, Kumar V, Robbins SL. *Robbins' Pathologic Basis of Disease*. Philadelphia: WB Saunders Company, 1989:1374-1375.
8. Kissane JH, editor. *Anderson's Pathology*. St. Louis: CV Mosby Company, 1990:1873-1879.
9. Waligore MP, Stephens DH, Soule EH, McLeod RA. Lipomatous tumors of the abdominal cavity: CT appearance and pathologic correlation. *AJR* 1981; **137**:539-545.

