

TUMORS OF THE RENAL PELVIS

Report of a Case

F. C. SCHLUMBERGER, M. D.

Tumors of the renal pelvis, by reason of their infrequent occurrence and diagnostic complexity, have a special significance not entirely characteristic of other types of renal tumors. These growths are comparatively uncommon and it is generally considered that they comprise from 5 to 7 per cent of all renal tumors. In a series of 341 renal tumors seen at the Cleveland Clinic, 13 or 4.2 per cent were or had their origin in the renal pelvis. It is of interest to note that no such tumor was recorded in this Clinic between January, 1933, and December, 1938. In December, 1938, two cases were seen, one of which is here reported.

REPORT OF CASE

History: The patient was a man, 54 years of age, whose occupation for twenty years had been that of a laborer in a stone quarry. He came to the Clinic on December 14, 1938. His chief complaint was of bloody urine, which had been present for about two months. He had always enjoyed good health with the exception of a chronic cough and shortness of breath. The cough had never been productive. Associated with the hematuria, mild dysuria and occasional nocturia developed. The urine was diffusely red at all times and was not clear on any occasion following the onset of hematuria. He fatigued quite easily and had lost about ten pounds in weight.

The past history was non-revealing. He was a Polish immigrant and contacts with his family had been severed at an early age.

Physical Examination: The patient was a fairly well nourished, well developed man; his temperature was normal; the pulse rate was 72 beats per minute and the blood pressure was 130 systolic and 90 diastolic. He was rather pale but there were no signs of severe, long-standing bleeding.

Examination of the head and neck indicated only improper dental attention. There were no enlarged cervical glands. The chest was somewhat emphysematous with diminished excursion on both sides. There were fine, rather dry râles over the entire lung fields. The heart was not enlarged and its function was good. There were no audible murmurs. The abdomen was not tender and no masses were present. Although there was some tenderness over the right costovertebral area on deep percussion, one could not demonstrate any mass in this region. No tenderness was elicited on the left side and there were no masses present. The genitalia were normal. On digital examination, the prostate was found to be mildly enlarged and benign in character. No varicose veins

were present in the lower extremities and all reflexes showed normal response.

Laboratory Data: The specific gravity of the urine was 1.020, the reaction of the urine was alkaline; there was one plus albumin but no sugar. Microscopically, the specimen was heavily loaded with red blood cells and some pus cells. Complete examination of the blood showed 3,950,000 red blood cells, 68 per cent hemoglobin, and 9,100 white blood cells. Of these, 55 per cent were polymorphonuclear neutrophils, 40 per cent lymphocytes, and 5 per cent monocytes. The value of the sugar determination was 97 mg. and of the urea 54 mg. per 100 cc. of blood. The sedimentation rate was 0.4 mm. and the Wassermann and Kahn tests gave negative reactions.

Roentgen examination of the chest showed a definite silicosis with some evidence of a superimposed tuberculosis in the upper portion of the left lung. Repeated examinations of the sputum were negative for tubercle bacilli and follow-up roentgenograms of the chest also disproved the presence of tuberculosis. Roentgen examination (plain plate) of the kidneys, ureters, and bladder showed normal kidney outline and no suspicious urinary tract shadows; there was a marked osteoarthritis of the spine.

Cystoscopic Examination: The cystoscope was introduced without difficulty and there were about 25 cc. of bloody urine in the bladder. Upon irrigating the bladder it was noted that the return solution cleared readily, suggesting that the bleeding probably was coming from above the bladder. Thorough examination revealed no pathology in the bladder but each efflux of urine from the right ureteral orifice was definitely bloody. Catheters were passed to both kidney pelves without meeting any obstruction. There was an immediate flow of urine from both catheters. That from the right was very bloody and that from the left was clear. Five cc. of indigo carmine were injected intravenously and made its appearance from the left catheter in 4 minutes and from the right in 5 minutes, both in good concentration.

A bilateral pyelogram was made after injecting 8 cc. of solution into each kidney pelvis. The left pyelogram showed a normal kidney. The right (Fig. 1), however, showed a filling defect in the pelvis due either to blood clots or possibly a tumor of the kidney pelvis.

The patient was placed on complete bed rest for six days, at the end of which time the cystoscopic examination was repeated and a right ureteropyelogram was made which showed the same filling defect in the pelvis which was interpreted as probable tumor of the renal pelvis (Fig. 2). The ureter appeared normal and without filling defects.

On December 29, 1938, a right nephrectomy was performed under spinal anesthesia. The kidney was readily exposed and a small mass

TUMORS OF THE RENAL PELVIS

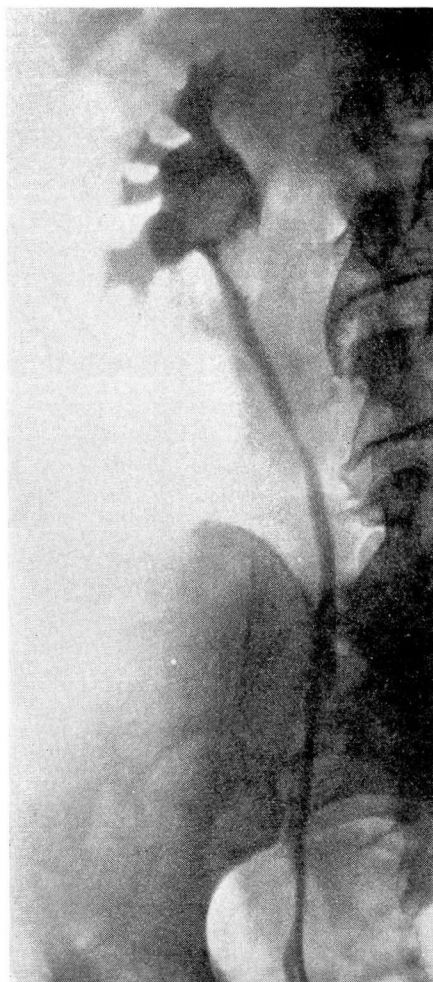

FIGURE 1: Retrograde pyelogram showing a punched-out filling defect, with slightly moth-eaten edges at the ureteropelvic junction of the right kidney, probably a tumor. Overlying this shadow was a larger, less dense filling defect, the edges of which were smoother. This was interpreted as a blood clot.

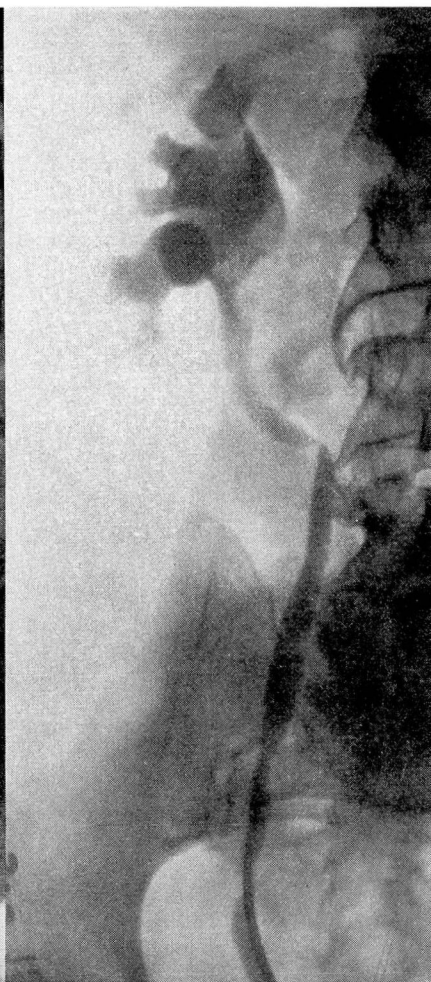

FIGURE 2: Recheck retrograde pyeloureterogram showing the same filling defect and a normal ureter. The final interpretation was tumor at the ureteropelvic junction of the right kidney pelvis.

in the pelvis could be felt on gentle palpation. The ureter was exposed and appeared entirely normal. It was severed as close to the bladder as possible through the kidney incision. The remainder of the procedure was without incident.

The postoperative convalescence was quite uneventful although some difficulty was encountered because of the silicosis demonstrated in the

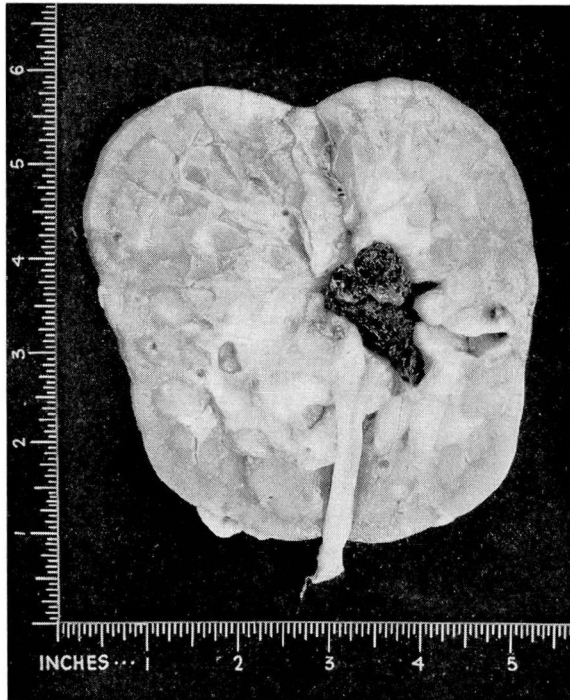


FIGURE 3: Photograph of gross specimen.

chest. The patient was discharged from the hospital on the eighteenth postoperative day.

Pathological Examination: Grossly, the specimen consisted of a fairly normal appearing right kidney and major portion of the right ureter. Gross examination of the sectioned kidney revealed a mildly dilated pelvis filled with a large blood clot. On removing the clot one saw a soft, flat tumor mass, measuring 3 x 2.5 cm. (Fig. 3). This was just at the ureteropelvic junction and extended up into the pelvis. The medullary and cortical tissue otherwise appeared normal. The ureter appeared to be entirely normal with no evidence of implanted tumor tissue.

Histologic examination of sections through the tumor showed a carcinoma arising in the pelvic mucosa and infiltrating the adjacent stroma (Fig. 4).

Diagnosis: Papillary type of carcinoma of the kidney pelvis without evidence of metastasis.

DISCUSSION

Thirteen cases of tumors of the kidney pelvis have been recorded at the Cleveland Clinic. They include papillomas, squamous cell

TUMORS OF THE RENAL PELVIS

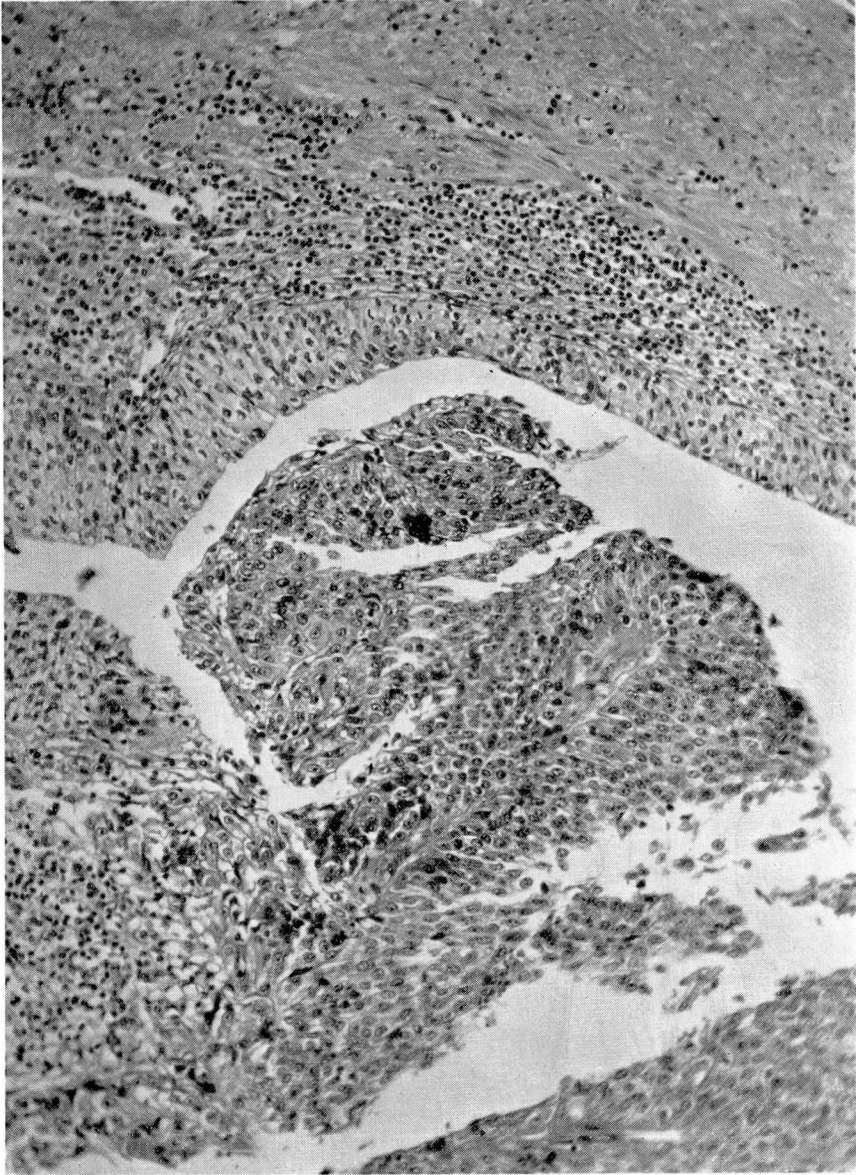

FIGURE 4: Photomicrograph of section through tumor.

carcinoma, and papillary carcinomas. The average age of the patients in this group was 57 years. Twelve tumors occurred in males while only one was found in a female. The side most commonly involved was the left, nine occurring on this side and four on the right.

Symptomatology and Physical Findings: The symptomatology of this group of tumors is similar to that of renal tumors as a whole with

perhaps one or two exceptions. In this group of thirteen patients, hematuria was the only complaint in eight cases, hematuria and pain in four, and frequency was the only complaint in one case. Hematuria, of course, is perhaps the most important symptom in any kidney tumor, but is characterized in tumors of the kidney pelvis by the fact that it often is the only complaint. The bleeding may be painless and this is particularly true in papillary tumors of the kidney pelvis which bleed easily because of the vascularity of the tumor in contrast to the squamous cell type which is relatively avascular.

Pain rarely accompanies hematuria in these cases because, as a rule, the tumor is not large and the kidney is not palpable on physical examination. When pain does occur it is often the result of pelvic block with resulting pyelectasis. In the four cases in which hematuria was accompanied by pain, it was of interest to note that the kidney had enlarged to such proportions that it was definitely palpable. In contrast there is that group of kidney tumors comprised by hypernephromas, Wilms' tumors, and adenocarcinomas, in which one often finds that although hematuria may be present the patient may tell you of a mass which usually is associated with pain. These tumors are also, as a rule, accompanied by extreme loss in weight which is not characteristic of renal pelvic tumors.

Diagnosis: The diagnosis of pelvic tumors is made chiefly by urographic study. Although the majority are associated with profuse hematuria, this finding without definite palpable evidence of renal tumor may be deceptive. Urographic evidence of filling defects in the pelvis and ureter may again be deceptive and does not necessarily represent neoplasm. These defects may occur as a result of a clot, a shadowless calculus, or granulomatous or cystic changes along the ureter and renal pelvis.

Thus a true diagnosis can be established only by thoroughly correlating the urographic findings with the clinical history and cystoscopic findings. If the filling defect is consistently present through repeated retrograde pyelograms, if there is no evidence of chronic infection or stone, and observation is made at intervals between bleeding, the evidence is conclusive that such an abnormality is created by a pelvic tumor. Intravenous urography may be of assistance in certain cases but delineation by this means is seldom as clean-cut as by retrograde pyelography.

Cytological study of the urine may be of great value in the accurate diagnosis of neoplasms of the renal pelvis. Microscopic examination of the sediment in the urine may show bits of tissue which contain tumor cells. This is especially true of the papillary tumors. During the course of ureteral catheterization small pieces of tumor tissue which are

TUMORS OF THE RENAL PELVIS

adequate for cellular identification of tumor tissue may be obtained in the washings from the renal pelvises.

Treatment: The treatment of tumors of the renal pelvis is surgical and varies with the type of tumor encountered. As in all tumors, early diagnosis is essential for the future welfare of the patient. Because the hematuria is often painless, many of these patients are not seen in the early stages of the disease. In the squamous cell type, the growths as a rule have extended beyond hope of cure. Simple nephrectomy in this type is usually all that is necessary as it has little tendency to involve the ureter.

However, in the papillary tumors—benign and malignant—more than nephrectomy is required, although this is the operation which is usually performed first in the majority of instances. Ureterectomy, if not done during the initial procedure, may follow by matter of choice or because of recurrence of the tumor. Ureterectomy should include the intramural portion of the ureter in view of its being the most common point for recurrence or implantation to take place.

Many of these pelvic tumors are not radiosensitive. However, in the light of recent reports on the beneficial effects of radiation on papillary neoplasms of the bladder, it may be deemed advisable to follow this course with kidney tumors. This is entirely dependent upon the findings in each individual case.

Pathology: With few exceptions these tumors are epithelial, the majority being of the papillary variety and very similar to those of the bladder. The papillary tumors constitute about three-fourths of all of the renal pelvic growths. Five of our cases were of the squamous cell type and eight were of the papillary type of varying degrees of malignancy. The truly benign papillomata are apparently of infrequent occurrence. Malignant changes appear to be the rule since many of these tumors remain silent for a long period of time.

The growth may be tall and pedunculated or short and spreading. Multiplicity is common and there may be implantation in the ureter or even the bladder. When the growth is of the flat, spreading type such as the one reported, infiltration is early and a large portion of the kidney may become involved, obliterating its pelvic origin. The cells are usually made up of large, oval, vesicular nuclei, blue-staining cytoplasm, and they have a tendency toward alveolar arrangement. The squamous cell type is usually flat and shows early infiltration with a tendency toward pearl formation. These tumors are often associated with pre-existing factors such as calculi or leukoplakia.

Prognosis: The variable factors in the prognosis of renal neoplasm are notable in that there is a general lack of agreement among numerous

authors and their observations. In the squamous cell type, metastasis is usually widespread when the tumor is found, dissemination through the blood stream being evidenced by lesions in the lungs, liver, and bones. In many cases extension of the local lymphatics has taken place. The true papillary type of tumor offers a ray of hope although local recurrence in the bladder is not uncommon. In our series, five of the thirteen patients died within six months following operation, three of these had had squamous cell carcinoma and two papillary carcinoma. In three of these cases, metastases were demonstrable in the lungs, and in one of the squamous cell types metastasis was generalized. Three patients survived only one year and metastasis to the lungs was demonstrated in one case. One patient survived nephrectomy for epidermoid carcinoma of the kidney pelvis for a period of three years with final metastasis to the lungs and femur. Two patients with papillary carcinoma of the kidney pelvis were alive and well four years after operation. Two cases have been of recent date. We may conclude from this study that the prognosis is very grave where squamous cell carcinoma is proven. In the papillary group of tumors the extensiveness of the growth, the invasiveness and degree of malignancy, and the time of operation largely determine the future outcome of the patient.