

HEPATICODUODENOSTOMY

Report of a Case

T. E. JONES, M. D.

This case is presented as one which is rather typical of an injury to the common duct during cholecystectomy. Anomalies of the duct account for a few accidents, but the majority result from incomplete exposure of the duct during operation or clamping blindly for hemorrhage in cases where the cystic artery slips away from the clamp or the ligature becomes loose. The cystic artery is a branch of the right hepatic and comes off at a level above the cystic duct so that in our cases the damage has invariably been in the hepatic duct at a distance of one-fourth to one inch below the bifurcation of the right and left hepatic duct.

The diagrammatic sketch shown in figure 1 shows also that the right hepatic artery may be clamped and tied off if the hemostats are put on blindly, leading to damage to the right lobe of the liver. In the case reported here, the physician stated that the gallbladder was acutely inflamed and, during the operation, he encountered severe hemorrhage which necessitated the blind application of the hemostat. This can easily

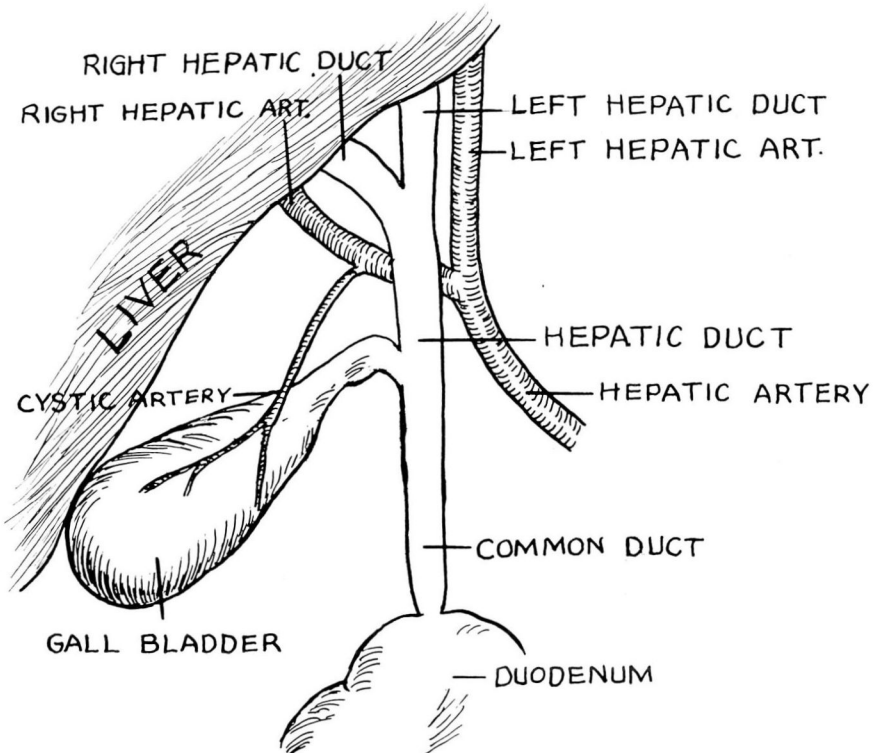


FIGURE 1

be avoided, however, if one places the finger in the foramen of Winslow and compresses the gastric hepatic omentum, through which the main vessels run, between the thumb and forefinger. Then on gradual release of pressure, the one bleeding point may be picked up and drainage to the duct obviated.

I have now performed hepatico- or choledocho-duodenostomies in 10 cases. Most of these were necessary because of injury during cholecystectomy which had not been recognized at the time. At the time of the secondary operation, the lower end of the common duct cannot be recognized in the majority of these cases and in those cases where it is recognized, the distance between the cut ends is frequently too great for anastomosis. Furthermore, in cases where it is possible to anastomose the cut ends, experience has taught us that the likelihood of reformation of the stricture is very great, necessitating further surgery; therefore, it has been our experience that anastomosis to the duodenum gives a much better end result.

CASE REPORT

A man, 32 years of age, was admitted to the Clinic on January 4, 1939, complaining of jaundice and generalized pruritus. Ten months previously, in March, 1938, cholecystectomy for cholelithiasis had been performed elsewhere. The presenting symptom at that time was pain which had been present for three days in the upper part of the abdomen. Jaundice had not been associated with this symptom. The immediate postoperative course had been stormy; jaundice developed and on the fourth day the incision broke down and bile drained from it. However, this had healed within three weeks and the patient was able to leave the hospital.

Mild jaundice without pain persisted with varying intensity until six weeks before entrance to the Clinic when it became more pronounced and was associated with generalized itching. At no time had there been abdominal pain. Stools had varied from yellow to clay in color and the urine had been dark. The past history was negative except that thyroidectomy had been performed for diffuse goiter with hyperthyroidism in July, 1936.

Physical examination revealed a frail young adult who weighed 126 pounds. The temperature was 97.9° F., the pulse rate 80, and respirations 20. The skin presented a moderate icterus and the sclerae were slightly tinged. Recent excoriations due to pruritus were scattered over the trunk and extremities.

Examination of the abdomen revealed the liver to extend one finger's breadth below the costal margin. No other masses and no tenderness was detected.

HEPATICODUODENOSTOMY

On admission, a diagnosis of stricture of the common duct was made.

Blood studies revealed 4,640,000 red blood cells with 87 per cent hemoglobin, 11,500 white cells with 62 per cent polymorphonuclears, and an icterus index of 20 units. The prothrombin time was determined and found to be 15 seconds, 20 seconds being normal.

Twenty cc. of a 10 per cent solution of calcium gluconate, together with 1000 cc. of a 5 per cent solution of glucose in saline was given intravenously each day for five days, affording marked relief from the pruritus. Repeat studies of the blood on the fifth day showed that the icterus index had risen to 25 units while the prothrombin time was 17 seconds.

An exploratory laparotomy was performed January 10, 1939. Hugging the under surface of the liver, adhesions were divided, finally exposing the portion of the hepatic duct about 1 cm. from the liver (Fig. 2A). A probe was passed into the duct which was lightly dilated, liberating a considerable quantity of normal appearing bile. The probe could then be passed easily into the right and left hepatic ducts, the openings of which could be visualized through the end of the hepatic duct. However, on attempting to explore in the downward direction toward the common duct, obstruction was encountered and the common duct could not be demonstrated. The duodenum was mobilized and brought up to approximately the end of the previously dissected common hepatic duct. An opening was made into the duodenum and an anastomosis with the stump of the duct was constructed over the limbs of a T-tube. It was necessary to place one limb in the left hepatic duct in order to make it stay in place (Fig. 2B). It was noted that bile flowed from the long end of the tube and that none escaped at the site of the anastomosis. A transfusion of 500 cc. of citrated blood was given during the operation.

On the second postoperative day the T-tube was clamped off for two hour intervals without causing discomfort or leakage of bile around the

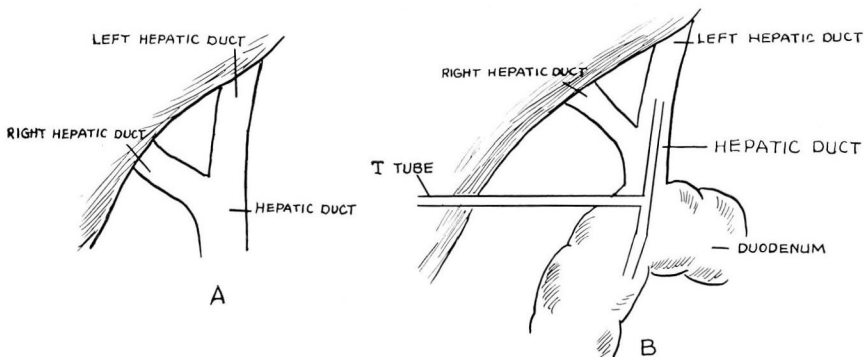


FIGURE 2

T. E. JONES

tube. The following day the clamp was applied continuously without untoward results.

By the sixth day the stools were dark in color and it was apparent that bile was passing into the intestines but the icterus index remained at 20 units. The prothrombin time remained normal and there was no indication of a hemorrhagic tendency.

On the sixteenth day the icterus index had fallen to 10 units and the jaundice had obviously decreased. At the time of discharge on the eighteenth day (January 28, 1939) the patient looked and felt greatly improved, the stools were dark in color, and the tube had remained clamped off without leakage for several days.

When examined twelve days later (February 9, 1939) the patient weighed 133 pounds, a gain of 7 pounds, and the icterus index was 10 units. His appetite was excellent and he felt excellent.