

# BILATERAL SIMULTANEOUS URETEROSIGMOIDOSTOMY FOR CHRONIC INTERSTITIAL CYSTITIS

## *Report of a Case*

WILLIAM E. LOWER, M.D., and F. C. SCHLUMBERGER, M.D.

Transplantation of the ureters into the rectosigmoid is now a recognized procedure in the treatment of various types of intractable lesions of the bladder. Its success has been proved in the treatment of exstrophy of the bladder and, if no complications exist in the upper urinary tract, it may be performed with a relatively low mortality. In carcinoma of the bladder, circumstances often exist which render such an operation more hazardous. Obstruction and infection in the upper urinary tract is more often encountered in such cases. In irremediable vesicovaginal fistulae which have not lent themselves to the usual methods of surgical correction and also in cases of extensive chronic interstitial cystitis, interference with the structure and function of the upper urinary tract occurs less frequently. Consequently, ureteral transplantation is more applicable in these cases.

We wish to present the case of a patient who was disabled with extensive chronic interstitial cystitis. In this instance a bilateral ureterosigmoidostomy was done, both ureters being placed in the rectosigmoid at the same operation.

## REPORT OF CASE

A housewife, 53 years of age, came to the Clinic on March 3, 1939, complaining of severe dysuria, frequency, nocturia, and suprapubic distress; these symptoms had been present for ten years. The initial symptoms had been frequency and mild dysuria. However, she soon began to have some nocturia and noticed that a very small amount of urine was passed at each voiding. The urine was always very clear. A uterine suspension was recommended and carried out elsewhere but this did not add to her comfort. A course of roentgen therapy was given but was of no avail.

The symptoms became increasing more severe. Constant urgency developed and the patient experienced diurnal frequency every half hour and nocturnal frequency equally as often. She finally resorted to the oral administration of morphine sulfate to obtain relief. In 1937 it became necessary for her to take as much as 38 or 40 grains of morphine each week.

Early in 1937, after eight years of suffering, she consulted a urologist and a diagnosis of chronic interstitial cystitis was made. The usual forms of treatment were instituted. When first undertaken, fulguration of the involved areas gave relief for about three months. Over a period

of two years, nine fulgurations were done and little result was obtained from the last two. During this time it was necessary for her to take 10 to 12 grains of morphine each week.

It was at this time that the patient was referred to the Clinic to accept any form of treatment which might afford some permanent relief.

*Physical Examination:* Nothing outstanding was found on physical examination. The temperature was 98.6° F., pulse rate 72 beats per minute, blood pressure 130 systolic and 80 diastolic. There was a mid-line scar in the lower part of the abdomen and some tenderness over the lower abdomen.

*Laboratory Procedures:* Examination of the blood showed 4,600,000 red cells, 71 per cent hemoglobin, and 5,750 white cells. The level of the blood sugar was 96 mg. and of the blood urea 36 mg. per 100 cc. The blood Wassermann and Kahn tests gave negative reactions. Urinalysis showed the pH to be 6.0, no albumin or sugar was present; an occasional white blood cell and a few red blood cells were found. Culture of urine from the bladder proved to be sterile.

Roentgen study of the upper urinary tract indicated no pathologic lesion. Intravenous pyelography showed both kidneys to have prompt and good function; there was no ureteral dilatation or evidence of ascending infection.

The patient was admitted to the hospital. A *cystoscopic examination* was carried out under spinal anesthesia. The bladder capacity was found to be very small, approximately 50 cc. The entire bladder was diffusely inflamed and there were extensive areas of ulceration. There were no encrustations. Both ureteral orifices appeared quite normal. Upon distending the bladder there was generalized capillary oozing. The cystoscopic picture was characteristic of extensive chronic interstitial cystitis with ulceration. It was our opinion that diverting the urinary stream was the best method of treatment which might afford her some relief.

The usual cleansing routine in preparation for a colonic operation was instituted. Briefly the routine consists of a diet of non-residue food with additional glucose candies. Saline cathartics are administered each morning for two days, with cleansing enemas in the evening. On the third day the bowel is placed at complete rest.

On the fourth hospital day both ureters were transplanted into the pelvic portion of the colon, the left being transplanted first. A suitable site was selected at a point approximately at the junction of the sigmoid and rectum. A ureteral bed between the muscularis and mucosa of the bowel was prepared for a distance of two inches. The ureter was fixed

## BILATERAL SIMULTANEOUS URETEROSIGMOIDOSTOMY

into the bed and its end tucked through a small opening in the mucosa into the lumen of the bowel at the distal end of the ureteral bed.

A similar procedure was carried out on the right side. However, the site of implantation on this side was some distance below that on the left. The abdomen was closed without drainage and a tube was placed in the rectum. The patient withstood the operative procedure well.

Catheters or splints in the ureters were not used. If the implantation is carefully done and care is taken not to draw the sutures too tight, the urinary flow is adequate the first few days following the anastomosis.

The quantity of urine secreted on the first day was 1125 cc. On the second day there were 1910 cc., on the third day 1590 cc., and on the fourth day 1450 cc. Drainage of urine continued very favorably and on the eighth day 2475 cc. were secreted. The rectal tube was removed on the ninth postoperative day.

The highest temperature reading recorded, 102.4° F., occurred on the first postoperative day (Chart 1). At no time was there any radical

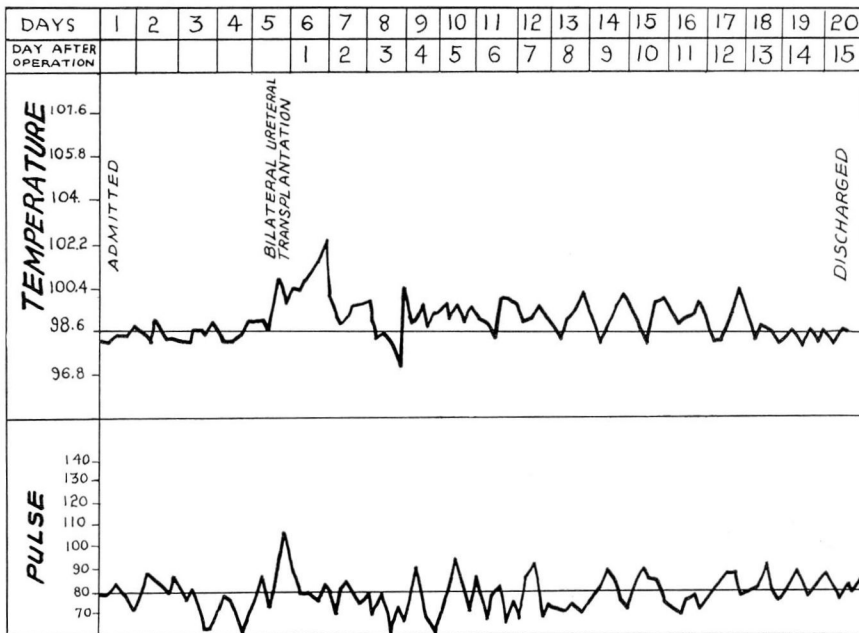


CHART 1: Chart showing temperature and pulse curves.

change in the blood chemistry. The blood urea determination was never more than 42 mg. per 100 cc.

When the patient was discharged from the hospital on the fifteenth postoperative day, she had complete symptomatic relief and required no narcotics.

The last observation of this patient was made two months following

operation, at which time she had gained 12 pounds in weight and had been perfectly comfortable.

Chronic interstitial cystitis is one of the most persistently distressing conditions which involve the urinary bladder. Only a small portion of the bladder may be involved; if so, these regions may be treated by lavage, medical agents, cauterization, and finally overdistension. However, when large portions of the bladder become affected, it is almost impossible to control the condition by such methods. When of long standing, this disease produces a small, contracted, rigid bladder with a capacity of only a few ounces. The result is extreme pain and great disability as was truly demonstrated in this case. In this state, life becomes intolerable, the patients are social outcasts, and diversion of the urinary stream is the only procedure which offers comfort to the patient. The question then is one of rehabilitation from an unendurable state to one of comfortable existence with a minimal surgical risk. In order to accomplish this, several factors must be considered.

1. What is the general physical condition of the patient? Have abdominal operations been performed previously which may make the procedure more hazardous?

2. What is the condition of the upper part of the urinary tract? Fortunately, in cases of chronic interstitial cystitis the disease usually remains confined to the bladder. Sometimes it is complicated by the formation of encrustations which may produce obstruction.

3. Proper preparation before operation has proved itself very essential both as an aid in carrying out the surgical procedure and in bringing about a favorable outcome.

4. Careful selection of the position in the bowel for implantation of the ureters is of prime importance. That position which allows the ureters to lie in their most natural positions, without becoming tortuous or kinked, is the one to be used.

5. Careful attention must be given to details during the postoperative period with special reference to the maintenance of adequate fluid intake and urinary output.

Whether one ureter should be transplanted at a time or both transplanted simultaneously is a moot question. In the patient who is a poor operative risk, the hazard of the operation may be increased if both ureters are transplanted at once. It has been our experience that the reaction following implantation of the second ureter is as great as that following the first. A number of simultaneous bilateral transplantations of the ureters have been performed at this Clinic. We are of the opinion that in patients with general good health and with the improved preoperative preparation and surgical methods, bilateral simultaneous ureteral transplantations may be utilized more frequently.