

# THE INDICATIONS FOR DUODENAL DRAINAGE: ITS RELATION TO CHOLECYSTOGRAPHY

E. N. COLLINS, M.D.

Since its clinical application by Lyon in 1919<sup>1</sup>, the Meltzer-Lyon method of duodenal drainage has proved physiologically sound but its clinical value has been disputed. When cholecystography was introduced by Graham and his coworkers in 1924<sup>2</sup>, interest in this procedure diverted attention from duodenal drainage for a number of years. During the past 14 years, however, the value and limitations of cholecystography have become established. Due to certain limitations of cholecystography, duodenal drainage is again being used by an increasing number of clinicians in conjunction with cholecystography and other roentgen examinations, each procedure giving findings complementary to the other.

In our experience cholecystography has proved the most important single diagnostic procedure pertaining to the biliary tract. The use of newer developments in technic<sup>3,4,5</sup> has enhanced its accuracy. However, there are instances in which the gallbladder has been removed, where jaundice of a sufficient degree to contraindicate the use of cholecystography exists, and when both clinical and cholecystographic findings are indeterminate.

Although we do not use duodenal drainage routinely in the investigation of the upper gastro-intestinal tract, in recent years it has been employed in an increasing number of cases and it has given important information which could be obtained in no other way.

In this communication certain features relative to an appraisal of both cholecystography and duodenal drainage will be mentioned, and the indications for duodenal drainage, according to our experience, will be presented.

In attempting to relax the sphincter of Oddi and promote drainage of bile, it should be recalled that the administration of magnesium sulfate and other gallbladder stimulants *by mouth* produce a result different from that obtained by introducing the substance directly into the duodenum (Fig. 1). Not only is hypertonic magnesium sulfate reduced to isotonicity in the stomach but at least a part of the solution is converted into magnesium chloride, and when it reaches the duodenum the union with sodium results in its conversion to sodium sulfate. Physiologists have reported that sodium sulfate tends to constrict instead of relax involuntary muscle.

The increasing interest in the study of the "post-cholecystectomy syndrome" has again emphasized the importance of earlier diagnoses in

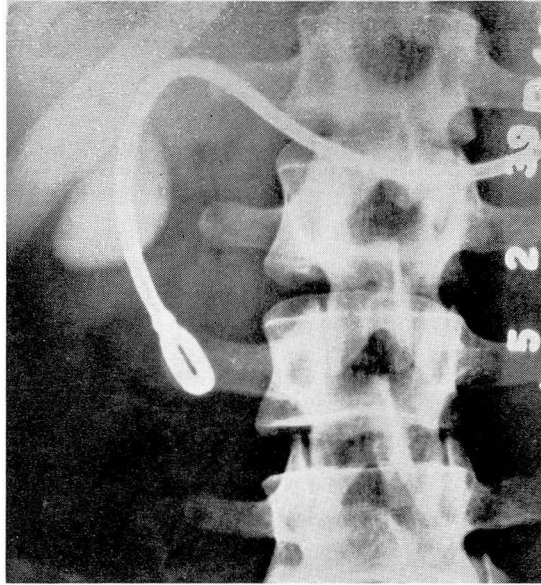


FIGURE 1a: Roentgenogram showing a normally functioning gallbladder by cholecystography during the course of duodenal drainage.

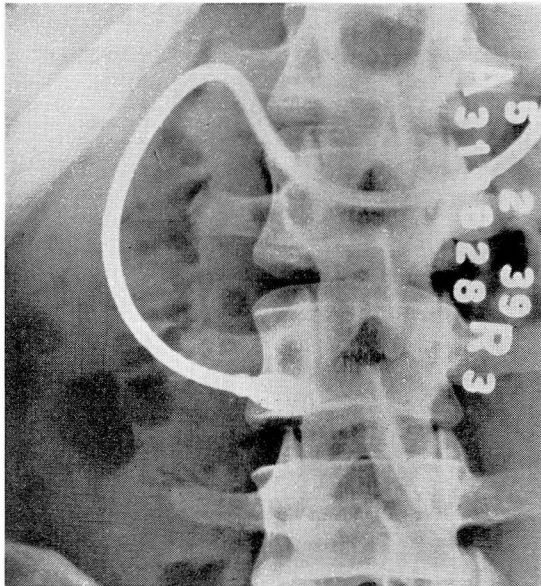


FIGURE 1b: Roentgenogram showing complete emptying of the gallbladder one hour after the injection of hypertonic magnesium sulfate into the duodenal tube.

## THE INDICATIONS FOR DUODENAL DRAINAGE

order to prevent the late sequelae of biliary disease. We believe the medical profession has not realized the significance of the published findings of the clinicians who have had considerable experience in the use of duodenal drainage. These clinicians have found that duodenal drainage has given earlier evidence of abnormality in the biliary tract than has been obtained by other diagnostic means. The increasing use of this procedure, both preoperatively and postoperatively, indicates that its value is becoming more widely recognized. Bockus, Shay, Willard, and Pessel<sup>6</sup> have shown that, in their experience, "bile drainage has proved superior to cholecystography in gall stone diagnosis." Allen O. Whipple<sup>7</sup>, in presenting a study of 700 unselected, consecutive patients having biliary or pancreatic lesions operated upon by himself during the 20 year period from 1914 to 1934, states, "The findings of cholesterol crystals, calcium bilirubin particles, and pus cells with bacteria in the duodenal contents obtained by duodenal intubation is, in our experience, even more reliable than cholecystography in demonstrating true pathology; that is, a lesion requiring surgical therapy." An interesting sidelight on the question of duodenal drainage was made by one of our urologists after the subject was discussed at a Staff Meeting. He said, "It seems to me that a diagnosis of significant biliary disease could not be made without knowing the findings on duodenal drainage any more than I could make a diagnosis of significant urinary tract disease without urinalysis." In view of investigations pertaining to the formation of renal and biliary calculi and infections in the urinary and biliary tracts, this comment was not without significance.

Certain limitations relative to cholecystographic procedures have not received sufficient emphasis; for example, normal cholecystographic findings do not exclude the presence of a significant cholecystitis. We must recall the fact that a gallbladder full of calcium-type gall stones often functions normally, as determined by cholecystography and, in this instance, a diagnosis of chronic cholecystitis, as well as cholelithiasis, is usually made in spite of the normal function.

Except in unusually acute conditions, surgeons have learned to place considerable reliance on the cholecystographic findings before advising surgical procedures. Although there has been considerable controversy relative to the significance of the so-called "innocent gall stone," all are agreed that the best results from surgery of the gallbladder are obtained in those patients who have had definite biliary colic. The relatively huge number of patients having cholecystography as compared with the small number having operations has not received sufficient recognition. Relatively few patients having normal cholecystographic findings have operations on the biliary tract. Those

having non-visualization of the gallbladder by cholecystography without evidence of opaque calculi rarely have operations unless there is a history characteristic of biliary colic. Therefore, the cholecystographic findings are not checked by the surgeon and pathologist in these instances.

If we are to make an *early diagnosis* of significant biliary disease, prevent the late sequelae of this condition, use the established newer developments in medical management, particularly as it pertains to metabolic disturbances, the infectious factors, and stasis, we believe the more widespread use of duodenal drainage, particularly in borderline cases, proves important.

## INDICATIONS FOR DUODENAL DRAINAGE

### A. *Diagnosis*

1. Suspected biliary disease; gallbladder has been removed  
Post-cholecystectomy syndrome
  - a. Suspected common-duct stone  
Chronic cholangitis
  - b. Stricture of common duct  
Is bile obtained by duodenal drainage?  
Time of onset of jaundice after cholecystectomy  
Is jaundice increasing progressively?
  - c. Spasm of sphincter of Oddi; biliary dyssynergia
2. Presence of jaundice  
History and physical findings indeterminate  
No opaque stones visualized by roentgen examination  
Character of bile, if obtained  
Is icterus index curve rising or falling?
3. Absence of jaundice
  - a. History characteristic of biliary colic  
Cholecystographic and other roentgen findings normal
  - b. Suspected biliary disease; history and physical findings indeterminate; other causes for patient's symptoms excluded
    1. Normal cholecystographic findings
    2. Non-visualization of the gallbladder by cholecystography and no opaque stones visualized
4. Suspected pancreatic disease  
Is purulent material or other inflammatory products obtained?  
Pancreatic enzymes  
Character of bile, if obtained
5. Certain diseases of the liver, such as biliary cirrhosis
6. Postoperative appraisal of state of biliary tract

## THE INDICATIONS FOR DUODENAL DRAINAGE

### B. *Treatment*

Pancreatitis; "Catarrhal" jaundice (shortens course);

Non-calculous biliary tract disease, if other indicated measures of treatment prove inadequate. Intractable urticaria; the use of a vaccine made from cultures of bile obtained by duodenal drainage has proved effective in the treatment of intractable urticaria when other procedures from the stand-points of allergy and gastro-intestinal function prove ineffective.

### SIGNIFICANT FINDINGS—DUODENAL DRAINAGE

#### 1. Absence of concentrated bile

(Gallbladder present)

Repeated stimulations; possibly repeated on separate days;

Correlation with roentgen findings

Consider abnormal function of gallbladder, cystic duct obstruction or gallbladder containing stones; psychic factors.

#### 2. Presence of

a. Cholesterol crystals

b. Calcium bilirubinate pigment

1. If jaundice is not present

presence of both (a) and (b) usually indicates gall stones, cholesterosis, or pre-calculous state

2. If jaundice is present or has been present recently

presence of (b) alone is not significant

presence of (a) alone may indicate cholesterosis

presence of both: as indicated in (1)

### SUGGESTIVE FINDINGS—DUODENAL DRAINAGE

1. Unusual number of bile-stained pus cells

2. Abnormal cell exfoliation

3. Bacterial clumps—number and amount in concentrated or last bile fractions

4. Bacteriological examination

### TECHNIC

The value of duodenal drainage depends to a great extent on the care and exactness of the technic used, as well as the experience of the examiner. Although these criteria are always employed in judging the value of cholecystography and other laboratory procedures, they may not be given equal emphasis in the appraisal of duodenal drainage. This communication is based on the work done or supervised by a technician who has had ample training and experience with Doctors Lyon and Bockus. Because of its proved value in producing contraction of the gallbladder during cholecystography, an egg-yolk-lecithin-glycerine mixture<sup>5,8</sup> has been injected through the duodenal tube when no concentrated bile (gallbladder present) is obtained by the use of the usual stimulants.



Positive findings may be accepted with greater certainty than negative findings, as is the case with other laboratory procedures. When there is absence of concentrated bile (gallbladder present) and the result of duodenal drainage is either indeterminate or not in keeping with other features of the individual's problem, recheck examinations should no more be neglected in the appraisal of duodenal drainage than is the case with other examinations.

The value of experience in interpretation has been emphasized by Shay and Riegel<sup>9</sup>. "Persistence and care are required even by the very experienced microscopist. Examination of the sediment after centrifugalization should always be made before the specimen is to be considered negative and it is of great importance that the material be examined shortly after it is obtained."

## A. DIAGNOSIS

### 1. *Suspected Biliary Disease in Absence of Gallbladder*

The value of duodenal drainage in cases of common duct stone after cholecystectomy has been demonstrated in the cases reported by Shay, Tumen, and Rodis<sup>10</sup>, and Shay and Riegel<sup>9</sup>. In these instances when roentgenograms of the gallbladder area reveal no opaque calculi, cholesterol crystals and calcium bilirubinate pigment obtained by duodenal drainage may give the clinician the most important objective evidence available. On the other hand, their absence on repeated satisfactory examinations is significant in the diagnosis of biliary dyssynergia.

### 2. *Presence of Jaundice*

In simple diagnostic problems where there is a history of biliary colic followed by jaundice there is usually no need for duodenal drainage. This is especially true when roentgenograms of the gallbladder area reveal the presence of opaque calculi or when the jaundice has subsided, cholecystography demonstrates the presence of gall stones. But when the history (aside from the presence of jaundice) and roentgen findings are indeterminate, duodenal drainages are helpful in differentiating between so-called "catarrhal jaundice" and a calculous state.

When jaundice is present, regardless of whether or not the patient has a gallbladder, although examinations of the urine and stools for bile pigment are important, the quantity and character of the bile obtained by duodenal drainage may furnish accurate information relative to the cause of obstructive jaundice. Roentgenograms of the gallbladder area may reveal no opaque calculi and cholecystography is not used. Other diagnostic measures which have proved significant in our experience have been quoted by Phillips and Haden<sup>11</sup> and Hartsock<sup>12</sup>. A curve plotted from daily or repeated determinations of the icterus

## THE INDICATIONS FOR DUODENAL DRAINAGE

index is especially significant. Hartsock has mentioned that, "There are many cases in which the exact etiology of the jaundice remains in doubt even after exploratory operation, so it is easy to realize the difficulty of making an exact differential diagnosis clinically."

Early in the course of our appraisal of duodenal drainage this procedure was used as a confirmatory diagnostic measure in the following case:

*Case 1:* A housewife, 32 years of age, was jaundiced at the time of her admittance to the Clinic. She gave a history of increasingly frequent attacks of pain in the right upper quadrant of the abdomen, chills, and fever, followed by jaundice. The icterus index was 50 units, the blood cholesterol 246 mg. per 100 cc., and a macrocytosis of the red cells was present. Even though roentgenograms of the gallbladder area revealed no evidence of opaque calculi, the diagnosis of gall stones both in the gallbladder and common bile duct seemed obvious. By duodenal drainage a free flow of bile was obtained on each of two separate days and both times the bile contained cholesterol crystals, calcium bilirubinate pigment, many bile-stained pus cells, and tall columnar epithelial cells. On preoperative management, the patient's general condition was considerably improved and the icterus index was reduced to 25 units. At this time cholecystography, using the 2 dose oral method, was reported as showing non-visualization of the gallbladder, and the remainder of the gastro-intestinal series' roentgen examination revealed normal findings.

At operation two stones in the common bile duct at the ampulla of Vater, enormous dilatation of the common bile duct, and a small gallbladder adherent to the surrounding structures were found. No other stones were present. By the introduction of a lead probe through an incision in the common bile duct the surgeon was able to push the stones into the duodenum. The gallbladder was removed and a T-tube was left in place. The pathological diagnosis was chronic cholecystitis. The postoperative convalescence was uneventful and the patient has had excellent health since that time.

### 3. *Absence of Jaundice*

In cases where jaundice is not present and the cholecystographic findings are normal, biliary disease may still be suspected. The patient may or may not give a history characteristic of biliary colic and other causes for the symptoms have been excluded. In our experience relatively few patients having normal cholecystographic findings have operations on the biliary tract so that the accuracy of cholecystography as a diagnostic procedure in these instances is rarely checked at operation and by the pathologist. We believe the assumption that the biliary tract is normal because the cholecystographic findings are normal in

this group of cases is incorrect. Wilson, Lehman, and Goodwin<sup>13</sup> in dealing with prognosis in gallbladder surgery, state that the ultimate results in 14 cases of normal cholecystographic shadow are only 50 per cent satisfactory. "This is of particular interest not only in the use of the normal cholecystogram as a warning against operation but also to emphasize further the suggestion of Graham and Mackey<sup>14</sup> that a proportion of unsatisfactory results in gallbladder surgery arise from mistaken diagnosis." Jenkinson<sup>15</sup> found that in a series of 95 cases with symptoms referable to the gallbladder, cholecystography showed a normally functioning gallbladder in 70 (73 per cent).

In dealing with operations on the stoneless gallbladder, Graham and Mackey found the percentage of cures or improvement the same in the group of patients with normal cholecystograms and in the group with non-visualized gallbladders (60 per cent). In the same type of case Kunath<sup>16</sup> stated, "of the cases in which there were normal cholecystograms, there were cures or improvement in 75 per cent."

Therefore, in spite of normal findings by cholecystography when a strong suspicion of biliary disease remains, we believe significant abnormality in the biliary tract should not be considered to have been excluded until two or more duodenal drainages result in normal findings. On the other hand, positive findings by duodenal drainage may result in a diagnosis of cholesterosis, a pre-calculous state, or chronic cholangitis. If early surgical procedures do not seem to be indicated, the use of the important developments in medical management should prove especially valuable in these cases.

In the following case the significance of calcifications in the right upper abdominal quadrant was not determined at the time of the initial examination. In view of the important findings obtained by duodenal drainage when it was used at a later date (confirmed at operation), its earlier use might have established the correct diagnosis before the onset of biliary colic and jaundice.

*Case 2:* A man, 43 years of age, was admitted to the Clinic in March 1935, and a diagnosis of irritable colon, hypometabolism, and obesity was made. Cholecystographic examinations were reported as showing a normally functioning gallbladder not containing calculi, but five calcifications were visualized outside the gallbladder in the right upper quadrant of the abdomen. There was no history of jaundice and the symptoms were interpreted as unrelated to biliary disease. It was thought that the shadows represented calcified lymph nodes. The use of duodenal drainage was not considered at that time.

Two years and three months later the patient was deeply jaundiced at the time of his re-admittance (June 1938). The icterus index was 75



## THE INDICATIONS FOR DUODENAL DRAINAGE

units and it rapidly rose to 100. Eleven days prior to this entrance he had been awakened by severe pain in the right upper quadrant of the abdomen. Hypodermics were given for relief but the pain recurred off and on, and meanwhile he became deeply jaundiced. Roentgen examination revealed no change in the calcifications. On each of four separate days a free flow of bile was obtained by duodenal drainage. This contained cholesterol crystals, large strands of cast-like mucous-material, and an abnormal number of bile-stained pus cells, in addition to pigment granules and bile-stained tall columnar epithelium. A diagnosis of common duct stone was made.

Operation was performed and a stone, the size of a pea, associated with the presence of "gravel," was found in the common bile duct at the ampulla of Vater. The gallbladder was small and presented considerable fibrosis in its walls but it contained no gall stones. The common bile duct was much thicker than normal but was not dilated. It was thoroughly irrigated and a T-tube was left in place. Nothing was done to the gallbladder. The postoperative convalescence was uneventful, the icterus index curve slowly descended to 10 units on the twenty-third postoperative day, and no abnormal symptoms or findings relative to the digestive tract have been observed since that time.

Roentgenograms of the gallbladder area subsequent to operation showed an absence of the calcifications observed at the time of the first examination.

### *Non-Visualization of the Gallbladder by Cholecystography*

Non-visualization of the gallbladder by cholecystography (no opaque calculi visualized) does not mean that the cause for the patient's abdominal symptoms has been found. Unless there is a history of unquestioned biliary colic, it is advisable for the surgeon to defer operation on the biliary tract until roentgen and other examinations of adjacent organs, as well as duodenal drainage, have been done. Close correlation of all clinical and laboratory evidence is, of course, assumed in order to prevent an unsatisfactory postoperative course. In questionable cases, at least recheck cholecystographic examinations should be made after the patient has been on medical management several weeks before it is concluded that abnormality in the gallbladder is the chief cause of the patient's symptoms.

The various causes of non-visualization of the gallbladder by cholecystography are now well known. When the clinical and other laboratory evidence is not conclusive, the findings on duodenal drainage may show that operation is clearly indicated. On the other hand, when satisfactory duodenal drainages result in normal findings in these instances, we believe operation should be deferred until medical man-

agement has relieved symptoms pertaining to other parts of the digestive tract.

Jenkinson<sup>15</sup> found that in 8, or 40 per cent, of twenty patients with non-functioning gallbladders by cholecystography there was a normal response radiographically after medical management.

We agree with Wilkinson<sup>17</sup> in his discussion of "Chronic Cholecystitis Versus Irritable Colon" when he states, "The fundamental difference between the diagnosis of chronic cholecystitis and that of irritable colon would be of little moment but for the fact that one condition is organic and likely to be treated surgically while the other is a functional disorder amenable to dietary management. Since there is such a similarity in the two types of complaints, it does not seem proper immediately to classify chronic dyspepsia as gallbladder disease because of a dull ache in the right upper part of the abdomen and a poorly seen gallbladder. Lahey and Jordan have shown that 44 per cent of the patients with chronic dyspepsia whose gallbladder cannot be visualized will later show normal filling after an adequate period of bowel management. The patients who show delayed emptying or poor visualization will be even more likely to fall into the functional group." This coincides with our experience except that a smaller percentage of our patients having irritable colon have a non-functioning gallbladder by cholecystography at the initial examination with return to normal function later. Differences in cholecystographic technic used at the time the statistics were compiled may be the explanation.

The significant feature is the established fact that spastic conditions of the gastro-intestinal tract can cause temporary non-visualization of the gallbladder by cholecystography. In this group most of our patients did not have duodenal drainages at the time of the original examination because the symptoms relating to the irritable colon syndrome, associated with diarrhea or constipation, or one alternating with the other, seemed most significant. If recheck cholecystography at the end of a period of adequate bowel management does not result in normal findings, we now routinely request duodenal drainage.

In our experience, one of the chief causes of the increasing incidence of irritable colon is the widespread use of magnesium sulfate given by mouth each morning for months if not years as a supposed "cure" of alleged gallbladder disease. We refer to patients who do not give a history of clear-cut biliary colic but have non-visualization of the gallbladder by cholecystography, associated with an indeterminate chronic dyspepsia. Even though the symptoms involve the right upper abdominal quadrant (usually close analysis of symptoms will reveal the presence of abdominal distress related to other parts of the colon also)

## THE INDICATIONS FOR DUODENAL DRAINAGE

we have found that the discontinuance of the increasing use of cathartics, particularly daily saline cathartics, together with other principles of bowel management, result not only in relief of symptoms but a return to normal in gallbladder function.

The difference in giving hypertonic magnesium sulfate *by mouth* and by duodenal tube (after which it is immediately removed by siphonage during duodenal drainage) has been emphasized earlier in this discussion.

*Case 3:* In the following case, the 21-year-old unmarried daughter of a physician had symptoms characteristic of biliary colic but of equal significance were those pertaining to an irritable colon.

From the standpoint of symptoms and personal observation, this patient repeatedly said that, "as long as I follow the principles of bowel management as instructed I have no trouble. When I encounter circumstances which make this impossible or I want to try myself out I get one of these attacks (pain in the right upper abdominal quadrant radiating to the right scapula without jaundice)." At these times she also invariably had dysfunction of the colon, either unusual constipation or diarrhea, cramp-like pain, and definite tenderness over the lower left colon. A test enema, given in the hospital at the time of an attack characteristic of biliary colic increased the pain as the fluid entered various parts of the colon, but complete relief was obtained after the expulsion of the enema. It should be emphasized that this patient was a shrewd observer and honest.

Repeated double-dose cholecystographic examinations resulted in non-visualization of the gallbladder without evidence of opaque calculi. Two duodenal drainages resulted in obtaining both cholesterol crystals and calcium bilirubinate pigment and no concentrated "B" fraction of bile. Surgeons who saw her in consultation during the initial attacks advised no surgical procedures, partly because of her age, but also because of misjudgment relative to functional disturbances, in spite of the positive findings by cholecystography and duodenal drainage. Finally, she had an attack of biliary colic which was followed by jaundice. At operation gall stones were found in the gallbladder (two large mulberry stones and ten or twelve small stones the size of a pea). The common duct was dilated, opened, and explored but no stones were found; however, drainage was done. Her convalescence was uneventful and recently it was learned that she is in excellent health and is on a European honeymoon.

A letter from her father, a well-known physician, states, "The pathological section of her gallbladder showed no evidence of infection and it was the opinion of us all that this was purely a problem of metabolism."

It would seem that this case emphasizes the close relationship between the biliary tract and the colon, that spastic conditions in the colon or other parts of the gastro-intestinal tract, may, in a reflex manner, cause spasm of the sphincter of Oddi, which in turn results in metabolic disturbances or the soil (to quote Osler) contributing to the formation of cholesterol (non-opaque) gall stones. Is this any more a stretch of the imagination than to say the disturbance in the biliary tract in a 21-year-old girl resulted in reflex disturbances in the colon? Which is the cart and which is the horse? It is the author's opinion that a careful study of a relatively few intelligent individuals would result in a more accurate solution of these problems than an incomplete study of a large number of statistics.

#### 4. *Suspected Pancreatic Disease*

When suspected pancreatic disease is present the analysis of the findings on duodenal drainage is of unquestioned value. On the diagnostic side, it is important when purulent material or other inflammatory products are obtained, as well as to permit analysis of the character of the duodenal contents, including studies of pancreatic enzymes. Constant duodenal drainage while adequate parenteral therapy is administered has also proved important from the therapeutic standpoint.

#### 5. *Certain Diseases of the Liver*

In the appraisal of certain diseases of the liver, such as biliary cirrhosis, the use of duodenal drainage has proved important in our experience.

#### 6. *Postoperative Appraisal of Biliary Tract*

In the postoperative evaluation of the state of the biliary tract we believe the findings obtained by duodenal drainage have not been sufficiently utilized, in view of the fact that it is desirable to prevent the "post-cholecystectomy syndrome." The writings of Best and Hicken<sup>18</sup> relative to cholangiographic demonstration of biliary dyssynergia are of unusual significance in this respect. Even though meticulous operative procedures have been done, detritus may remain in the common bile duct which is not drained by the T-tube. Substances injected directly into the duodenum, in proper concentration, have proved more effective than the administration of the same substances by mouth, not only in producing relaxation of the sphincter of Oddi, but also in permitting analysis of drainage from the common bile duct.

If duodenal drainage has not been done prior to two months following operative procedures on the biliary tract, we believe the more common use of this procedure at this time, together with appropriate use of medical management, according to the findings, will result in better

## THE INDICATIONS FOR DUODENAL DRAINAGE

operative statistics and the ultimate aim of a satisfied patient. It is fair to assume that the desirable postoperative course in the individual case, particularly when unusual circumstances are present, will be afforded by the mutual interest and cooperation of both the internist primarily interested in gastro-intestinal diseases and of the surgeon.

### B. TREATMENT

Our experience in the treatment of biliary disease by the use of duodenal drainage is limited. Our chief interest in this procedure has been the added information it gives when other diagnostic procedures are either indeterminate or not helpful. We believe it is of value in the treatment of pancreatitis, in shortening the course of "catarrhal jaundice," and in non-calculous biliary tract disease when other well-known methods of medical management prove unsatisfactory. Intractable urticaria; the use of a vaccine made from cultures of bile obtained by duodenal drainage has been mentioned.

### CONCLUSIONS

1. The increasing use of duodenal drainage in recent years, in correlation with cholecystography, as well as the clinical and other findings, has proved to be an important diagnostic procedure under the circumstances mentioned.

2. The value of cholecystography is well known.

3. The most important indications for duodenal drainage are the instances where the gallbladder has been removed, where jaundice of a sufficient degree to contraindicate the use of cholecystography exists, and when both clinical and cholecystographic findings are inconclusive.

4. In patients having operations subsequent to duodenal drainage, the operative findings confirmed the findings by duodenal drainage in 84 per cent of all cases to date. Duodenal drainage has not been used as a routine procedure in the investigation of the digestive tract. Its use has been limited usually to those instances where other diagnostic criteria are indeterminate.

5. Since routine autopsies in various countries have shown that half of the persons above the age of 30 years had pathological changes in the gallbladder and approximately 20 per cent had gall stones, the more common use of duodenal drainage should result in earlier diagnoses and earlier operations, if medical management is not appropriate, before pathological processes have extended so widely that surgery cannot be expected to relieve the patient's symptoms.

## E. N. COLLINS

### REFERENCES

1. Lyon, B. B. V.: Diagnosis and treatment of disease of gallbladder and biliary ducts, J. A. M. A., 73:980-982, (September 27) 1919.  
Non-surgical Drainage of the Gall Tract, Lea and Febiger, Philadelphia, 1923.
2. Graham, E. A. and Cole, W. H.: Roentgenologic examination of gallbladder, new method utilizing intravenous injection of tetrabromphenolphthalein, J. A. M. A., 82:613-614, (February 23) 1924.  
Graham, E. A., Cole, W. H. and Copher, G. H.: Visualization of gallbladder by the sodium salt of tetrabromphenolphthalein, J. A. M. A., 82:1777-1778, (May 31) 1924.
3. Collins, E. N.: Cholecystography, Cleveland Clin. Quart., 2:16-22, (July) 1935.
4. Collins, E. N.: Cholecystography, op. cit. 11, Vol. 8, Chapter 3, p. 58-68.
5. Collins, E. N. and Root, J. C.: Cholecystography; further observations on use of pitressin and evaluation of other procedures, Radiology, 29:216-226, (August) 1937.
6. Bockus, H. L., Shay, H., Willard, J. H. and Pessel, J. F.: Comparison of biliary drainage and cholecystography in gall stone diagnosis with especial reference to bile microscopy, J. A. M. A., 96:311-317, (January 31), 1931.
7. Whipple, A. O.: Therapy of non-malignant biliary tract lesions, Am. J. Digest. Dis. & Nutrition, 2:44-46, (March) 1935.
8. Levyn, L.: An effective gallbladder stimulant to supplant the fat meal, Am. J. Roentgenol., 26:904, (December) 1931.
9. Shay, H. and Riegel, C.: Role of laboratory in diagnosis of gallbladder disease, Am. J. M. Sc., 192:51-57, (July) 1936.
10. Shay, H., Tumen, H. and Rodis, I.: Diagnosis of gallstones; relative accuracy of cholecystography and non-surgical biliary drainage, M. Clin. North America, 13:939-946, (January) 1930.
11. Phillips, John and Haden, R. L.: Diagnosis and Treatment of Diseases of the Liver and Biliary Tract, Vol. 8, Oxford Monographs on Diagnosis and Treatment, Oxford University Press, New York, 1936.
12. Hartssock, Charles L.: Differential diagnosis of jaundice, Cleveland Clin. Quart., 5:102-107, (April) 1938.
13. Wilson, W. D., Lehman, E. P. and Goodwin, W. H.: Prognosis in gallbladder surgery, J. A. M. A., 106:2209-2213, (June 27) 1936.
14. Graham, E. A. and Mackey, W. A.: Consideration of stoneless gallbladder, J. A. M. A., 103:1497-1499, (November 17) 1934.
15. Jenkinson, E. L.: Cholecystography, J. A. M. A., 107:755-757, (September 5) 1936.
16. Kunath, C. A.: Stoneless gallbladder; analysis of 100 cases treated by cholecystectomy, J. A. M. A., 109:183-187, (July 17) 1937.
17. Wilkinson, S. A.: Chronic cholecystitis versus irritable colon, J. A. M. A., 109:1012-1016, (September 25) 1937.
18. Best, R. R. and Hicken, N. F.: Cholangiographic demonstration of biliary dyssynergia and other obstructive lesions of gallbladder and bile ducts, J. A. M. A., 107:1615-1620, (November 14) 1936.  
Nonoperative management of remaining common duct stones, J. A. M. A., 110:1257-1261, (April 16) 1938.