

## OBSTRUCTIVE LESIONS AND INFECTION IN THE URINARY TRACT

W. J. ENGEL, M.D.

The common urological dictum that obstructive lesions and infection of the urinary tract are bad bedfellows has been established by universal clinical experience. Not only does obstruction predispose to infection, but treatment of the infection in the presence of obstruction is usually quite hopeless until the obstruction is relieved. Thus the recognition of obstruction is essential to proper treatment of urinary infections and in the present era of effective chemotherapy, one criterion which may be used in suspecting the presence of an obstructive lesion is the failure of the infection to respond to chemotherapeutic agents. Chronic urinary infection should, therefore, be considered to be due to urinary stasis until proved otherwise. The relief of the obstruction is a surgical problem in the majority of instances.

Obstructive lesions in the urinary tract are of many types and may be partial, complete, or intermittent. They may occur anywhere from the calices to the urethral meatus and may be either congenital or acquired. An important consideration from the point of view of management is the location of the obstruction, that is, whether it is below or above the bladder and, in turn, whether the supravescical lesion is unilateral or bilateral.

That obstruction predisposes to infection finds many examples and sooner or later infection is almost sure to complicate any obstructive lesion. The increased susceptibility of an obstructed urinary tract to infection is due to the resulting congestion in the kidney which reduces the resistance of the renal cells and pelvic epithelium to bacteria which may be excreted and this, added to stasis of urine to provide a good culture medium, sets the stage for infection. It has generally been accepted that the kidneys may excrete bacteria as, for example, during the course of any acute infectious disease and in the absence of any obstruction, no symptoms referable to the urinary tract may occur whereas if obstruction is present infection is likely to follow. Once infection is present, however, obstruction plus infection is rapidly destructive to renal tissue. In fact, extensive destruction of the renal parenchyma rarely results from infection alone without some degree of obstruction and, in general, the more complete the obstruction, the more rapid the renal damage.

True it is that many obstructive lesions may be present for a considerable period of time without giving rise to any noteworthy symptoms and many of these cases are first brought to the attention of the physician by the advent of infection. This may occur in young children, especially those with a congenital type of obstruction, although in some cases a

hydronephrosis may exist until advanced years of life and never be discovered unless superimposed infection occurs.

Although the diagnosis of an obstructive lesion complicating infection can be established finally only by complete urological investigation, including cystoscopy, ureteral catheterization, and pyelography (or intravenous urography in certain cases), some clue is frequently supplied by the clinical course and symptomatology.

To paraphrase the three R's of school days we may epitomize the three P's of obstructive infection in the urinary tract, which are *pain*, *pyrexia*, and *persistent pyuria*.

If we consider first only the supravescical lesions, the one outstanding differential symptom is pain. In the ordinary uncomplicated pyelitis kidney pain is not an outstanding symptom while in the presence of obstruction pain is the rule. This may be of a dull, dragging, aching type or it may be acute, severe, and colicky, the degree as well as type depending upon the suddenness and completeness of the obstruction. An infected kidney which has some drainage gives rise to mild pain compared with the kidney which is suddenly and completely obstructed.

Likewise, the severity of the febrile reaction is dependent upon the same factors. The more chronic, incompletely obstructed infection may give rise to only mild elevations of temperature so the urinary tract

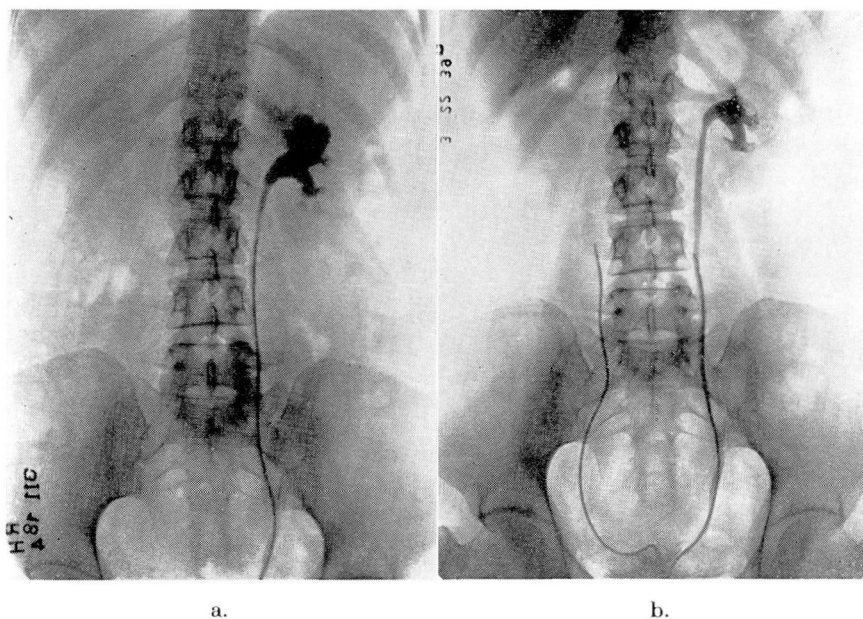


FIGURE 1: Woman, age 49. Complaint: Backache, fatigue, and poor endurance. No urinary symptoms but pus cells were found in the urine secured by catheterization.  
 a. Pyelogram shows marked dilatation of the upper calyx; a stone was present in this calix.  
 b. Postoperative pyelogram nine months following heminephrectomy.

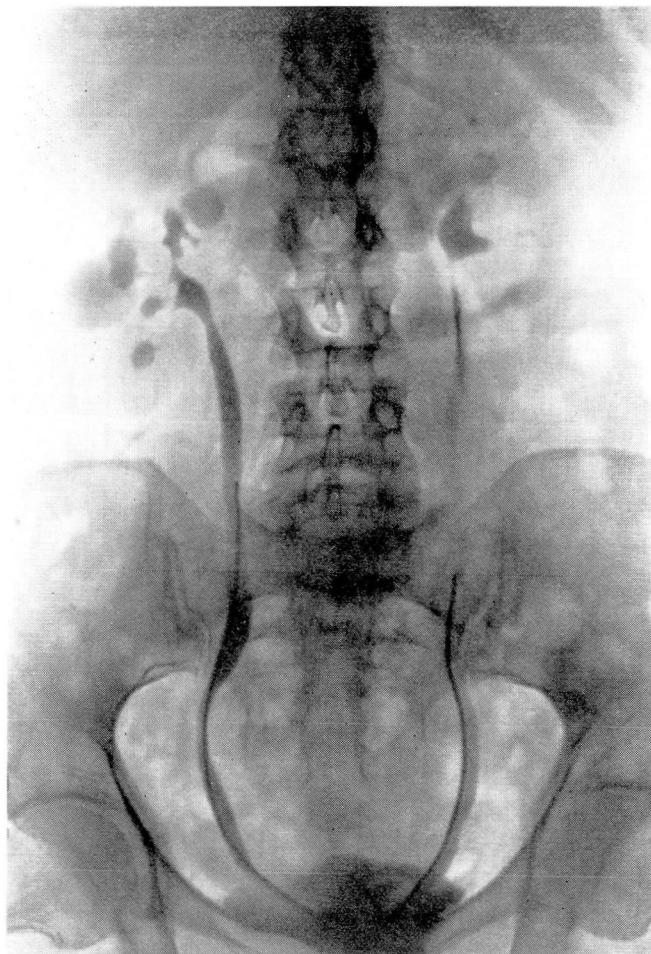


FIGURE 2: Woman, age 48. Complaint: Burning on urination, frequency, urgency, and chills and fever. Urine loaded with pus. Pyelogram shows advanced chronic bilateral pyelonephritis. Note particularly dilatation of the calices on the right with constriction of the infundibulae.

should therefore be considered in any unexplained, prolonged, low grade fever. In contrast to this the acutely obstructed infection may produce astounding temperature elevations even up to  $106^{\circ}$  F. or higher and yet, as a rule, the degree of prostration may be minimal.

The majority of the supravescical lesions are of course unilateral and this very fact also tends to indicate the presence of obstruction. Localizing symptoms are rarely absent in infected hydronephrosis and, in fact, in the majority of unilateral obstructed infections.

Persistent pyuria, however, is perhaps the most reliable guide to indicate the presence of an obstruction complicating infection for there are

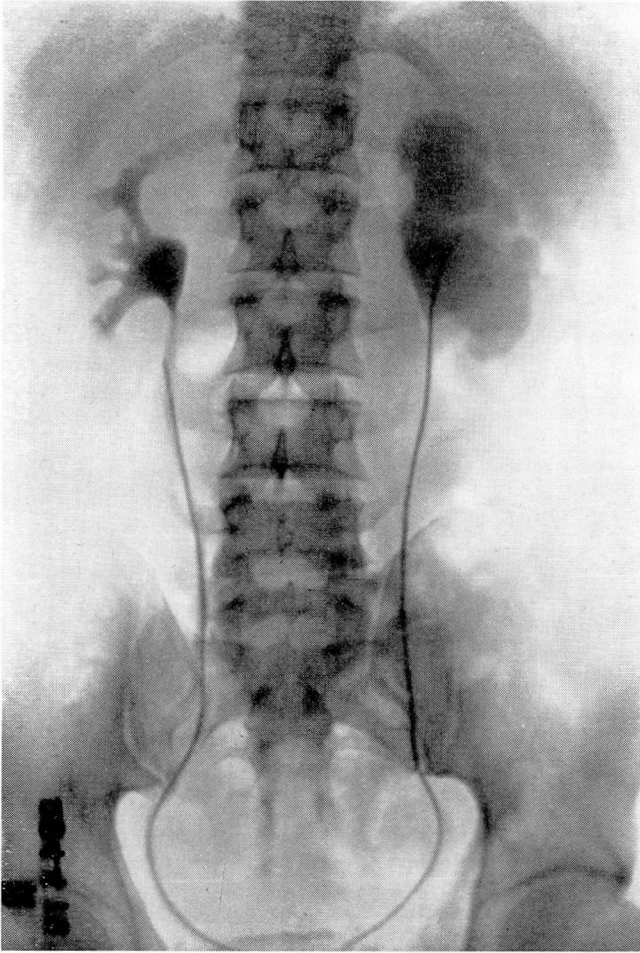


FIGURE 3: Man, age 31. Complaint: Severe attacks of pain in the left kidney region associated with nausea, vomiting, and chills and fever. Pyelogram shows normal right kidney; marked hydronephrosis with infection on the left side. Operation: Left nephrectomy with removal of a large pyonephrotic kidney. Obstruction was due to an aberrant artery at the ureteropelvic junction.

some cases in which neither pain nor fever is present. This is particularly true in certain of the congenital lesions in children and Campbell<sup>1</sup> reports finding anomalies in 41 per cent of children who were investigated for chronic pyuria. Regardless of age, however, as a clinical rule one may say that any urinary tract infection in which the urine is not clear within four weeks under medical management should be completely investigated to rule out an obstructive lesion. The same rule should be applied to recurrent infections.

Of the obstructive lesions of the upper urinary tract, one occasionally encounters an inflammatory stricture of the infundibulum of a single

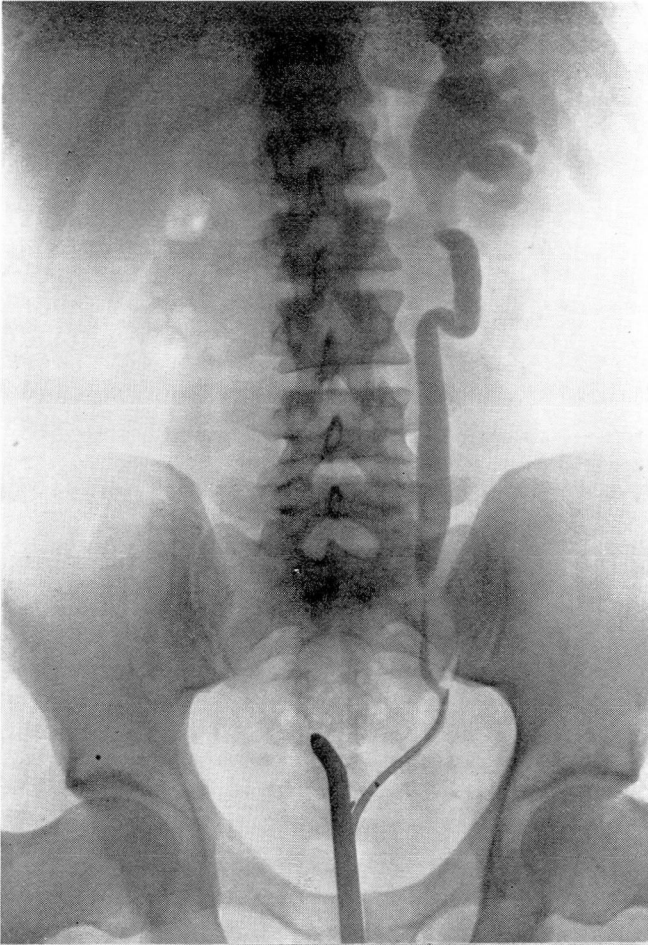


FIGURE 4: Man, age 28. Complaint: Pain in the left kidney region and persistent pyuria. Ureteropyelogram shows true inflammatory stricture of the lower third of the ureter with dilatation of the ureter and kidney pelvis above.

calix of the kidney (Fig. 1). More commonly this involves either the upper or lower calix, although in rare instances it may involve only a middle calix. Very commonly these cases are associated with stone and the treatment of choice is heminephrectomy since it is quite impossible to correct the stenosis of the calix. Unless the dilated, infected calix is removed, infection is likely to persist and recurrent formation of the stone is the rule. Another type of obstruction somewhat akin to this exists in the patients with chronic pyelonephritis in whom cicatricial constrictions of the calices frequently develop (Fig. 2). This results in obstruction to the individual calices and these constitute exceedingly

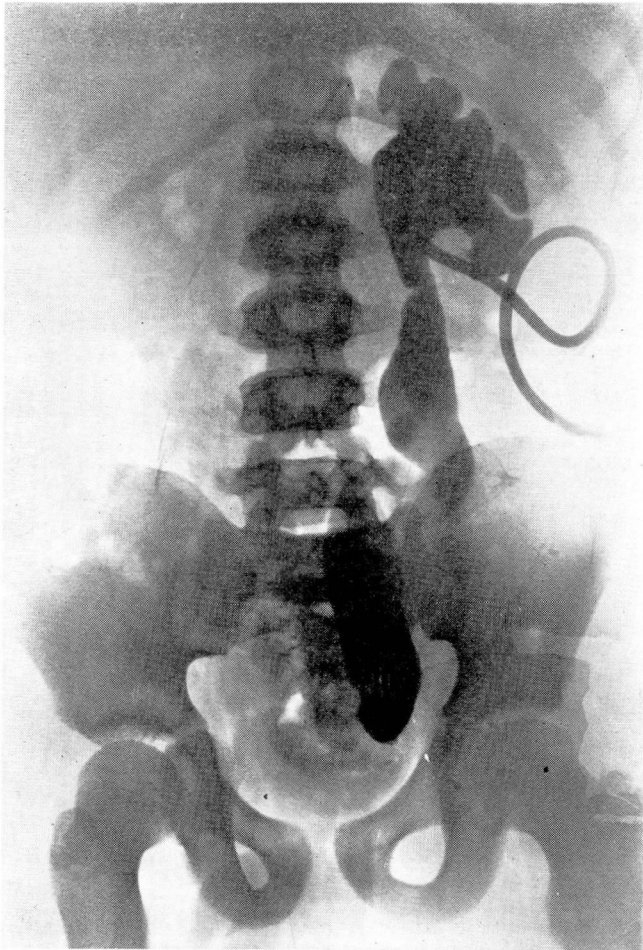


FIGURE 5: Boy, age 10. Only complaint was pus in the urine with absolutely no urinary symptoms. Ureteropyelogram through a nephrostomy tube shows marked hydronephrosis, ureteral dilatation, and tortuosity, with congenital stricture at the ureterovesical junction. Following pyelostomy drainage, plastic operation was performed upon the lower end of the ureter with relief of symptoms.

difficult problems in treatment. They are almost invariably bilateral and therefore operation cannot be performed.

Of the obstructive lesions at the ureteropelvic junction, the commonest perhaps is an impacted stone but next in frequency are the congenital obstructive lesions in the ureteropelvic junction, particularly the strictures, angulations, and aberrant vessels (Fig. 3). Although pain may call attention to the existence of lesions of this type, here again they are more commonly brought to the attention of the physician by the advent of infection. Medical management cannot hope to clear up these lesions; they are distinctly surgical problems and the decision as to conservative

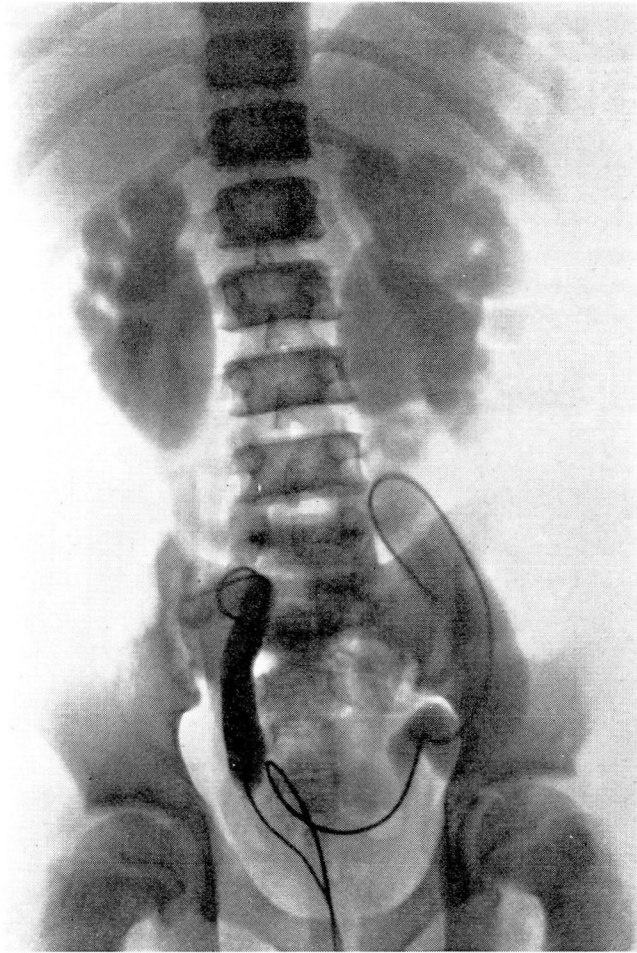


FIGURE 6: Boy, age 15. Persistent pyuria and renal rickets. Bilateral pyelogram shows marked bilateral hydronephrosis and hydro-ureter. Congenital obstruction at bladder neck.

plastic operation or nephrectomy depends upon the degree of kidney damage.

A word of caution should be inserted here regarding the investigation of these hydronephrotic kidneys. Because the obstruction predisposes to infection, ureteral catheterization and diagnostic pyelograms sometimes initiate infection so that these patients should be ready for operation when such investigations are carried out.

In the ureter, stone is the most common obstruction. A stone may pass without infection but all too commonly infection complicates the problem. Particularly in the manipulation of stones must one be on guard because so frequently these procedures inaugurate infection above the impacted stone.

The other obstructive lesions in the ureter include the true strictures and particularly the congenital strictures at the ureterovesical junction (Figs. 4 and 5). The latter cases most frequently occur in children and, as a general rule, persistent pyuria or recurrent acute urinary infection is the thing which brings these to attention.

Rarely does one see primary ureteral tumors which produce obstruction. There are a number of extra-ureteral lesions which may cause ureteral obstruction by external compression. First and foremost of these is pregnancy which constitutes in reality a physiological type of obstruction and yet, because of this, the upper urinary tract in pregnancy is especially prone to infection. This usually clears up promptly after delivery, although if the infection has been severe, it may persist for a considerable period of time. Although both kidneys may be affected in the pyelitis of pregnancy, the more troublesome cases are often associated with a severe unilateral infection. Most cases will respond favorably to the use of properly chosen urinary antiseptics in conjunction with knee chest exercises to allow the uterus to fall away from the ureters, thus promoting better drainage. It is my firm belief that instrumentation should be avoided in the treatment of these cases until it is demanded by the failure of more conservative methods.

Pelvic tumors, particularly fibroids and ovarian tumors, may in a similar fashion produce ureteral obstruction as may also the rare cases of retroperitoneal tumors.

In the urethra, of course, by far the most common obstructive lesion is prostatic hypertrophy and other obstructions of the bladder neck. In this, as in other infravesical obstructions, the infection may be limited to the bladder. This is aggravated by the frequent association of sacs and diverticula which result from the obstruction and may become infected and cause prolonged cystitis. It is virtually impossible to clear up a cystitis in the presence of bladder neck obstruction; therefore, surgical relief in these cases is demanded.

The congenital urethral valves constitute a lesion of unusual interest and are invariably seen in children. In the vast majority of these cases the obstruction has existed since birth and even during intra-uterine life. In all the cases I have seen there have been markedly dilated ureters and kidney pelves so that the entire urinary tract is one communicating cavity (Fig. 6). Chronicity characterizes infection in these cases and even after obstruction has been relieved pyuria frequently persists. However, here again this lesion may exist for a considerable period of time before being recognized. I recall particularly the instance of a patient who had had very little trouble until the age of 14 years, when an infection developed and persisted. Investigation showed the presence of a congenital enlargement of the verumontanum.



## OBSTRUCTIVE LESIONS AND INFECTION IN THE URINARY TRACT

I should like to emphasize particularly the association of urethral stricture with obstinate urinary infection. We have on numerous occasions seen patients with recurrent chills and fever in whom a urethral stricture was found and relief by internal urethrotomy and subsequent dilatations proved to be prompt and gratifying.

### SUMMARY

Attention has again been drawn to the effect of obstructive lesions of the urinary tract upon infections. Their recognition constitutes an essential part of the intelligent treatment of urinary infections and yet they are commonly overlooked. It is hoped that this repetition of facts which are common knowledge to many will stimulate others to consider the possible presence of these lesions in the more resistant infections of the urinary tract.

### REFERENCE

1. Campbell, Meredith F.: *Pediatric Urology*, v. 1, p. 385, New York, The Macmillan Company, 1937.