

# THE DIAGNOSIS OF FOREIGN BODIES IN THE LOWER AIR PASSAGES

H. S. VAN ORDSTRAND, M. D.

The diagnosis of foreign bodies in the bronchi necessarily entails close correlation of an accurate history, physical examination, and stereoroentgenographic study of the lungs. It is often impossible to get a clear-cut history of something having been inhaled into the air passages, and the roentgenograms are occasionally misleading, especially in non-opaque foreign bodies. The purpose of this paper is to stress the diagnostic importance of a careful physical examination of the chest. The necessity of early diagnosis and removal in order to avoid complications such as abscess, bronchiectasis, and pulmonary gangrene is well known.

A positive history of a foreign body will be of the accidental entrance of some organic or inorganic substance into the trachea. Such a history may not be obtained, especially if the onset of symptoms is insidious. This is especially true in infants and very young children where a history of manipulating foreign matter about the upper respiratory tract cannot be obtained.

The manner of lodgment of the foreign body influences the symptoms to an important degree. This has been shown by the experimental work of Weinberg<sup>1</sup> who demonstrated the different degrees of pathological changes produced by vegetable and inert types of foreign bodies. He observed that obstruction caused by inhaled vegetable matter plays little part in the early disturbance of tissue. However, bronchial obstruction develops later and the tissue change which results is similar to that produced by obstructing inert foreign bodies. At this stage, the degree of obstruction rather than the composition of the foreign body determines the pathological changes in the lungs.

Roentgen studies are of value in demonstrating opaque bodies and evidence of obstructive emphysema. Iglaue<sup>2</sup> in 1911 and Manges, Jackson, and Spencer<sup>3</sup> in 1920, described the roentgenographic signs of obstructive emphysema. The first sign consists of increased transparency of the lung on the side the main bronchus is obstructed. This change is demonstrated during expiration. The diaphragm on the same side is depressed during expiration, while the heart and mediastinal structures are displaced toward the opposite side. However, these changes may not be observed on the roentgenograms or at fluoroscopic examination due to the rolling, ball-valve action of a potentially obstructing substance. As shown in one of our cases, the changes may be positive on one roentgenogram (Fig. 1) and negative on another a

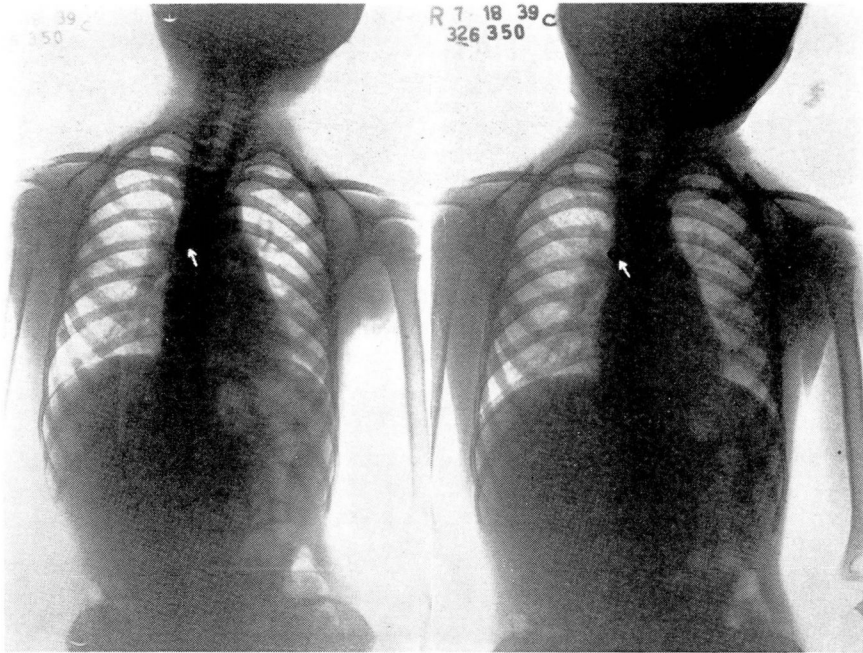


FIG. 1, (Case 1): Roentgenogram of the chest, taken in expiration, showing typical roentgen evidence of obstructive emphysema secondary to a foreign body (metal tip of whistle).

FIG. 2, (Case 1): Roentgenogram taken in different phase of respiration, showing typical roentgen evidence of foreign body in lower air passages, but not showing secondary roentgen changes of obstructive emphysema.

few moments later (Fig. 2). This case, on the other hand, demonstrates the helpfulness of stereoroentgenograms.

The findings on physical examination are of great importance in the diagnosis and localization of a foreign body in a bronchus; this is particularly true in the presence of non-opaque bodies. Inspection may show diminished expansion on the affected side. This is more marked in obstruction of an entire lung than in the unilobar type. Palpation is of aid in determining the site of the cardiac apical impulse as well as the decrease in tactile fremitus over the limits of the lung parenchyma supplied by the obstructed bronchus. A palpable rhonchus may or may not be present. Percussion usually elicits the so-called hyperresonant note over the involved part. Auscultation is usually the most helpful aspect of the physical examination and reveals diminished to absent breath sounds with decreased vocal fremitus over the involved area. Râles may or may not be found, depending on the type of foreign body and the interval between its lodgment and the time of examination. Other noteworthy features are the presence or absence of cyanosis, dyspnea, and stridor. Gerlings<sup>4</sup> stressed the findings in unilobar obstructive emphysema secondary to foreign bodies. These physical signs

## DIAGNOSIS OF FOREIGN BODIES IN LOWER AIR PASSAGES

are similar to those of an obstruction of a main stem bronchus, excepting that they conform with a single lobe pattern. Determination on physical examination is simple when one remembers the normal limits of the various lobes. This is difficult on roentgen study alone.

The following cases represent a foreign body of the metal group and vegetable family respectively.

*Case 1:* The patient was a girl four and one-half years of age who came to the Clinic on July 18, 1939. Two days previously, while blowing a whistle, the small metal tip had been aspirated. There were no immediate ill effects but a wheezing cough developed 24 hours later. No cyanosis was present and the temperature was normal. Wheezing with labored breathing was most marked when the child became excited.

*Physical Examination:* There was lessened expansion of the right side of the chest. An inspiratory rhonchus was palpable and audible over the entire chest, both anteriorly and posteriorly. It was strongest in the third right interspace near the sternum and just to the right of the fifth vertebral spine. The percussion note was hypersonorous over the entire right lung with decreased breath sounds. No crepitant râles were heard. Roentgen examination (Figs. 1, 2, 3) revealed increased transparency of the right side, depression of the right diaphragm, and displacement of the heart and mediastinal structures to the left. On expiration (Fig. 1), a circular, metal foreign body 1 cm. in size was seen at the level of the second right costosternal junction. A roentgenogram taken on inspiration (Fig. 2) and an oblique film (Fig. 3) did not help to localize the foreign body.

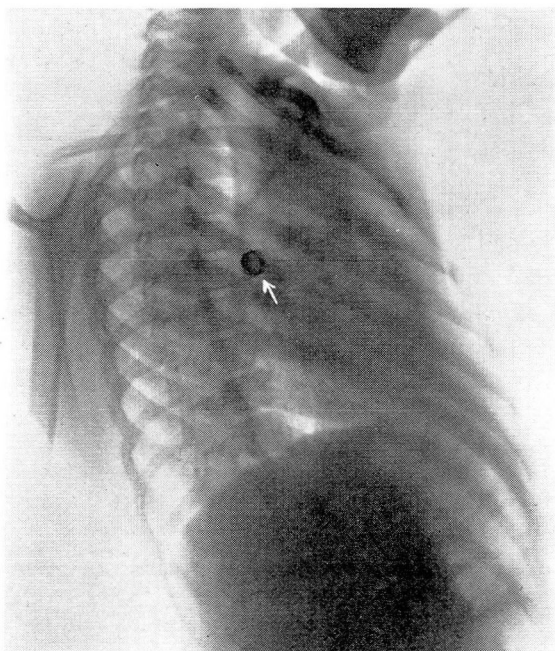


FIG. 3, (Case 1): Oblique film showing presence of foreign body but not localizing it.



## H. S. VAN ORDSTRAND

A diagnosis of foreign body in the right main stem bronchus was made: Bronchoscopy was performed by Dr. Paul Moore and the metal disc was removed.

The postoperative course was uneventful. The cough subsided within 24 hours. The child has remained well.

*Case 2:* A boy, three years of age, came to the Clinic on July 5, 1939. The parents believed the child had aspirated a large peanut three days previously. Paroxysms of coughing developed immediately. There had been no previous cough and he had never had whooping cough or pertussis vaccine.

*Physical examination* revealed decreased expansion of the right lung with hypersonorous percussion note, right posteriorly from the third to ninth vertebral spine, and right anteriorly from the fourth to sixth rib. The breath sounds were suppressed to absent over the right lung in the same areas. Sibilant râles were heard at the left posterior apex, the first to third vertebral spine and anteriorly from the first to the fourth rib. The temperature was 99.6° F.

Roentgen examination of the chest was noncontributory.

A diagnosis of foreign body in the right main stem bronchus producing obstruction of the middle and lower lobes was made. Bronchoscopy was performed by Dr. Moore and half of a peanut was removed from this site. Little inflammatory reaction was noted about the area of lodgment. Following removal, the fever and cough subsided. A few crepitant râles in the right posterior hilar region persisted for 24 hours. The breath sounds and percussion note were normal. When last seen on July 12, 1939, the child had remained free from symptoms.

### SUMMARY

The diagnosis of foreign bodies in the bronchi is made from the correlation of the history, roentgen examination and physical findings. The importance of a good physical examination is stressed from the standpoint of being a strong adjunct in diagnosis as well as its aid to the bronchoscopist in localizing the lodged foreign material.

### REFERENCES

1. Weinberg, J.: Bronchial obstruction produced by organic and inorganic foreign bodies, *J. Thoracic Surg.*, 7:488-497, (June) 1938.
2. Iglauer, S.: Correspondence letter, *Am. J. Roentgenol.*, 7:413, 1920.
3. Manges, W. F., Jackson, C., and Spencer, W. H.: Diagnosis and localization of non-opaque foreign bodies in bronchi, *Am. J. Roentgenol.*, 7:277-285, (June) 1920.
4. Gerlings, P. G.: Foreign bodies in air-passages, causing unilobar obstructive emphysema, *J. Laryng. & Otol.*, 54:23-31, (January) 1939.