

THE VALUE OF PERIMETRY IN BRAIN LESIONS

R. J. KENNEDY, M. D.

The study of visual fields is one of the most important aids in the diagnosis of lesions of the central nervous system. The time and effort involved is well worth while as negative results are of value in excluding certain conditions.

Although the perimeter was introduced many years ago, before the ophthalmoscope, its greatest use has followed the stimulating work of Cushing and Walker¹. They insisted on studies of the visual fields in every case where brain involvement was suspected.

Combined with pupillary changes, muscle paralysis or weakness producing diplopia with retinal lesion, and optic nerve involvement, the study of the visual fields is a valuable adjunct in many lesions in which the eye is directly or indirectly involved.

When the intracranial pathways are involved, the visual fields will indicate the approximate location and extent of involvement, but are not pathognomonic of the disease, although some definite inference can be drawn by progress studies.

Alteration of the visual fields must be considered as only part of the evidence upon which conclusions are based. It is the purpose of this paper to show that in several types of lesions, studies of the visual fields are not only an aid but, combined with encephalography and other neurological studies, are often of value in the diagnosis of certain lesions of the brain.

Perimetry is of value in the following types of cases²:

1. Cases in which the media is clear and the fundus is normal.
2. Cases in which ophthalmoscopic evidence is available, but further explanation is required.
3. Cases where disease of the retina or nerve path should be excluded or in which the media is partially obscured, interfering with satisfactory ophthalmoscopic examination.

Perimetry is especially valuable where visual impairment is apparently the only abnormality. The optic pathways with the site of lesions producing characteristic field defects is shown in figure 1.

Disease of the visual pathway in the region of the chiasm or posterior to it is characterized by changes in the visual field. This is known as anopsia. They are bilateral changes. The characteristic field defect resulting from chiasmal interference is known as bitemporal hemianopsia which, in its typical form, is found in tumor of the pituitary gland. Frequently, in cerebellar tumors, the third ventricle becomes so distended that it practically acts the same as a suprasellar tumor. Binasal

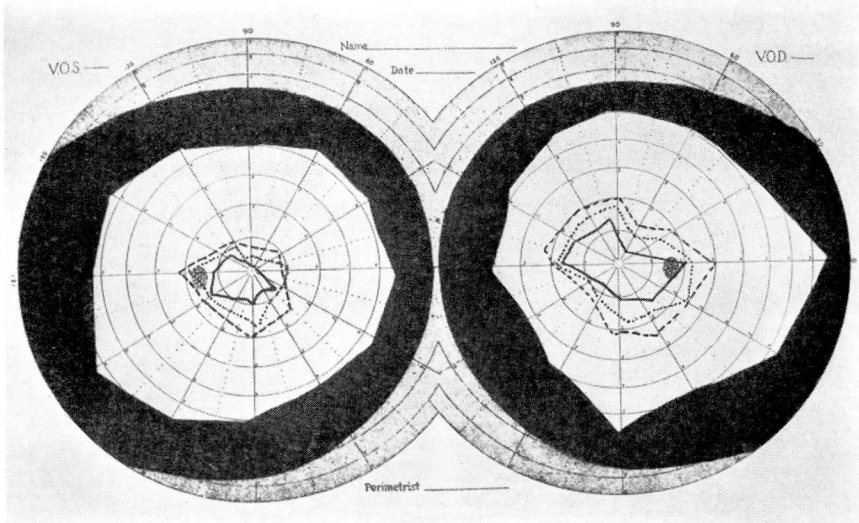


FIGURE 2: Right superior quadrant anopsia for colors in glioma of left motor cortex. (---- red, blue, ——— green.)

and left disc only slightly hazy. Vision in the right eye was 6/6-3 and in the left eye 6/9. Examination of the visual fields revealed left homonymous hemianopsia (Fig. 3). The encephalogram showed a tumor in the right temporal region. Operation was performed and a glioma of right lateral ventricle revealed.

Case 3: A man, 60 years of age, had had failing vision for 8 weeks, with loss of memory, confusion, and headaches. Examination of the fundus showed haziness and early edema of the optic discs, especially in the left eye.

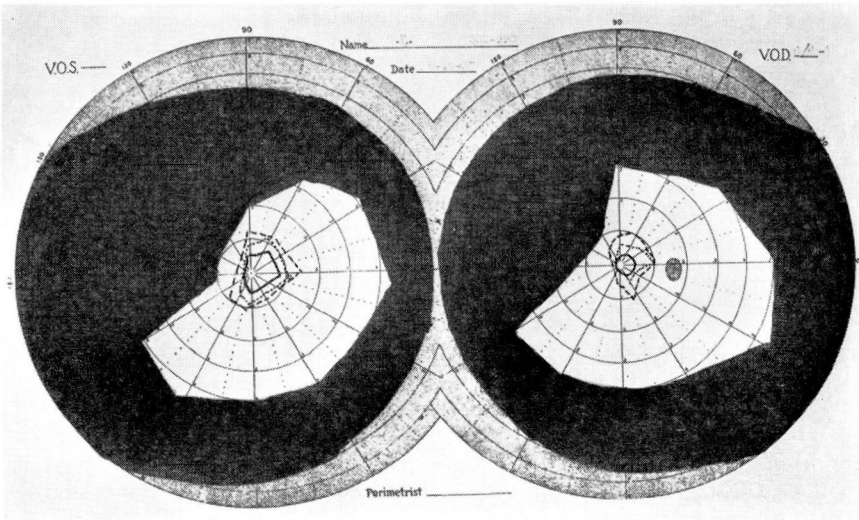


FIGURE 3: Left homonymous hemianopsia. Glioma right lateral ventricle. (---- red, blue.)

THE VALUE OF PERIMETRY IN BRAIN LESIONS

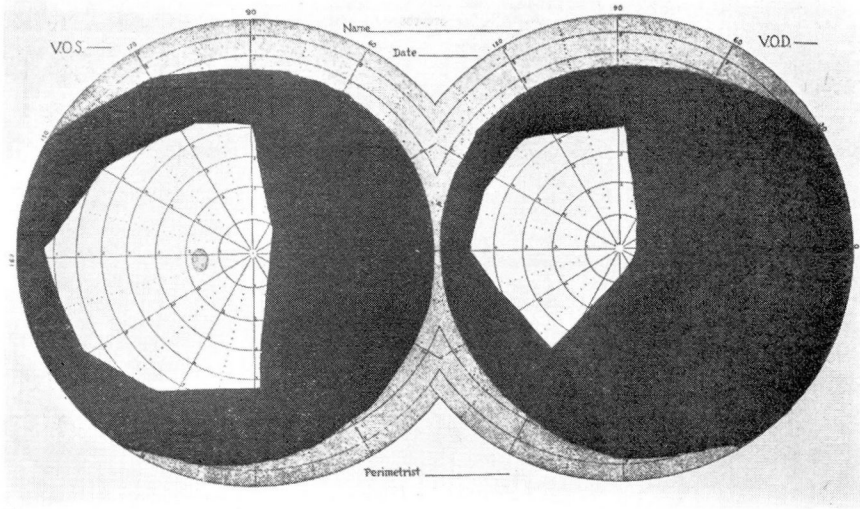


FIGURE 4: Right homonymous hemianopsia. Tumor of left frontal lobe.

Vision in each eye was 6/60. Examination of the visual fields showed right homonymous hemianopsia (Fig. 4). Encephalogram showed displacement of right lateral ventricle to the right. Operation was performed and a tumor of the left frontal lobe revealed.

Case 4: The patient was a man, 43 years of age, who had a history of headaches and changes in personality. Examination of the fundus showed 1 diopter of papilledema in each eye. Vision in each eye was 6/9. There was concentric contraction in both visual fields (Fig. 5). The encephalogram showed poor filling of the ventricles with displacement toward the right, suggesting a

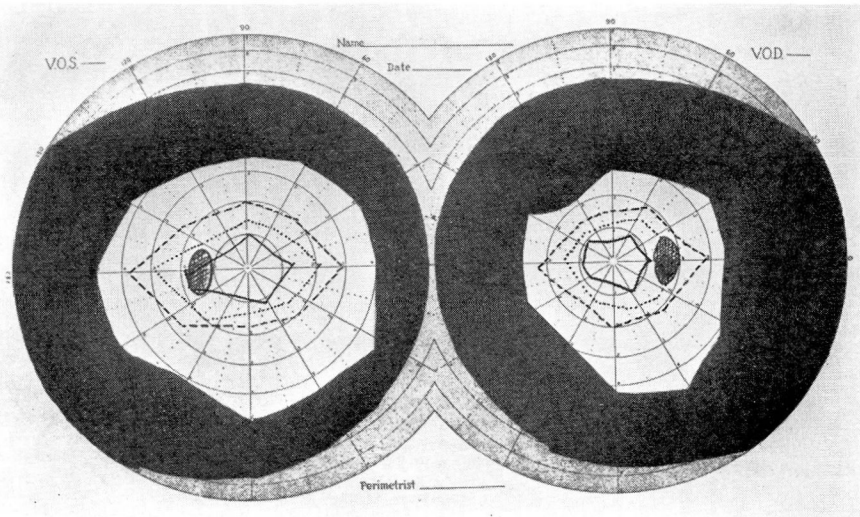


FIGURE 5: Concentric contraction. Glioma left frontal lobe. (---- red, blue, —— green.)

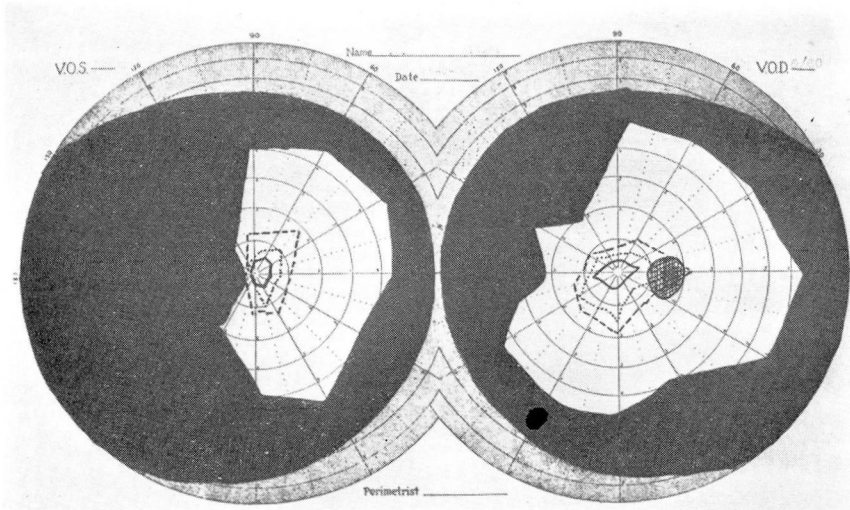


FIGURE 6: Left homonymous hemianopsia. Aneurysm of internal carotid. (----red,blue, —— green.)

space-filling defect of the left parietal area. A left frontal glioma was revealed at operation.

Case 5: A woman, 46 years of age, gave a history of failing vision in the left eye. A constant left-sided headache had been present for 6 months. She complained of weakness and 30 pounds in weight had been lost. Examination of the fundus showed slight haziness of the discs in both eyes, but no papilledema. Corrected vision in the right eye was 6/15 and in the left eye 6/6. Examination of the visual fields showed left homonymous hemianopsia (Fig. 6).

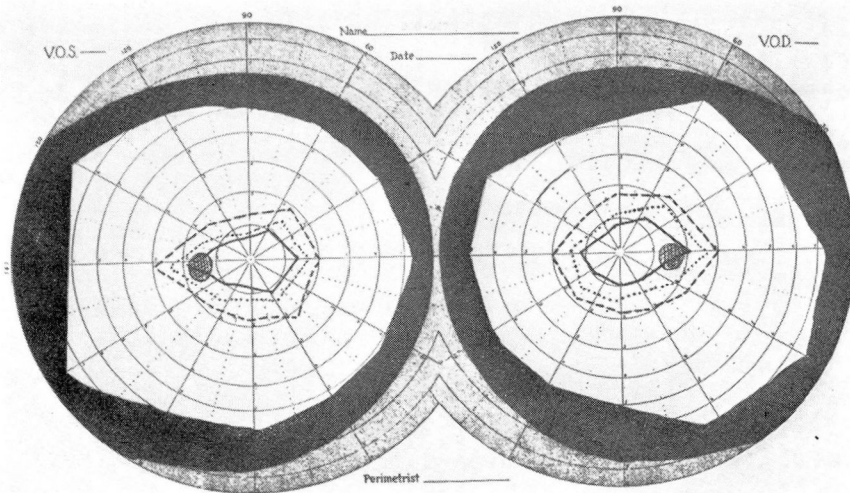


FIGURE 7: Essentially normal fields. Glioma right parietal lobe. (----red,blue, —— green.)

THE VALUE OF PERIMETRY IN BRAIN LESIONS

The encephalogram was negative. Operation revealed aneurysm of the internal carotid.

Case 6: The patient was a man, 33 years of age, who had had convulsions for 7 years. Examination of the fundus showed no papilledema and only slight haziness of the discs. The visual fields were normal (Fig. 7). Vision in the right eye was 6/5 and in the left eye 6/6. The encephalogram showed poor filling of the right lateral ventricle. A glioma of right parietal lobe was revealed at operation.

Table I shows nine cases of tumor of the frontal lobe; positive encephalograms were present in all of the cases. The visual fields are not diagnostic as to the location of the lesion.

TABLE I

Visual Fields in Tumors of the Frontal Lobe

9 CASES

Concentric contraction	5
Enlarged blind spot, right eye.....	1
Right homonymous hemianopsia	1
Normal visual fields	2
Positive encephalograms	9

SUMMARY

Perimetry is of definite value as an adjunct to the diagnosis of intracranial lesions, but in itself usually is not sufficient. It is of definite aid in pituitary tumors but less exact in other lesions. Visual fields defects are sometimes difficult to explain, such as the right homonymous hemianopsia which occurred in the tumor of the frontal lobe in Case 3.

Generally speaking, perimetric fields give accurate and dependable information. At times they may be misleading, and we must look further for diagnosis. In such cases the encephalogram is of distinct advantage, combined, of course, with a good history and physical examination.

REFERENCE

1. Cushing, H. and Walker, C. B.: Studies of optic nerve atrophy in association with chiasmal lesions, *Arch. Ophth.*, 45:407-437, (September) 1916.
2. Traquair, H. M.: *An Introduction to Clinical Perimetry*, 3rd ed. C. V. Mosley Co., St. Louis, 1938.