

INTRATHORACIC GOITER

GEORGE CRILE, JR., M. D.

INCIDENCE

Although many large goiters dip beneath the clavicles for a short distance, true intrathoracic goiters with extension downward as far as the arch of the aorta are relatively rare. In a series of thyroidectomies performed on 11,800 patients at the Cleveland Clinic Hospital there were only 97 cases in which the goiter descended to the arch of the aorta or below it, an incidence of less than 1 per cent.

PATHOLOGY

It is a safe rule to consider all intrathoracic goiters to be adenomas originating in normally situated thyroid glands. All large intrathoracic goiters are adenomatous; in no instance in this series did a diffuse goiter descend to the arch of the aorta, and in all cases the adenomas had their origin in normally situated thyroid glands. We have seen several cases in which papillary adenomas arising in aberrant thyroid tissue and not connected with the thyroid itself were present in the superior mediastinum. However, these tumors are extremely rare and must be considered as a separate entity from the ordinary endemic goiter.

Intrathoracic goiter is a disease of the mid and latter span of life, the average age of the patients in this series being 53 years. The youngest patient was 32 years of age and in only 7 per cent of the cases were the patients under 40 years of age.

Since only adenomatous goiters become intrathoracic, it is not surprising to find the incidence of intrathoracic goiter highest in the older age groups in which adenomas are more common.

ETIOLOGY

There is little doubt that the musculature of the neck plays a large part in directing the growth of an adenomatous goiter. Intrathoracic goiters as compared with other forms of endemic goiter are relatively more common in men than in women. They are also more commonly seen in stocky, short-necked individuals, in whom the pre-thyroid muscles are well developed. The pressure from these muscles tends to prevent the outward expansion of the goiter in the neck and gradually forces the adenoma downward into the superior mediastinum. Here for a time the adenoma may be freely movable, rising with deglutition or with straining, and descending again into the thorax. As the adenoma enlarges, it delivers from its intrathoracic position with less ease but still retains its attachment to the thyroid gland. Finally it becomes imprisoned in the thorax and continues to expand downward and laterally, the narrow thoracic outlet finally preventing its emergence into the neck.

SYMPTOMS

Patients with intrathoracic goiters may be divided, according to symptoms, into three groups: First, those with no symptoms; second, those with symptoms resulting from an associated hyperthyroidism; and third, those with symptoms resulting from pressure on the trachea and great vessels.

Large intrathoracic goiters are often completely symptomless and may appear entirely harmless. On the other hand very small intrathoracic goiters, situated in certain positions, may produce intolerable symptoms of pressure and tracheal obstruction.

The most severe symptoms occur in the cases in which the pressure of the enlarging adenoma is exerted exactly at the level of the thoracic out-

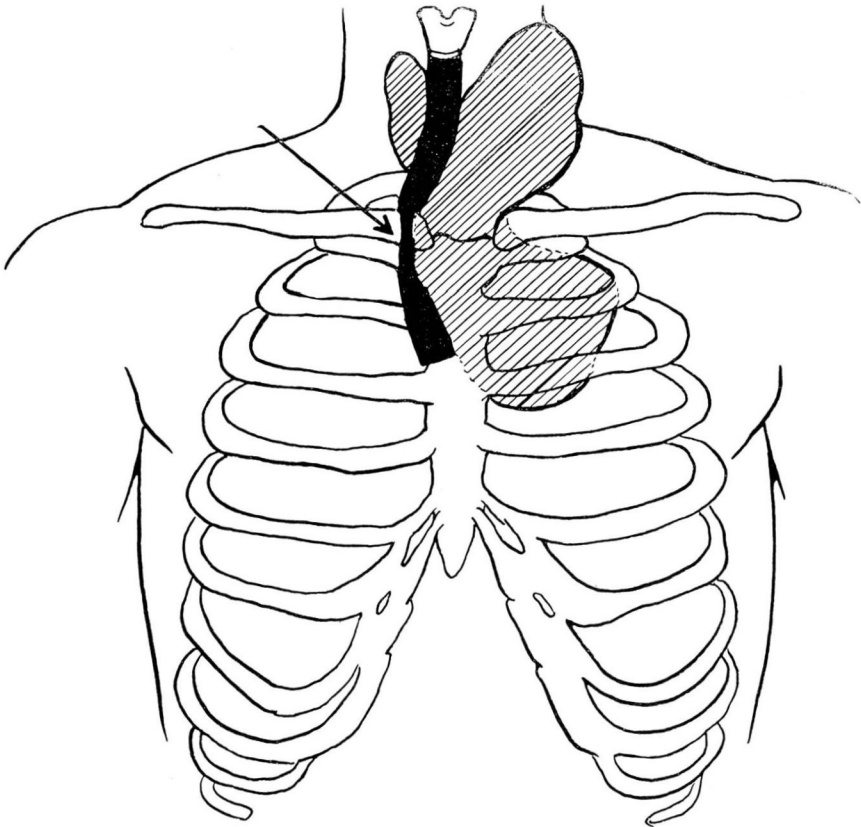


FIGURE 1: Arrow points to compression of trachea at level of thoracic outlet. Note that either flexing or extending the head would force larger portions of the dumbbell-shaped goiter through the narrow thoracic outlet and increase the pressure on the trachea.

let, the narrow and rigid bony structures at this level rendering it impossible for the tumor to expand without compressing the trachea.

The most common type of tracheal compression seen at this level is the

INTRATHORACIC GOITER

result of a dumbbell-shaped goiter, part of which lies above the thoracic outlet in the neck and the other part below the outlet and in the thorax (Fig. 1). The isthmus of the gland compresses the trachea between itself and the bony structures of the outlet and often results in severe symptoms of obstruction. To make matters still worse, extension of the neck, straining, or swallowing tends to lift the lower half of the dumbbell out of the thorax and through the contracted outlet, giving further pressure. Flexing of the neck, on the other hand, forces the cervical enlargement downward through the rigid outlet and again increases the symptoms of pressure. Hence, it is common for patients with intrathoracic goiter to complain that flexing or extending the neck, as in bending forward or in lying flat on the back, produces an unpleasant sensation of choking.

A second type of intrathoracic goiter which may produce obstruction of respiration is a relatively small adenoma located at the level of the thoracic outlet and situated either directly anterior to the trachea, compressing it backward against the vertebral column, or situated directly behind the trachea and compressing it forward against the sternum. The trachea may be considerably angulated and distorted by relatively small adenomas in these locations and the resulting symptoms of obstruction may be severe.

In contrast to the severe obstructive symptoms frequently experienced by patients with the above types of goiter, a high percentage of patients with large intrathoracic goiters—nearly 50 per cent in this series—had no symptoms referable to pressure or to tracheal obstruction. If the cervical portion of the thyroid is not enlarged sufficiently to result in fixation of the tumor, there is nothing to prevent an adenoma of the lower pole from growing downward into the thorax and expanding into the lung fields without producing symptoms of tracheal compression. In one case (Fig. 2) the entire upper lung field on the right was obliterated by an enormous intrathoracic goiter, which had expended its growth energy entirely by displacement of lung tissue. There was no compression of the trachea, and not the slightest symptom of pressure. The degree of tracheal obstruction will depend not so much upon the size of the tumor as upon its ability to expand without producing pressure on the trachea at the level of the thoracic inlet.

Hyperthyroidism was present in 50 per cent of all patients operated upon for large intrathoracic goiters and manifested itself in the usual way. In some cases it may be difficult to determine whether dyspnea, in a patient with an intrathoracic goiter, is the result of mechanical factors, the result of hyperthyroidism, or whether it is caused by primary cardiac disease.

The most common symptom associated with intrathoracic goiter is dyspnea, but in a high percentage of cases the dyspnea is secondary to an

associated hyperthyroidism or is the result of myocardial changes incidental to advancing age. In about 50 per cent of the cases, dyspnea was

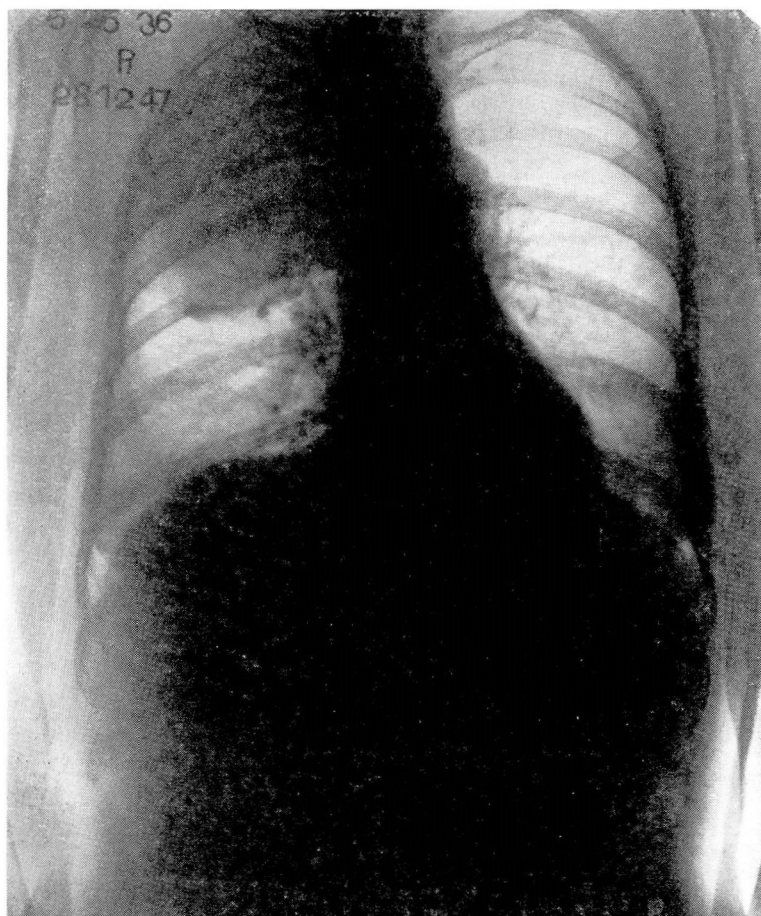


FIGURE 2: The entire upper lung field on the right is obliterated by an enormous intra-thoracic goiter which had expended its growth energy entirely by displacement of lung tissue. There was no compression of the trachea and no symptoms of pressure.

a leading complaint and could not be explained solely on the basis of hyperthyroidism or myocardial damage. This symptom was completely relieved by operation in the great majority of these cases.

In 27 per cent of the cases the patients complained of choking sensations usually brought on by swallowing or by extending or sharply flexing the neck. The presence of this symptom is extremely helpful, as it is a certain indication that symptoms of obstruction are either present or are impending.

A late and specific symptom of tracheal obstruction is the development of stridor. This was noted in only 12 per cent of the cases. It is

INTRATHORACIC GOITER

characteristic of the stridor associated with intrathoracic goiter in that it occurs only when the patient is in certain positions, and most commonly during sleep.

Cough is rare and frequently represents a late symptom of intrathoracic goiter. When present it is often of a peculiar brassy quality. As a rule, however, there is little irritation of the trachea even when a moderate degree of compression is present. In severe cases, longstanding obstruction of the trachea may result in bronchiectasis, which signifies its presence by a productive cough.

Dysphagia, resulting from pressure on the esophagus, is rare and did not occur in any case in this series.

A sense of pressure, occasionally so severe as to be classified as a substernal pain, may be produced by an intrathoracic goiter. In some cases it may be confused with angina pectoris if a careful analysis of the complaint is not made. This symptom is rare, and the relation of the pressure sensation to swallowing and to the position of the neck, rather than to excitement or exertion, are important points in relating the symptom to the presence of an intrathoracic goiter.

Hoarseness is rarely caused by an intrathoracic goiter. In only 2 per cent of this series (in all of which the goiter descended to the arch of the aorta or below) was there a preoperative paralysis of the recurrent laryngeal nerve. A change in the quality of the voice, secondary to distortion of the larynx and trachea, is more commonly seen, and in some instances difficulty in singing occurs.

In spite of the fact that severe symptoms of pressure, such as choking and stridor, are present in less than one-third of the cases, it is nevertheless true that many patients who have no complaints prior to operation will obtain striking improvement in their general sense of well being after the removal of a large intrathoracic goiter. In these cases, just as in the case of women in whom large symptomless fibroids of the uterus slowly develop, the pressure symptoms have come on so gradually that the patient accustoms himself to their presence, and scarcely realizes that they have been a burden until the tumor is removed. So, in the case of patients with large goiters, obscure sensations which they have come to accept as normal will disappear and leave the patient with a sense of well being that has not been experienced for years.

DIAGNOSIS OF INTRATHORACIC GOITER

An intrathoracic goiter can easily be overlooked, and unless routine roentgenograms of the chest are taken a small number of cases will always escape recognition. Most intrathoracic goiters are palpable and can sometimes be percussed. The symptoms of tracheal obstruction or the presence of dilated veins over the thorax may indicate the presence of an intrathoracic goiter. But the final decision as to the nature and extent

of the mediastinal tumor usually depends upon the roentgen findings.

In the anteroposterior view of the chest the trachea can be seen to be compressed or displaced by a smooth shadow descending from the neck. As a rule, this shadow completely fills the area just below the thoracic inlet, and becomes narrower as it descends to meet the shadow of the aorta. As Nichols¹ has pointed out, the demonstration of an angle between the mediastinal tumor and the arch of the aorta differentiates an intrathoracic goiter from an aortic aneurysm. Under the fluoroscope, or by means of the chimograph, the absence of expansive pulsation and the tendency of the tumor to rise when the patient swallows will further distinguish an intrathoracic goiter from an aortic aneurysm. Finally, a lateral view is indispensable in demonstrating the relationship of the tumor to the trachea and in revealing small adenomas compressing or displacing the trachea from in front or from behind.

TREATMENT OF INTRATHORACIC GOITER

The treatment of intrathoracic goiter is surgical. Roentgen therapy is utterly ineffective in reducing the size of an intrathoracic goiter or in alleviating the symptoms it produces. These tumors are well differentiated adenomas, are not sensitive to irradiation, and do not diminish in size in response to treatment with iodine.

When an intrathoracic goiter is large enough to descend to or below the arch of the aorta, its removal may present technical difficulties so the risk of thyroidectomy is considerably increased. Thus, in older patients who have large but symptomless intrathoracic goiters, it is not always wise to advise their removal. This is particularly true in patients over 65 years of age in whom life expectancy may be shortened by the presence of arteriosclerosis, hypertension, or myocardial damage. In such cases, if the goiter is not enlarging, if it is producing no symptoms, and if hyperthyroidism is not present, it is more than likely that the patient will die of other causes before the goiter produces any discomfort. But in younger patients, in patients with hyperthyroidism, and in patients in whom symptoms of obstruction are present, thyroidectomy must be performed unless strong contraindications are present.

TECHNIC

Since intrathoracic goiters are adenomas originating in normally situated thyroid glands, it is clear that the operation for intrathoracic goiter should be directed primarily toward the cervical portion of the tumor. The operation can be conveniently divided into five definite steps:

- (1) The cervical portion of the thyroid is dissected free of its capsule of muscle and fascia.
- (2) The superior pole is clamped and divided.

INTRATHORACIC GOITER

(3) The tracheal attachments of the thyroid are cut over hemostats whose points are always directed away from the tracheo-esophageal groove and into the thyroid tissue where there is no possibility of injury to the recurrent nerve.

Up to this point no direct attack on the intrathoracic portion of the gland has been made. With the cervical portion of the gland freed from the trachea, with the superior pole cut and tied, and with the isthmus of the gland divided, the intrathoracic portion tends spontaneously to slide upward into the incision.

(4) Gentle traction is made on the intrathoracic portion, using the cervical portion of the gland as a handle.

(5) As the gland delivers upward out of the thorax, it is carefully dissected free of its capsule. The lateral thyroid vein and the branches of the inferior thyroid vessels are then clamped, cut and tied as they present themselves in the field.

There is rarely any bleeding from adhesions or fibrous bands that may be present at the base of the intrathoracic extension. The operation should be practically bloodless if a careful dissection is performed and if the blood supply of the adenoma is meticulously ligated before making a forcible attempt to withdraw the intrathoracic extension.

The recurrent nerve is rarely displaced by an intrathoracic goiter except as it is pressed further medially into its normal position in the tracheo-esophageal groove. Hence, if the operation is performed gently, and if the capsule is dissected carefully as the gland is delivered into the wound, there is little danger of injury to the intrathoracic portion of the nerve. The greatest danger of nerve injury is at the point where the nerve comes forward to enter the larynx. Fixation of the intrathoracic portion of the goiter, as we have already mentioned, often renders it impossible to rotate the gland up from its bed. Dissection under these circumstances must be carried blindly downward along the side of the trachea, and this can be done with safety only if the points of the hemostats are always inserted into the thyroid tissue. Hemostats must be carefully applied, because if large bites are taken the ligatures may include the nerve and result in its paralysis. In small goiters, the gland can be rotated up into the field before it is liberated from the trachea, the lateral thyroid vein can be ligated and divided and the course of the recurrent nerve can be carefully avoided.

Collapse of the trachea probably never occurs except secondarily to bilateral injury to the recurrent nerves. The appearance of collapse is the result of strong inspiratory efforts in an attempt to suck air through the narrow chink between the paralyzed cords. The suction draws the walls of the trachea together and gives the appearance of spontaneous collapse.

Occasionally, during the delivery of a large adenoma, compression of the trachea will take place, but the normal shape of the trachea is restored as soon as the pressure is removed. Since force should not be used in delivering the goiter, this complication should rarely occur.

It is nearly always possible to remove an intrathoracic goiter without splitting the sternum or disturbing the bony outlet of the thorax. Splitting the sternum produces considerable shock and increases the incidence of postoperative pulmonary complications. This procedure should therefore be avoided if possible. In this series it was necessary to split the sternum in only one case and the outcome in this instance was fatal, the patient dying as the result of a mediastinal hemorrhage.

In all but three of the remaining 96 cases the goiter was removed through the usual cervical incision. In two of these three cases large cervical adenomas were removed with relief of the symptoms of pressure. In view of the patients' debilitated condition, and the technical difficulties involved, it was not thought to be advisable to attack the intrathoracic portion of the gland. In a third case, every effort was made to remove the intrathoracic portion but the lobes had extended bilaterally behind the trachea and into the mediastinum for a distance of 3 inches below the arch of the aorta. It was technically impossible to remove the tumor and matters were further complicated by the presence of advanced bronchiectasis which predisposed the patient to pneumonia and afforded a strong contraindication to splitting the sternum.

In all other cases (over 95 per cent of the total series) the entire tumor was removed through an ordinary goiter incision and without disturbing the bony structures of the thorax. In several cases the tumor was too large to be delivered intact through the thoracic outlet, but its complete removal was successfully accomplished by ligating the blood supply entering from above, opening the capsule of the adenoma, and then breaking up the tumor and removing it piecemeal. This procedure is accompanied by little or no bleeding and, after the removal of sufficient tissue, the capsule of the adenoma can be delivered through the thoracic outlet and excised. Bilateral extracapsular ligation of the main trunks of the inferior thyroid artery is of value in these cases whenever it is technically possible to do it.

There has been considerable controversy as to the treatment of the cavity left by removal of an intrathoracic goiter. Some have insisted that the cavity be packed open in order to control bleeding², wall off the cavity, and prevent mediastinal extravasation of blood or serum. This technic is unquestionably of value in the rare case in which there is persistent and uncontrollable oozing from the walls of the cavity. But in the great majority of cases, the cavity left by the removal of an intrathoracic goiter is merely a *potential* space and is quickly obliterated by the pleura and mediastinal tissues as they are forced into it by the intra-

INTRATHORACIC GOITER

thoracic pressure. By the use of packing, this potential space is transformed into a true cavity which is highly susceptible to infection and may drain for weeks.

In our hands the most satisfactory treatment of the mediastinal space has been closure without packing. Two or three small rubber drains are left in the cavity for several days to allow blood and serum to drain freely until the walls of the cavity fall together and become firm enough to prevent mediastinal extravasation. Better drainage is afforded by rubber than by gauze and the results with this method have been superior not only in respect to wound healing but also in respect to control of mediastinal extravasation. No fatal case of mediastinal hemorrhage has occurred since this technic was adopted some 5 years ago.

DISCUSSION

In this series of 97 cases, all of which were large intrathoracic goiters descending to or below the arch of the aorta, there were only two post-operative deaths in patients who did not have hyperthyroidism. The mortality rate from removal of these tumors, large though they may be, should not be high, provided the general condition of the patient is satisfactory.

When hyperthyroidism is associated with an intrathoracic goiter, the risk is definitely increased. If the patient is under 55 years of age, there is little danger whether hyperthyroidism is present or not. In the oldest age groups, when the patients are in the late sixties and seventies and have both hyperthyroidism and large intrathoracic goiters, the risk of operation is increased to about 20 per cent. It is thus clear that in older patients in whom active hyperthyroidism complicates an intrathoracic goiter, a certain amount of conservatism must be exercised in regard to the surgical treatment of the goiter.

Technical accidents, i.e., mediastinal hemorrhage, asphyxia, and infection have not been important causes of postoperative death. Three patients in this series, all cases operated in the early period in which the wounds were packed open with gauze, died as a result of mediastinal hemorrhage. There were no deaths from asphyxia or from mediastinitis.

Pneumonia was the most common single cause of death following operations for intrathoracic goiter. Other fatal complications in these elderly patients have been coronary occlusion and cerebral hemorrhage.

In view of the tendency to pulmonary complications, it is clear that general anesthesia with its attendant depression of the cough reflex and of cellular metabolism should be avoided. The operation can be performed under local anesthesia with no discomfort to the patient and with less risk of the necessity for an emergency tracheotomy. Intratracheal anesthesia is unnecessary and is actually undesirable because of its tendency to produce tracheal irritation and increase the amount of

mucus postoperatively. In addition, the use of intratracheal anesthesia necessitates deep narcosis with its attendant danger of pneumonia. In only two instances in this series was it necessary, because of respiratory obstruction, to perform a tracheotomy at the time of operation. These tracheotomies were promptly closed and convalescence was complicated by only slight infection in the wounds. If the operation is performed under local anesthesia, if the upper attachments of the goiter are completely freed, and if the goiter is delivered with extreme gentleness, there should rarely if ever be any obstruction to respiratory exchange.

SUMMARY

1. Large intrathoracic goiters are rare. Ninety-seven cases in which the tumor descended to or below the arch of the aorta are reported.
2. Intrathoracic goiters are almost invariably adenomas originating in a normally situated thyroid gland.
3. Large intrathoracic goiters may give no symptoms if their growth energy is directed toward displacement of lung tissue rather than toward compression of the trachea.
4. Compression of the trachea is most commonly seen at the level of the thoracic outlet.
5. It may be difficult in patients with intrathoracic goiter to differentiate among dyspnea due to organic heart disease, hyperthyroidism or tracheal compression.
6. Surgery is the only effective treatment for intrathoracic goiter.
7. The technic of operation is outlined.
8. The risk of operation is slight when the patient is not old or debilitated.
9. In patients over 65 years of age, in whom active hyperthyroidism is associated with an intrathoracic goiter, the risk of operation is considerably increased. In these cases, if the patients' general condition is not satisfactory, conservative therapy is justified.

REFERENCES

1. Nichols, B. H.: Personal communication.
2. Lahey, Frank: Intrathoracic goiter, *S. Clin. North America*, 16:1613-1629, (December 1936).