



# The Maze procedure: surgical therapy for refractory atrial fibrillation

PATRICK M. MCCARTHY, MD; LON W. CASTLE, MD; RICHARD G. TROHMAN, MD; TONY W. SIMMONS, MD;  
JAMES D. MALONEY, MD; ALLAN L. KLEIN, MD; RICHARD D. WHITE, MD; JAMES L. COX, MD

■ Although atrial fibrillation is well tolerated by most patients, in some patients the consequences may be severe. The Maze procedure is a new open-heart operation that creates a carefully designed maze of incisions in the atrial myocardium; this maze then acts as an electrical conduit to channel atrial impulses from the sinoatrial node to the atrioventricular node. The Maze procedure has been shown to restore sinus rhythm and atrial systole (thus reducing the risk of thromboembolism), improve hemodynamics, alleviate palpitations, and eliminate the need for antiarrhythmic and anticoagulant drugs. We describe our first patient to undergo this operation.

□ INDEX TERMS: ATRIAL FIBRILLATION □ CLEVE CLIN J MED 1993; 60:161-165

**A**TRIAL FIBRILLATION (AF) is the most common sustained cardiac arrhythmia and is present in approximately 0.4% of the general adult population.<sup>1,2</sup> Medication and electrical cardioversion have only limited success in restoring normal sinus rhythm.<sup>3-7</sup>

Although AF is well tolerated by most patients, in some patients the consequences may be severe. Symptomatic rapid AF can be disabling, and patients with AF have a significant risk (approximately 5% per year) of systemic embolization. AF is one of the most frequent causes of stroke in the United States.<sup>8-12</sup> Some patients also suffer from hemodynamic compromise

(secondary to rapid ventricular rates and loss of atrial systole)<sup>13-16</sup> and from side effects associated with antiarrhythmic drugs and anticoagulants.<sup>2,5,6,17</sup> The Maze procedure is a new surgical approach to correct the consequences of AF. We describe our first patient to undergo this operation.

## CASE HISTORY

A 66-year-old man was evaluated in December 1990 because of symptomatic AF unsuccessfully treated with multiple antiarrhythmic medications. The onset of palpitations was 9 years earlier. During those years, the AF was usually paroxysmal, and cardioversion was performed several times. During 1990, the patient was hospitalized four separate times for symptomatic episodes of rapid atrial flutter, and multiple cardioversions were performed with only temporary success. The patient also developed a pulmonary embolus secondary to deep vein thrombosis; this was treated with an inferior vena cava titanium filter. Over the last 6 months

From the Department of Thoracic and Cardiovascular Surgery, The Cleveland Clinic Foundation (P.M.M., L.W.C., R.G.T., T.W.S., J.D.M., A.L.K., R.D.W.); and the Department of Cardiovascular Surgery, Washington University, St. Louis, Mo (J.L.C.).

Address reprint requests to P.M.M., Department of Thoracic and Cardiovascular Surgery, F25, The Cleveland Clinic Foundation, 9500 Euclid Avenue, Cleveland, OH 44195.

of 1990, AF and atrial flutter became more frequent. The patient was in chronic atrial flutter by December 1990. AF and atrial flutter were associated with fatigue, shortness of breath, a "smothering" feeling with exertion, and near syncope (New York Heart Association class III).

Because of these symptoms, the patient retired from his occupation as a barber. Over a 10-year period he had been treated with digoxin, propranolol, quinidine, disopyramide, procainamide, verapamil, amiodarone, propafenone, atenolol, and moricizine. Each medication was ineffective or led to unacceptable side effects. Amiodarone provided effective rhythm control but had to be stopped when pulmonary fibrosis developed. Cardiac catheterization in 1984 and 1990 demonstrated normal coronary arteries. Echocardiography showed normal ventricular size and function with no evidence of valvular pathology. Thyroid function tests were normal.

In January 1991, the patient underwent the Maze procedure originated by Dr. Cox (who was present for the operation).<sup>18-21</sup> Full-thickness atrial incisions divided the macroreentry circuits responsible for AF or atrial flutter. The Maze operation is standardized, rather than tailored to the individual patient, so no intraoperative mapping is required. After preliminary dissection, the patient was placed on cardiopulmonary bypass. During the 59-minute aortic cross-clamp time, an incision in the posterior left atrium encircled (and electrically isolated) the pulmonary veins, a potential site of macroreentry circuits. Another incision to the mitral valve annulus further divided the left atrium to decrease the amount of atrial tissue available to sustain a macroreentry circuit. The coronary sinus and mitral and tricuspid valve annuli were treated with  $-60^{\circ}\text{C}$  "cryolesions" to disrupt microscopic atrial fibers. Both atrial appendages were completely excised (they are a potential source of emboli and reentry circuits). Finally, right atrial incisions were made medial and posterolateral to the sinoatrial (SA) node complex. When the Maze incisions were completed, impulses arising normally in the SA node propagated inferiorly (contained within the suture lines), then medially to the tricuspid valve annulus, atrial septum, and atrioventricular (AV) node. The impulses also innervate the left atrium.

The patient spontaneously resumed normal sinus rhythm at the conclusion of the 4-hour operation. Intraoperative transesophageal echocardiography documented atrial contraction as shown by a small reversal of flow in the right upper pulmonary vein during atrial

systole. The left ventricular inflow also showed both an early filling wave (E wave) and a late filling wave (A wave) due to atrial contraction.

The patient was extubated the morning after surgery. In the first weeks after the operation, the patient had intermittent episodes of AF which were successfully controlled with flecainide. Three weeks after surgery, we were satisfied that he would experience no further AF, and he was discharged. Flecainide dosage was tapered off; at 3 months after the operation, flecainide therapy was discontinued. At a 12-month follow-up visit, the patient was in normal sinus rhythm without medication. Cine-magnetic resonance imaging confirmed atrial systole. The patient had resumed employment, and was New York Heart Association class I 2 years after surgery.

#### DISCUSSION

A variety of antiarrhythmic medications are available to treat AF. When used in conjunction with electrical cardioversion—and, ideally, with treatment of an underlying reversible condition, such as thyrotoxicosis or mitral valve disease—normal sinus rhythm resumes. However, for most patients these treatments are either ineffective or only temporarily successful. These patients face the consequences of AF the rest of their lives: symptomatic tachycardia, impaired hemodynamic function, increased thromboembolic risk, and the risks associated with the chronic use of antiarrhythmic and anticoagulant drugs. This patient illustrated many of these problems: episodes of tachycardia caused unacceptable symptoms, and impaired hemodynamics led to fatigue and dyspnea on exertion. The only effective medication, amiodarone, had to be stopped due to severe pulmonary fibrosis. This patient became disabled due to his AF symptoms and had to retire early.

The small group of patients disabled by the tachycardiac symptoms of AF may be considered for radiofrequency ablation of the AV node. This procedure leads to permanent complete heart block and requires inserting a rate-responsive pacemaker; episodes of tachycardia are controlled, and antiarrhythmic medications can usually be discontinued.<sup>22-25</sup> However, the atria continue to fibrillate, so there is no atrial systole; fatigue and dyspnea may continue.<sup>23</sup> Pacemaker failure may lead to syncope and even death.<sup>23,24</sup> Also, the risk of thromboemboli is unchanged, and the long-term use of anticoagulants may be required.

### Anticoagulation therapy

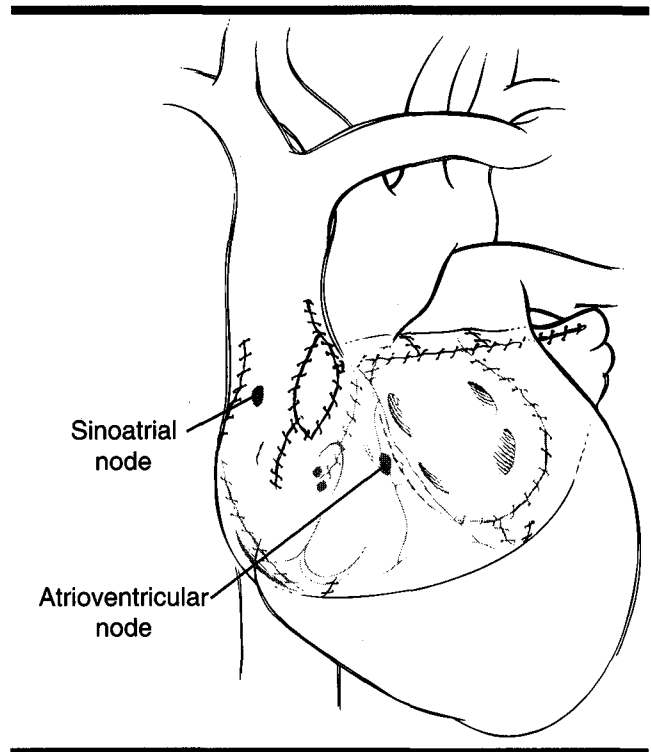
Recent prospective randomized trials<sup>26-28</sup> indicate an approximately 5% per year risk of stroke (most of which were fatal or disabling) for control patients (no anticoagulation) with nonrheumatic AF. Warfarin may decrease this risk by 59% to 86%, but the annual risk of major bleeding was significant (3.5% in one study,<sup>26</sup> and 1.7% in another<sup>27</sup>). For a young patient, a life-long requirement for warfarin anticoagulation would carry a significant risk.

### Surgical attempts

Surgical therapies for AF have heretofore yielded only limited success. The left atrial isolation procedure<sup>29,30</sup> is performed by extending a standard left atriotomy anterior and posterior to the mitral valve annulus. The coronary sinus is treated with a cryoablation to ablate the accompanying atrial fibers. After the operation, the sinus node resumes its normal activity and drives the ventricles through the AV node, reestablishing a regular heart rhythm. The normal right-side cardiac output is delivered across the lungs to the left atrium and left ventricle (which slightly increases left ventricular end-diastolic volume), resulting in normal cardiac output. However, the electrically isolated left atrium may continue to fibrillate, and, therefore, the thromboembolic risk remains. The left-atrial isolation procedure has been essentially abandoned.

In 1985, Guiraudon introduced the corridor procedure,<sup>31,32</sup> in which transmural right and left atrial incisions divide the atria into a "corridor" containing the SA node and AV node. The SA node impulse drives the ventricles, but the atria outside the corridor may continue in AF, with the chronic risk of emboli. Of 20 patients reported,<sup>32</sup> 8 required reoperation to further electrically isolate the corridor. Five patients continued to require antiarrhythmic drugs. The theoretical design and early results of the corridor procedure suggest that it has little benefit over AV node ablation with insertion of a pacemaker, which is not an open-heart procedure.<sup>33</sup>

The Maze procedure—so named because it creates an electrical "maze" of incisions to channel the atrial impulses from the SA node to the AV node, thereby restoring synchrony—alleviates the three physiologic sequelae of AF (tachycardia, thromboembolism, and hemodynamic compromise). It restores sinus rhythm with resolution of palpitations. Atrial contraction and AV synchrony are also restored, leading to improved hemodynamics with decreased risk of thromboem-



**FIGURE.** The Maze procedure: a series of incisions in both atria divide the macroreentry circuits responsible for atrial fibrillation. Sinus rhythm is restored with conduction from the sinoatrial node to the atrioventricular node. Both right and left atria are innervated and contract during atrial systole.

bolism. Furthermore, antiarrhythmic and anticoagulant medications can be discontinued.

Macroreentry circuits were postulated<sup>29-31</sup> and demonstrated in humans<sup>19</sup> to be the underlying mechanism of AF. The Maze procedure achieves its effect by surgical division of the macroreentry circuits in both atria.<sup>20</sup> The atrial tissue between the incisions is small, and large macroreentry circuits are interrupted.<sup>20</sup> The precise surgical technique has been previously described (Figure).<sup>21</sup>

Cox recently reported 22 patients who underwent the Maze procedure.<sup>34</sup> At the Cleveland Clinic, 11 patients had undergone Cox's Maze procedure as of March 1992.<sup>35</sup> The Cleveland Clinic patients had a mean age of 46 and had been treated unsuccessfully with a mean of five antiarrhythmic medications. After the Maze procedure, all patients resumed sinus rhythm with documented atrial systole. Two patients (with sick sinus syndrome preoperatively) required DDD-R pacemakers which are currently functioning as backup systems. One patient with Yamaguchi's disease, a

**TABLE**  
**THE MAZE PROCEDURE: CANDIDATES**

Patients who fail drug therapy due to:
Severe symptoms
Drug side effects
Contraindication for anticoagulants
Patients who have had a previous thromboembolic event
Young patients who require amiodarone or warfarin
Patients who require other cardiac operation that can be performed in conjunction with the Maze procedure

variant of hypertrophic cardiomyopathy,<sup>36</sup> was discharged postoperatively but died later of hyperkalemia from antibiotic-induced acute renal failure. The other patients have resumed employment, except for the most recent two patients (less than 3 months after surgery). None of the patients was on antiarrhythmic medications after the Maze surgery. One patient had a brief course of warfarin because of thrombus on a permanent pacemaker wire.

In our patients, postoperative morbidity includes two patients requiring DDD-R pacemaker implantation for sick sinus syndrome (noted preoperatively). Three patients had peripheral edema and fluid retention, postulated by Cox to be from low atrial natriuretic factor,<sup>34</sup> and they required diuretics for up to 3 months. Three patients (including the illustrated case) had perioperative AF, which was treated with an antiarrhythmic for 6 to 12 weeks; treatment was then stopped without recurrence of the arrhythmia.

Indications for the Maze procedure are still being defined. Potential candidates are similar to those undergoing AV junction ablation for AF (Table). These are typically either patients with frequent severe symptoms despite appropriate medications, or patients with unacceptable side effects from medication. Young patients on chronic amiodarone or warfarin should be considered candidates because of the long-term risk of these medications.

Patients with previous thromboembolic events are candidates because of the high risk of subsequent events, which AV junction ablation will not decrease. The patient with Yamaguchi's disease and another patient with lone AF (who had previously undergone AV node ablation with pacemaker insertion) had a history of stroke. The second patient (on warfarin preoperatively) was found at surgery to have a 1-cm left atrial thrombus.

The Maze procedure can be performed in conjunction with other cardiac operations: two patients had coronary artery bypass grafting, and one patient had

mitral valve repair, all with a simultaneous Maze procedure.<sup>37</sup> As experience grows, the Maze procedure will increasingly be added as a "secondary" goal with concomitant cardiac surgery.

In conclusion, patients with incapacitating AF can now be treated successfully with this new surgical operation, which restores sinus rhythm and atrial systole. It greatly reduces the risk of thromboembolism, improves hemodynamics, and alleviates palpitations. Antiarrhythmic and anticoagulant medications can be discontinued. For selected patients with AF, this operation has advantages over AV junction ablation.

#### REFERENCES

1. Kannel WB, Abbott RD, Savage DD, McNamara PM. Epidemiologic features of chronic atrial fibrillation: the Framingham Study. *N Engl J Med* 1982; 306:1018-22.
2. Kopecky SL, Gersh BJ, McGoon MD, et al. The natural history of lone atrial fibrillation: a population-based study over three decades. *N Engl J Med* 1987; 317:669-74.
3. Borsky MA, Allen BJ, Capparelli EV, Luckett CR, Morton R, Henry WL. Factors determining maintenance of sinus rhythm after chronic atrial fibrillation with left atrial dilatation. *Am J Cardiol* 1989; 63:1065-8.
4. Sodermark T, Jonsson B, Olsson A, et al. Effect of quinidine on maintaining sinus rhythm after conversion of atrial fibrillation or flutter: a multicenter study from Stockholm. *Br Heart J* 1975; 37:486-92.
5. Flaker GC, Wright WP, Alpert MA. Atrial fibrillation: new ideas on an old arrhythmia. *Cardiovasc Rev Rep* 1990; 11:23-9.
6. Antman EM, Beamer AD, Cantillon C, McGowan N, Friedman PL. Therapy of refractory symptomatic atrial fibrillation and atrial flutter: a staged care approach with new antiarrhythmic drugs. *J Am Coll Cardiol* 1990; 15:698-707.
7. Horowitz LN, Spielman SR, Greenspan AM, et al. Use of amiodarone in the treatment of persistent and paroxysmal atrial fibrillation resistant to quinidine therapy. *J Am Coll Cardiol* 1985; 6:1402-7.
8. Wolf PA, Dawber TR, Thomas HE, Kannel WB. Epidemiologic assessment of chronic atrial fibrillation and risk of stroke: the Framingham study. *Neurology* 1978; 28:973-7.
9. Wolf PA, Kannel WB, McGee DL, Meeks SL, Bharucha NE, McNamara PM. Duration of atrial fibrillation and imminence of stroke: the Framingham study. *Stroke* 1983; 14:664-7.
10. Britton M, Gustafsson C. Non-rheumatic atrial fibrillation as a risk factor for stroke. *Stroke* 1985; 16:182-8.
11. Petersen P, Godtfredsen J. Embolic complications in paroxysmal atrial fibrillation. *Stroke* 1986; 17:622-6.
12. Peterson P. Thromboembolic complications of atrial fibrillation and their prevention: a review. *Am J Cardiol* 1990; 65:24C-28C.
13. Mitchell JH, Gupta DN, Payne RM. Influence of atrial systole on effective ventricular stroke volume. *Circ Res* 1965; 17:11-8.
14. Glancy DL, O'Brien KP, Gold HK, Epstein SE. Atrial fibrillation in patients with idiopathic hypertrophic subaortic stenosis. *Br Heart J* 1970; 32:652-9.
15. Khaja F, Parker JO. Hemodynamic effects of cardioversion in chronic atrial fibrillation: special reference to coronary artery disease. *Arch Intern Med* 1972; 129:433-40.
16. Mukharji J, Rehr RB, Hastillo A, et al. Comparison of atrial contribution to cardiac hemodynamics in patients with normal and severely compromised cardiac function. *Clin Cardiol* 1990; 13:639-43.



17. Falk RH. Flecainide-induced ventricular tachycardia and fibrillation in patients treated for atrial fibrillation. *Ann Intern Med* 1989; **111**:107-11.
18. Cox JL, Schuessler RB, Boineau JP. The surgical treatment of atrial fibrillation. I. Summary of the current concepts of the mechanisms of atrial flutter and atrial fibrillation. *J Thorac Cardiovasc Surg* 1991; **101**:402-5.
19. Cox JL, Canavan TE, Schuessler RB, et al. The surgical treatment of atrial fibrillation. II. Intraoperative electrophysiologic mapping and description of the electrophysiologic basis of atrial flutter and atrial fibrillation. *J Thorac Cardiovasc Surg* 1991; **101**:406-26.
20. Cox JL, Schuessler RB, D'Agostino HJ, et al. The surgical treatment of atrial fibrillation. III. Development of a definitive surgical procedure. *J Thorac Cardiovasc Surg* 1991; **101**:569-83.
21. Cox JL. The surgical treatment of atrial fibrillation. IV. Surgical technique. *J Thorac Cardiovasc Surg* 1991; **101**:584-92.
22. Gallagher JJ, Svenson RH, Kasell JH, et al. Catheter technique for closed-chest ablation of the atrioventricular conduction system. *N Engl J Med* 1982; **306**:194-200.
23. Rosenqvist M, Lee MA, Moulinier L, et al. Long-term follow-up of patients after transcatheter direct current ablation of the atrioventricular junction. *J Am Coll Cardiol* 1990; **16**:1467-4.
24. Morady F, Calkins H, Langberg JJ, El-Atassi R. A prospective randomized comparison of direct-current shocks vs. radiofrequency energy for catheter ablation of the atrioventricular junction. *J Am Coll Cardiol* 1992; **(19)**3:183A.
25. Scheinman MM. Catheter ablation. Present role and projected impact on health care for patients with cardiac arrhythmias. *Circulation* 1991; **83**:1489-98.
26. Petersen P, Boysen G, Godtfredsen J, Andersen ED, Andersen B. Placebo-controlled, randomised trial of warfarin and aspirin for prevention of thromboembolic complications in chronic atrial fibrillation: The Copenhagen AFASAK study. *Lancet* 1989; **1**:175-9.
27. Stroke Prevention in Atrial Fibrillation Study Group Investigators: Preliminary report of the Stroke Prevention in Atrial Fibrillation Study. *N Engl J Med* 1990; **322**:863-8.
28. Boston Area Anticoagulation Trial in Atrial Fibrillation Investigators: The effect of low dose warfarin on the risk of stroke in patients with nonrheumatic atrial fibrillation. *N Engl J Med* 1990; **323**:1505-11.
29. Williams JM, Ungerleider RM, Lofland GK, Cox JL. Left atrial isolation: a new technique for the treatment of supraventricular arrhythmias. *J Thorac Cardiovasc Surg* 1980; **80**:373-80.
30. Cox JL, Boineau JP, Schuessler RB, et al. Operations for atrial fibrillation. *Clin Cardiol* 1991; **14**:827-34.
31. Leitch JW, Klein G, Yee R, Guiraudon G. Sinus node-atrioventricular node isolation: long-term results with the "corridor" operation for atrial fibrillation. *J Am Coll Cardiol* 1991; **17**:970-5.
32. Defauw JJ, Guiraudon GM, van Hemel NM, et al. Surgical therapy of paroxysmal atrial fibrillation with the "corridor" operation. *Ann Thorac Surg* 1992; **53**:564-71.
33. DiMarco JP. Surgical therapy for atrial fibrillation: a first step on what may be a long road. *J Am Coll Cardiol* 1991; **17**:976-7.
34. Cox JL, Boineau JP, Schuessler RB, et al. Successful surgical treatment of atrial fibrillation. Review and clinical update. *JAMA* 1991; **266**(14):1976-1980.
35. McCarthy PM, Castle L, Ghandour M, et al. Initial experience with the Maze procedure. *J Thorac Cardiovasc Surg* 1993 (in press).
36. Yamaguchi H, Ishimura T, Nishiyama S, et al. Hypertrophic non-obstructive cardiomyopathy with giant negative T waves (apical hypertrophy): ventriculographic and echocardiographic features in 30 patients. *Am J Cardiol* 1979; **44**(3):401-412.
37. McCarthy PM, Cosgrove DM, Castle LW, White RD, Klein AL. Combined treatment of mitral regurgitation and atrial fibrillation with valvuloplasty and the Maze Procedure. *Am J Cardiol* 1993 (in press).

