

Internal Medicine Board Review

IN THIS ISSUE OF the *Journal*, we initiate a new feature, "Internal Medicine Board Review." This feature will present clinical vignettes together with questions focusing on salient aspects of differential diagnosis and treatment of problems likely to be encountered on the Qualifying Examination in Medicine, as well as in practice. We hope our readers will find it a worthwhile exercise.

DAVID L. LONGWORTH, MD
AND JAMES K. STOLLER, MD
SECTION EDITORS

Q A 43-YEAR-OLD WOMAN PRESENTS TO YOUR office with a 2-week history of anorexia, night sweats, dry cough, and left anterior pleuritic chest pain. Six months prior to admission, she developed bilateral leg pain and numbness. Over the next 3 months, her symptoms progressed, and she lost 20 pounds. Liver function studies were elevated, and the hepatitis B surface antigen test was positive. A sural nerve biopsy and muscle biopsy demonstrated vasculitis and a diagnosis of polyarteritis nodosa was made. Two months ago, she began treatment with prednisone 60 mg po qd and cyclophosphamide 100 mg po qd, which she has continued to the present.

On physical examination, she appears thin and chronically ill. Her temperature is 38.5° C, blood pressure 142/104, heart rate 104, and respirations 16 and unlabored. Oral thrush and a right foot drop are noted on examination. The chest is clear.

The white blood cell count is 5,600 with 96% granulocytes, 2% lymphocytes, and 2% monocytes. Chest radiography is performed (Figure 1).

A. Which of the following represents the least likely diagnosis?

- ☐ Cryptococcosis
- ☐ Tuberculosis

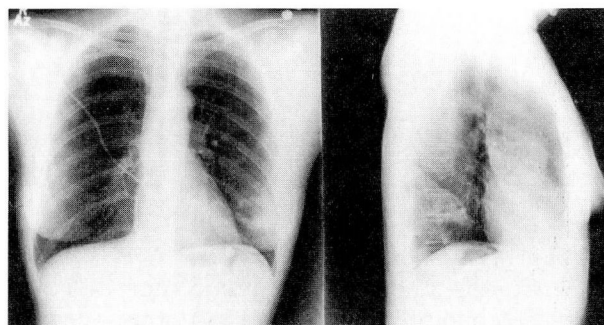


FIGURE 1.

- ☐ Nocardiosis
- ☐ *Pneumocystis carinii* infection

B. Bronchoscopy and transbronchial lung biopsy are performed. For each potential pathologic finding depicted in Figure 2, choose the appropriate therapy:

- ☐ Amphotericin B
- ☐ Isoniazid plus rifampin
- ☐ Erythromycin
- ☐ Trimethoprim-sulfamethoxazole
- ☐ Oxacillin
- ☐ Amphotericin B plus flucytosine

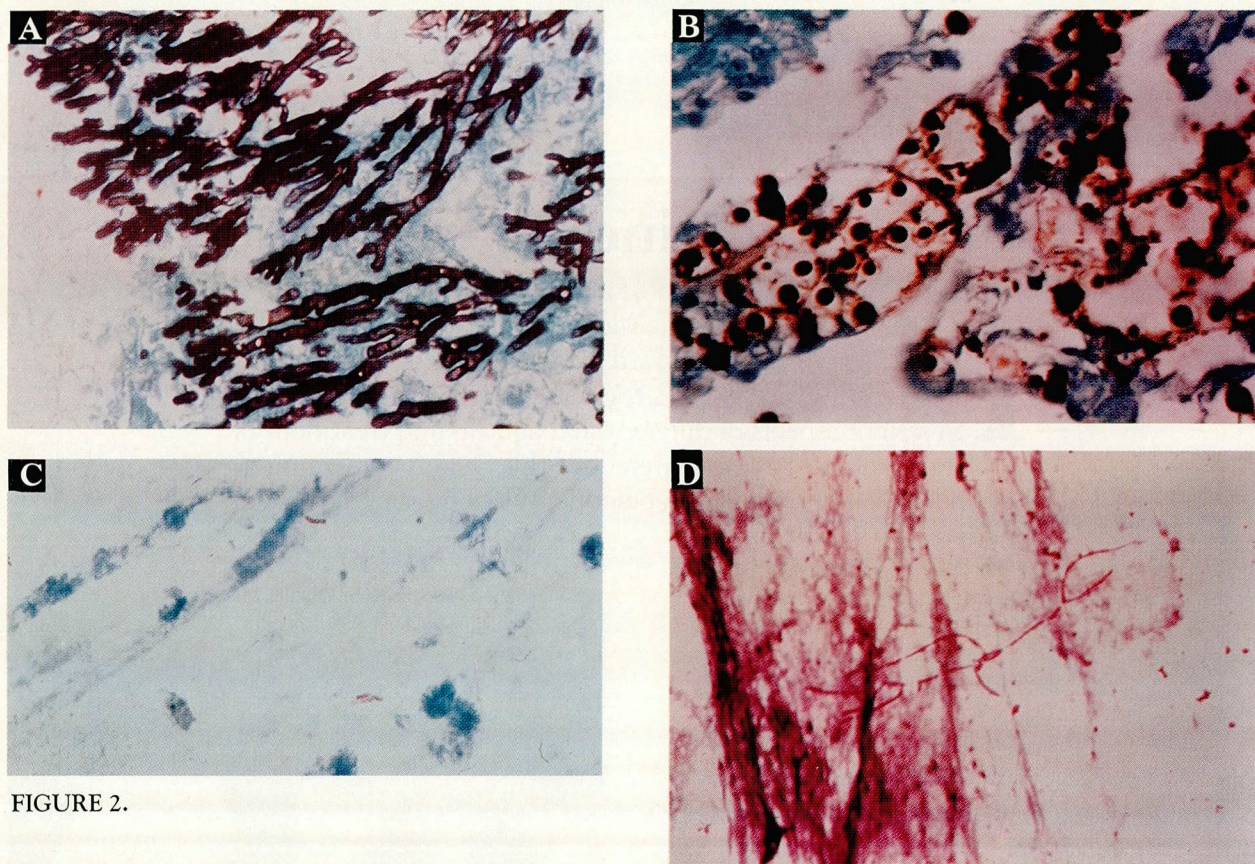


FIGURE 2.

Discussion

A THIS 43-YEAR-OLD WOMAN WITH POLYarteritis nodosa is immunocompromised by virtue of her prednisone and cyclophosphamide therapy. She presents with a subacute respiratory illness and a left lower lobe cavitary infiltrate. Of the possibilities in question A, *P carinii* pneumonia is the least likely diagnosis. Tuberculosis, nocardiosis, and cryptococcosis would all be serious considerations in such a patient. Although *P carinii* pneumonia can rarely present with small cavities, the typical radiographic pattern is that of a patchy or diffuse interstitial infiltrate.

Transbronchial lung biopsy might conceivably show one of several pathogens, depicted in Figure 2, which could produce a cavity. Figure 2A shows typical branching septated hyphae of *Aspergillus* species, for which amphotericin B would be appropriate therapy. *Cryptococcus neoformans* is depicted in Figure 2B, which demonstrates typical yeast forms. The combination of amphotericin B and flucytosine is

preferred by most authorities. Fluconazole might be considered as alternative therapy, but it is not offered as a potential answer in this question. Data regarding the utility of fluconazole for pulmonary cryptococcosis in patients who do not have the acquired immunodeficiency syndrome are limited. Typical acid-fast bacilli of *Mycobacterium tuberculosis* are shown in Figure 2C, for which isoniazid and rifampin would be the appropriate choice. The weakly acid-fast branching filamentous bacilli shown in Figure 2D are typical of *Nocardia asteroides*, which was the ultimate diagnosis in our patient. Trimethoprim-sulfamethoxazole represents the best answer offered. Some authorities would add other agents such as imipenem or amikacin in immunocompromised patients.

DAVID L. LONGWORTH, MD
Department of Infectious Disease
The Cleveland Clinic Foundation