



# Stereotactically guided thrombolysis of deep cerebral hemorrhage: preliminary results

DAVID W. MILLER, MD; GENE H. BARNETT, MD; DONALD W. KORMOS, PhD; CHARLES P. STEINER, BS

- **BACKGROUND** The neurologic outcome from conventional medical or surgical therapy of intracerebral hemorrhage (ICH) is poor; however, stereotactically guided instillation of thrombolytic agents to dissolve parenchymal clots due to hypertensive hemorrhage has recently produced results equal to or better than those obtained with conventional therapies.
- **OBJECTIVE** To determine whether stereotactic thrombolysis of deep ICH is safe and effective.
- **METHODS** We administered urokinase to clots in four patients with hypertensive ICH. After the hemorrhage was localized using angiography and computed tomography-assisted stereotactic technique, a ventricular catheter was used to administer urokinase to the clot.
- **RESULTS** Preliminary results showed dramatic reduction in clot volume within 48 hours of initiating treatment and modest clinical improvement in all four patients. No further hemorrhages were seen after treatment. Three patients ultimately died of non-neurologic causes.
- **CONCLUSIONS** With careful patient selection, stereotaxy-assisted thrombolytic therapy may be an advance in the treatment of certain cases of ICH.

■ **INDEX TERMS:** CEREBRAL HEMORRHAGE; STEREOTAXIC TECHNIQUES; UROKINASE; THROMBOLYTIC THERAPY ■ *CLEVE CLIN J MED* 1993; 60:321-324

From the Department of Neurological Surgery, The Cleveland Clinic Foundation.

Address reprint requests to G.H.B., Department of Neurological Surgery, S80, The Cleveland Clinic Foundation, 9500 Euclid Avenue, Cleveland, OH 44195.

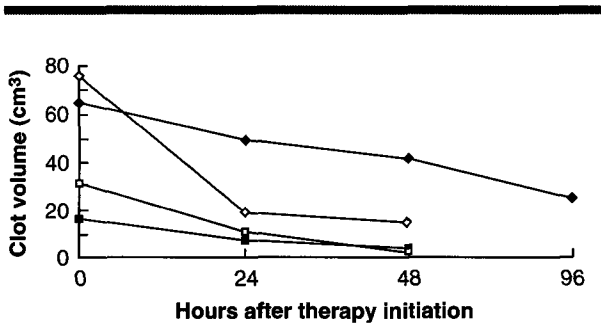
**D**ESPITE THE IMPROVEMENTS in diagnosis offered by computed tomographic (CT) imaging, the mortality and morbidity associated with intracerebral hemorrhage (ICH) remain distressingly high.<sup>1-8</sup>

Efforts to improve outcome by using image-guided stereotactic techniques to evacuate intracerebral clots date to the mid-1960s.<sup>9</sup> Such methods included simple aspiration,<sup>10</sup> devices employing the principle of Archimedes' screw,<sup>3,9</sup> and fibrinolysis.<sup>11</sup> Although the instillation of fibrinolytic agents into a fresh hematoma would intuitively seem hazardous, several reports have shown clinical outcome of this approach to be as good as or better than medical or other surgical series, with the risk of rehemorrhage no greater than after conventional management.<sup>11-13</sup> We report our experience using a ventricular catheter to administer urokinase to clots in four patients with hypertensive ICH.

**TABLE**  
STEREOTACTICALLY GUIDED THROMBOLYSIS OF DEEP CEREBRAL HEMORRHAGE:  
PATIENT CHARACTERISTICS AND OUTCOME

Age/sex	Presenting characteristics				Follow-up					
	Predisposing factors	Clot volume (cm <sup>3</sup> )	Site	Deficit	Initial GCS*	Best GCS	Clot reduction	Length of treatment (days)	Length of follow-up	Outcome
68/M	Hypertension	31.6	Right thalamus	Hemiplegia, obtundation	4	11	93.7%	4	1 month	Improved, then expired from pneumonia
67/F	Hypertension	16.1	Left thalamus	Hemiplegia, aphasia	8	15	79.5%	2	6 months	Improved
79/F	Hypertension	65	Left basal ganglia	Hemiplegia, obtundation, aphasia	4	6	81.0%	2	2 days	Improved, then expired after myocardial infarction
66/F	Hypertension, anticoagulated status	75.4	Right thalamus	Hemiplegia, obtundation	7	15	93.4%	8	2 months	Improved, then expired after myocardial infarction

\*GCS, Glasgow coma scale



**FIGURE 1.** Reduction of clot volume in four patients after instituting stereotactic thrombolytic therapy.

## PATIENTS AND METHODS

### Patient selection

Adults with recent ICH (< 96 hours) and static or progressive neurologic deficit were candidates for treatment. However, patients were included only if the hemorrhage etiology was hypertension, amyloid, or iatrogenic (ie, following thrombolytic therapy). Patients were excluded if the hemorrhage was shown to be due to vascular malformation or aneurysm (identified by angiography) or tumor (as identified on clinical and radiographic grounds).

### Operative technique

After angiography, a Brown-Roberts-Wells stereotactic headring (Radionics, Inc, Burlington, MA) and CT localization frame were applied. CT images were obtained encompassing the entire hemorrhage (5-mm slice/5-mm interval). These images were used to target the clot; they also allowed measurement of clot volume using customized volume measurement software. Stereotactic guidance was provided by a Cosman-Roberts-Wells arc (Radionics, Inc, Burlington, MA). After creating a hole with a twist drill, a 2-mm Silastic catheter (Codman & Shurtleff, Inc, Randolph, MA) was advanced into the hematoma using conventional stereotactic techniques. The clot was aspirated maximally, then 5000 U urokinase (1 mL) was instilled, followed by a 2-mL 0.9% sodium chloride flush. The catheter was then clamped. The patient was monitored in the neurosurgical intensive care unit, and the clot was aspirated and urokinase instilled every 5 to 6 hours. CT images were obtained twice daily.

### Endpoints

Clot aspiration was discontinued when maximal benefit was derived from the procedure, as determined by (1) resolution of the clot on CT images, (2) a cumulative aspirated clot volume (excluding

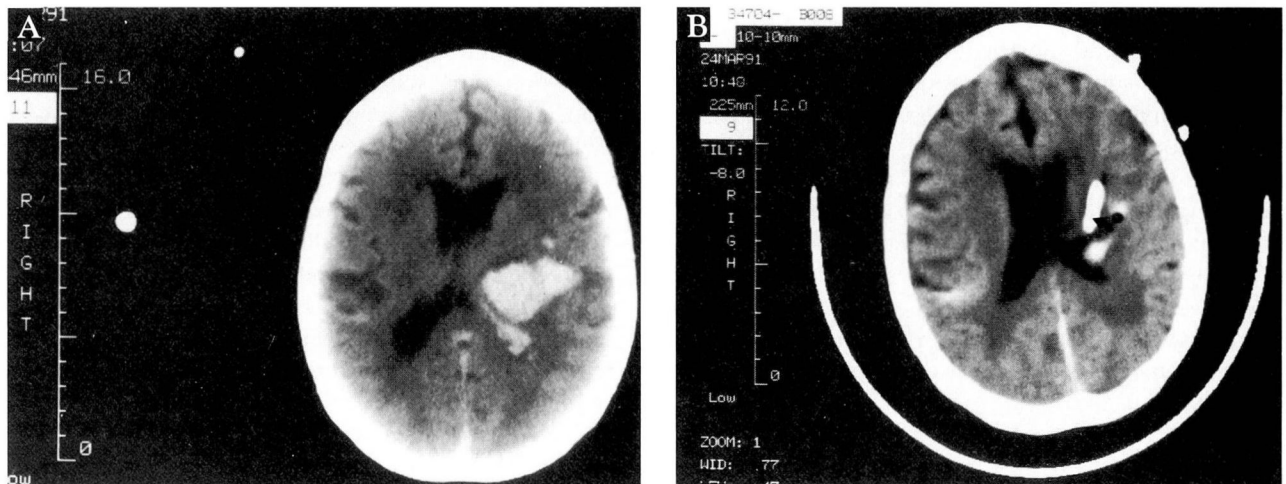


FIGURE 2. Unenhanced computed tomographic scan of left thalamic hemorrhage (A) in a 67-year-old hypertensive woman with global aphasia and right hemiplegia. After urokinase treatment (B), the clot volume is substantially reduced. The catheter tip is clearly seen (arrow). The patient was discharged to rehabilitation 3 weeks after treatment, at which time she could move her right lower limb, verbalize, and follow simple instructions.

urokinase) equal to 90% of calculated clot volume, or (3) recovery from neurologic deficit. Additional indications for discontinuation of treatment were clinical deterioration, rehemorrhage, or death.

#### RESULTS

Four patients were treated with intracloset urokinase. Their mean age was 70, with a range of 66 to 79 (Table). The site of hemorrhage was the basal ganglia (one patient) or thalamus (three patients). The mean Glasgow coma scale score<sup>14</sup> on admission was 6. The initial clot volume (mean  $\pm$  SEM) was  $47.0 \text{ cc}^3 \pm 13.9 \text{ cc}^3$  (range 16.1 to 75.4).

The Glasgow coma scale score rose an average of 6 points (range 2 to 8) after treatment (Table). Clot volume was reduced by  $59.4\% \pm 11.0\%$  after 24 hours of treatment and by  $72.7\% \pm 12.4\%$  after 48 hours of treatment (Figure 1). Maximum clot reduction during therapy was  $86.9\% \pm 3.8\%$ . No rehemorrhage was seen after therapy was started. Representative CT images obtained before and after therapy are presented in Figure 2. Three patients died of cardiopulmonary problems 2, 29, and 61 days after initiating treatment.

#### DISCUSSION

Definitive treatment of ICH remains a controversial topic. A number of authors have advo-

cated a surgical approach to treatment, but more recent studies support a trend toward "conservative" medical management of thalamic, putaminal and caudate hemorrhages. The lone exception to this approach may be when hematomas can be operated upon very early in their development (ie, within 7 hours of presentation).<sup>2,11</sup>

The advent of highly precise stereotactic methods in the treatment of brain disorders has raised enthusiasm regarding their use in the treatment of ICH. Early efforts aimed at simple clot aspiration as well as more ingenious means of mechanical evacuation<sup>3,9</sup> have placed the focus of early intervention on reducing hematoma volume; however, difficulties in obtaining significant reduction of the clot using these methods have led some investigators to use fibrinolytic agents as a means of enhancing clot evacuation.

Fibrinolytic agents (specifically, urokinase) substantially reduce clots, and the incidence of rehemorrhage or other associated morbidity is no higher when thrombolytic agents are used to treat ICH than when they are not used.<sup>11-13</sup> Moreover, animal models of ICH treated with urokinase have demonstrated no evidence of additional damage at the cellular level attributable to this agent.<sup>15-17</sup> Theoretically, tissue-type plasminogen activator may be more specific and rapid in its action than urokinase, but little evidence supports its safe use in brain tissue. Moreover, its cost remains prohibitive.

Direct stereotactic administration of urokinase into intracerebral clot beds appears to be safe and effective in substantially reducing the size of the clot. The mean reduction of clot volume within the first 48 hours of therapy (> 70%) was achieved with no more (and likely less) neurologic morbidity than is associated with conventional surgical evacuation of basal ganglia and diencephalic ICH. These data are consistent with some previous observations that the clinical status of the patient at presentation, the size of the hematoma, and the presence of intraventricular clot primarily govern the outcome, irrespective of treatment modality.<sup>7,18-20</sup>

The rationale for performing stereotactic thrombolytic therapy of ICH is that reducing clot volume by a substantial amount and removing potentially neurotoxic breakdown products of the hematoma should accelerate clinical recovery and lead to a better clinical outcome. In our patients, early intervention often led to considerable improvement in clinical neurologic status based on resolution of deficits and Glasgow coma scale score. Unfortunately, three of the four patients ultimately died from non-neurologic causes. Each of the patients who died

initially presented with obtundation, which is perhaps an ominous prognostic indicator, leading to excessive cardiovascular stress and protracted intubation. The lone survivor, at presentation, not only was awake, but also had the smallest hematoma.

To our knowledge, this is the first North American report of this technique's use for dissolving hematomas secondary to ICH. While the number of patients is small, these preliminary results support Matsumoto's findings that the volume of the hematoma in ICH can be safely and dramatically reduced without resorting to open surgical evacuation. The high observed mortality from non-neurologic causes underscores the importance of expanding this study to define which patients may reap long-term benefit from the procedure. It also directs attention to the need for intensive cardiopulmonary support in the period after hemorrhage.

#### ACKNOWLEDGMENT

The authors wish to thank the Cleveland Clinic Division of Radiology for its assistance in obtaining neuroimaging for these cases.

#### REFERENCES

1. Auer LM, Auer T, Sayama I. Indications for surgical treatment of cerebellar haemorrhage and infarction. *Acta Neurochir (Wien)* 1986; 79:74-79.
2. Juvela S, Heiskanen O, Poranen A, Valtonen S, Kuurne T, Kaste M. The treatment of spontaneous intracerebral hemorrhage: a prospective randomized trial of surgical and conservative treatment. *J Neurosurg* 1989; 70:755-758.
3. Kandel EI, Peresedov VV. Stereotaxic evacuation of spontaneous intracerebral hematomas. *J Neurosurg* 1985; 62:206-213.
4. Kanno T, Sano H, Shinomiya Y, Katada K, Nagata J, Hoshino M. Role of surgery in hypertensive intracerebral hematoma. A comparative study of 305 nonsurgical and 154 surgical cases. *J Neurosurg* 1984; 61:1091-1099.
5. McKissock W, Richardson A, Taylor J. Primary intracerebral haemorrhage. A controlled trial of surgical and conservative treatment in 180 unselected cases. *Lancet* 1961; 2:221-226.
6. Taneda M, Hayakawa T, Mogami H. Primary cerebellar hemorrhage. Quadrigeminal cistern obliteration on CT scans as a predictor of outcome. *J Neurosurg* 1987; 67:545-552.
7. Waga S, Miyazaki M, Okada M, Tochio H, Matsushima S, Tanaka Y. Hypertensive putaminal hemorrhage: analysis of 182 patients. *Surg Neurol* 1986; 26:159-166.
8. Waga S, Yamamoto Y. Hypertensive putaminal hemorrhage: treatment and results. Is surgical treatment superior to conservative one? *Stroke* 1983; 14:480-485.
9. Backlund EO, von Holst H. Controlled subtotal evacuation of intracerebral haematomas by stereotactic technique. *Surg Neurol* 1978; 9:99-101.
10. Benes V, Vladyka V, Zverina E. Stereotactic evacuation of typical brain hemorrhage. *Acta Neurochir (Wien)* 1965; 13:419-426.
11. Matsumoto K, Hondo H. CT-guided stereotaxic evacuation of hypertensive intracerebral hematoma. *J Neurosurg* 1984; 61:440-448.
12. Doi E, Moriwaki H, Komai N. Stereotaxic operation for hypertensive intracerebral hemorrhage—especially for thalamic hemorrhage. *Neurol Med Chir (Tokyo)* 1980; 20 (Suppl):124-125.
13. Mohadjer M, Eggert R, May J, Mayfrank L. CT-guided stereotactic fibrinolysis of spontaneous and hypertensive cerebellar hemorrhage: long-term results. *J Neurosurg* 1990; 73:217-222.
14. Jennett B, Bond M. Assessment of outcome after severe brain damage. A practical scale. *Lancet* 1975; 1:480-484.
15. Findlay JM, Weir BKA. Effect of intrathecal thrombolytic therapy on subarachnoid clot and chronic vasospasm in a primate model of SAH. *J Neurosurg* 1988; 69:723-735.
16. Julow L. Prevention of subarachnoid fibrosis after subarachnoid hemorrhage with urokinase. Scanning electron microscopic study in the dog. *Acta Neurochir (Wien)* 1979; 51:53-61.
17. Narayan RK, Narayan TM, Katz DA, Kornblith PL, Murano G. Lysis of intracranial hematomas with urokinase in a rabbit model. *J Neurosurg* 1985; 62:580-586.
18. Helweg-Larsen S, Sommer W, Strange P, Lester J, Boysen G. Prognosis for patients treated conservatively for spontaneous intracerebral hematomas. *Stroke* 1984; 15:1045-1048.
19. Nath FP, Nicholls D, Fraser RJ. Prognosis in intracerebral haemorrhage. *Acta Neurochir (Wien)* 1983; 67:29-35.
20. Portenoy RK, Lipton RB, Berger AR, Lesser ML, Lantos G. Intracerebral haemorrhage: a model for the prediction of outcome. *J Neurol Neurosurg Psychiatry* 1987; 50:976-979.