

# Hemopericardium and cardiac tamponade associated with warfarin therapy

KAMTHORN S. LEE, MD, AND THOMAS MARWICK, MD

- We report the case of a 67-year-old man with vertebral-basilar arterial insufficiency who had been receiving warfarin therapy for approximately 2 years. The patient presented with a 3-week history of weight gain, abdominal distension, and mild exertional dyspnea. Transthoracic echocardiography confirmed the presence of a large circumferential pericardial effusion with diastolic collapse of the right atrium, and a pulsed-wave Doppler echocardiographic study of mitral and tricuspid diastolic flow showed respiratory variation consistent with cardiac tamponade. The patient's prothrombin time was 30 seconds, which decreased to 17 seconds after treatment with intravenous fresh-frozen plasma and vitamin K. He underwent drainage of 2 L of bloody pericardial fluid over 12 hours by pericardiocentesis. Extensive further studies failed to demonstrate known causes or correlates of pericardial effusion. The patient was discharged and continued to do well without warfarin therapy.

■ INDEX TERMS: WARFARIN; PERICARDIAL EFFUSION; CARDIAC TAMPONADE  
■ CLEVE CLIN J MED 1993; 60:336-338

From the Department of Cardiology, The Cleveland Clinic Foundation.

Address reprint requests to K.S.L., Department of Cardiology, F15, The Cleveland Clinic Foundation, 9500 Euclid Avenue, Cleveland, OH 44195.

**T**HE ASSOCIATION of warfarin therapy with hemorrhagic complications is well known.<sup>1</sup> The sites of bleeding are usually confined to wounds and the gastrointestinal and genitourinary tracts. We report a case illustrating a rare complication of warfarin therapy—hemopericardium with resultant cardiac tamponade.

## CASE HISTORY

A 67-year-old man presented with a 3-week history of weight gain, abdominal distension, and mild exertional dyspnea. He had vertebral-basilar arterial insufficiency documented angiographically 2 years previously. Due to persistent neurologic symptoms with aspirin therapy, he had been prescribed warfarin, which resulted in cessation of his symptoms. Monthly laboratory monitoring demonstrated excellent anticoagulation, with a prothrombin time in the therapeutic range (18 to 20 seconds).

On examination his blood pressure was 190/100 mm Hg, with a pulsus paradoxus of 15 mm Hg. Jugular venous distension was

noted at 12 cm above the right atrium. The remaining physical examination demonstrated ascites, hepatomegaly, edema, and diminution of heart sounds. Electrocardiography showed low voltages. Chest roentgenography demonstrated cardiomegaly, and transthoracic echocardiography confirmed the presence of a large circumferential pericardial effusion with diastolic collapse of the right atrium (Figure). A pulsed-wave Doppler study of mitral and tricuspid diastolic flow showed respiratory variation consistent with cardiac tamponade.

On admission, the patient's prothrombin time was 30 seconds, which decreased to 17 seconds after treatment with intravenous fresh-frozen plasma and vitamin K. Pericardiocentesis performed under echocardiographic guidance drained 1 L of bloody pericardial fluid immediately. An additional 1 L of pericardial fluid was drained over the next 12 hours. Echocardiography performed after pericardiocentesis confirmed a marked reduction of the pericardial effusion. The right atrium was reexpanded. The pericardial fluid had a hematocrit of 19% (the peripheral blood hematocrit was 36%). Gram's stain, acid-fast bacillus stain, and bacterial culture of the pericardial fluid revealed no bacterial pathogens. Results of cytologic examination of the pericardial fluid were normal.

Additional studies, including determination of thyroid function, erythrocyte sedimentation rate, antinuclear antibody titer, serum rheumatoid factor concentration, and liver function, failed to demonstrate known causes or correlates of pericardial effusion. Serum titers to adenovirus, enterovirus, and echovirus were 1:8 both on admission and after 8 weeks, indicating that a viral infection was probably not the cause of this illness.

After serial echocardiography failed to demonstrate further accumulation of pericardial fluid, the patient was discharged from the hospital

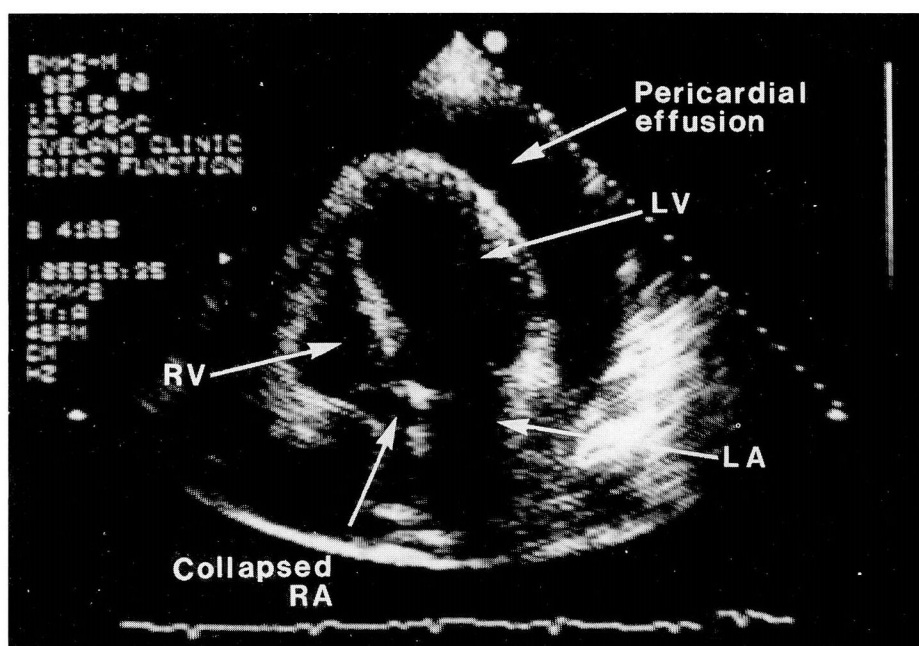


FIGURE. Apical four-chamber view of the heart showing a large pericardial effusion and diastolic collapse of the right atrium consistent with cardiac tamponade.

with normal coagulation parameters. He continued to do well clinically without warfarin therapy, and an outpatient echocardiogram confirmed that the pericardial effusion has not recurred.

#### DISCUSSION

Hemopericardium commonly occurs in the setting of trauma or inflammatory reactions. In the nontraumatic setting, hemorrhagic pericardial effusions are associated with malignancy, myocardial infarction, dissection of the aorta, and postmyocardial infarction syndrome.<sup>1</sup> In our patient, however, the history and laboratory studies pointed to none of these etiologies. In an elderly patient, such pericardial effusions are often thought to be associated with malignancy, but this case illustrates an exception.

Previous cases of "spontaneous hemopericardium" during anticoagulant therapy have been reported.<sup>1-3</sup> However, at the time of their writing, meticulous testing with viral titers, viral cultures, and rheumatologic antibody assays was not available to fully exclude other etiologies. In our patient, an extensive search for a precipitating cause was performed with serum hormone levels, viral titers and culture, bacterial culture, autoimmune antibody titers, and cytologic studies. A detailed his-

tory and physical examination also failed to reveal any cause of hemopericardium. Based on these exclusions, we believe that in this patient the occurrence of hemopericardium was associated with the use of anticoagulant therapy.

The treatment of hemopericardium involves the control of hemodynamic abnormalities and the reversal of anticoagulation. Pericardiocentesis, in draining the pericardial effusion, lowers intrapericardial pressure. This allows normalization of venous return and, hence, the proper filling of the heart in diastole.

Correction of anticoagulation can be achieved in several ways. Warfarin competitively inhibits the effects of vitamin K in the posttranslational gamma-carboxylation of vitamin K-dependent plasma proteins. An immediate but temporary decrease in prothrombin time can be achieved with use of fresh-frozen plasma, which is a source of vitamin K-dependent plasma proteins. Intravenous vitamin K infusion should correct prothrombin time in 4 to 6 hours.<sup>4</sup> The questions of whether to restart anticoagulant therapy and how long to wait before doing so are difficult clinical decisions and clearly

should be individualized. We feel that, because our patient has been clinically stable since his last neurologic event, the occurrence of spontaneous hemopericardium constitutes a contraindication to anticoagulation therapy.

Although the most common sites of bleeding from oral anticoagulants are from the gastrointestinal and genitourinary tracts,<sup>5</sup> the diagnosis of hemopericardium should be considered in patients developing signs and symptoms of right-sided heart failure while receiving anticoagulant therapy.

#### REFERENCES

1. Miller RL. Hemopericardium with use of oral anticoagulant therapy. *JAMA* 1967; **209**:1362-1363.
2. Fell SC, Rubin IL, Engelberg CD, et al. Anticoagulant-induced hemopericardium with tamponade. *N Engl J Med* 1965; **272**:670-674.
3. Granot H, Shinar E. Spontaneous anticoagulant-induced hemopericardium with tamponade. *Acta Haematol* 1982; **68**:339-340.
4. Mosher DE. Disorders of blood coagulation. In: Wyngaarden JB, Smith LH Jr, editors. *Cecil textbook of medicine*, 18th edition. Philadelphia, W.B. Saunders Co., 1988:1060-1081.
5. Coon W, Willis P. Hemorrhagic complications of anticoagulant therapy. *Arch Intern Med* 1974; **133**:386-392.

