



Stereotactic and computer-assisted neurosurgery at the Cleveland Clinic: review of 501 consecutive cases

HELDO GOMEZ, MD; GENE H. BARNETT, MD; MELINDA L. ESTES, MD; JOANN PALMER, RN; MELLISSA MAGDINEC, RN

- **BACKGROUND** Stereotactic and computer-assisted techniques have revolutionized the diagnosis and treatment of many disorders of the brain by directing surgical instruments, the surgeon's hands, or focused radiation to an imaged target along predefined routes.
- **METHODS** This report reviews the basic principles and techniques of stereotactic and computer-assisted procedures in 501 consecutive procedures.
- **RESULTS** Procedures performed include biopsy; decompression of cysts, hematomas, ventricles, and abscesses; "point," computer-assisted volumetric, and frameless stereotactic resection of brain lesions; placement of depth electrodes; treatment of movement or pain disorders; implantation of radioactive seeds in malignant tumors; and radiosurgery.
- **CONCLUSIONS** Overall, image-directed stereotactic neurosurgery proved safe, accurate, and versatile.

■ **INDEX TERMS:** STEREOTAXIC TECHNIQUES; IMAGE PROCESSING, COMPUTER-DIRECTED; NEUROSURGERY; BRAIN NEOPLASMS ■ CLEVE CLIN J MED 1993; 60:399-410

From the Center for Computer-Assisted Neurosurgery and the Department of Neurosurgery (H.G., G.H.B., J.P., M.M.) and the Department of Pathology (M.L.E.), The Cleveland Clinic Foundation.

Address reprint requests to G.H.B., Center for Computer-Assisted Neurosurgery, Department of Neurosurgery, S80, The Cleveland Clinic Foundation, 9500 Euclid Avenue, Cleveland, OH 44195.

STEREOTACTIC SYSTEMS that use computerized neuroradiologic imaging have led to the development of a large number of stereotaxy-directed neurosurgical procedures. By allowing precise preoperative planning, image-guided stereotactic neurosurgery provides a safe and accurate alternative to many traditional techniques in the diagnosis and treatment of intracranial lesions.

Indications for this technique include: (1) biopsy or resection of brain or other intracranial lesions¹⁻³; (2) drainage of abscess cavities^{2,4}; (3) aspiration of cystic tumors⁵⁻⁷; (4) placement of drainage catheters for decompression of cysts or ventricles^{1,2,6}; (5) evacuation of cerebral hematomas^{8,9}; (6) placement of depth electrodes for electrical recordings in the study of epilepsy^{10,11}; (7) implantation of radioisotopes or hyperthermic devices into intra-axial malignant brain tumors^{12,13}; (8) ablation or stimulation of various intracerebral targets for involuntary movement disorders¹⁴⁻¹⁶ or chronic pain¹⁷⁻¹⁹; and (9) radiosurgical obliteration of vascular malformations or

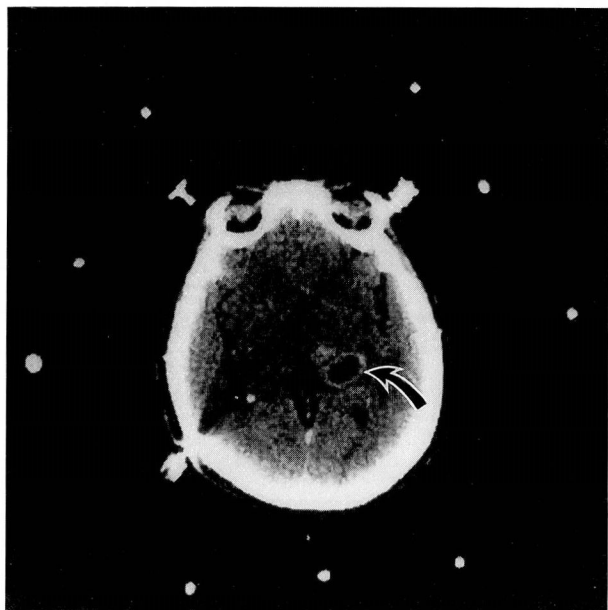

FIGURE 1. Stereotactic computed tomographic scan showing lesion (arrow) and nine reference marks. Ratio of distances between markers within each triad defines location of the central marker with respect to the head-ring. Localization of all three central markers defines the imaging plane.

brain tumors.²⁰⁻²²

Optimal application of these methods is aided by an understanding of their basic principles, techniques, limitations, and results.

BACKGROUND

Stereotactic imaging

Neuroimaging techniques such as computed tomography (CT), magnetic resonance imaging (MRI), single photon-emission computed tomography, and positron-emission tomography (PET) inherently contain spatial information. A rigid stereotactic frame or ring attached to the patient's head serves literally as a frame of reference when used in conjunction with a localizing device appropriate for the imaging modality. Localizers, commonly of the "picket fence" variety, produce reference points or "fiducials" on the image, thereby encoding spatial information (Figure 1).^{23,24} Localizers that use other principles can encode conventional roentgenograms, cut-film angiograms, and digital-subtraction angiograms.²⁵ The location of any point or "pixel" of such an image with respect to the frame (the "stereotactic space") can be determined by three-di-

mensional geometric calculations that can be performed on a scientific calculator or an appropriately programmed computer. When whole structures or volumes are defined in stereotactic space using these principles, the process is known as volumetric stereotaxy.²⁶

Stereotactic arcs

Once a target and a surgical trajectory are determined, precisely engineered hardware fitted to the head-frame allows accurate access. Popular designs include the multiple-interlocking arc and target-centered systems. The multiple-interlocking arc design allows access to virtually any intracranial point without repositioning the arc or the patient²⁷; however, changes in trajectory and its use with multiple targets are tedious and time-consuming.²⁸ Systems that position the target at the center of an arc (by moving the arc with respect to the patient or vice versa) are, in general, easier to set (they may even employ robotics)²⁹ and allow for quick changes in trajectory; however, they may require rotation of the arc or the patient to reach some intracranial targets.

Computer-assisted neurosurgery

While the target coordinates and arc settings can be determined using a calculator, this approach is time-consuming and prone to error. Appropriate software allows nearly instantaneous solution of these problems on personal computers. However, far more advanced computer graphics are required to display the surgical trajectory through the acquired images, to display a target defined by one image modality superimposed on a different type of image ("cross-modality correlation"), or to display cross sections or surfaces. Use of these more sophisticated methods is referred to as computer-assisted stereotaxy.³⁰

Frameless localization

In principle, the patient's head or reference points (fiducials) affixed to the head could replace the head-frame and external localizer. This technique requires (1) spatially accurate collection of a large amount of image data that includes both the fiducials and the region of interest; (2) a surgical three-dimensional localizer; and (3) a powerful computer. Improvements in all of these areas are making frameless localization increasingly practical, and this technique promises to make frame localization unnecessary in many cases.³¹⁻³³

METHODS

Patient data

Patient data from 512 consecutive stereotactic procedures performed at The Cleveland Clinic Foundation by one of the authors (G.H.B.) between June 1987 and January 1992 were entered into a data base in a prospective fashion. Procedures were excluded from this study if five or fewer had been performed; these included stereotactic thrombolysis of intracranial hemorrhage (4 cases), third ventriculostomy (2), cingulotomy (1), and endoscopic procedures (4). The remaining 501 cases are the subject of this review.

Materials

All procedures were performed using the Brown-Roberts-Wells (Radionics, Inc, Burlington, Mass), Cosman-Roberts-Wells (Radionics, Inc, Burlington, Mass), or COMPASS (Stereotactic Medical Systems, Rochester, Minn) stereotactic systems. The Brown-Roberts-Wells system uses the multiple-interlocking arc principle, whereas the Cosman-Roberts-Wells and COMPASS are target-centered systems. In addition, the COMPASS system is fully computer-integrated and capable of computer-assisted procedures and robotic-assisted target positioning.

Neuroimaging was performed with various units including a CT scanner (Picker 1200SX, Picker International, Solon, Ohio), three MRI machines (Technicare 0.6-Tesla, Technicare, Inc, Solon, Ohio; General Electric Signa 1.5-Tesla, General Electric, Milwaukee, Wis; Siemens Magnetom 1.5-Tesla, Siemens, Island, NJ), a PET scanner (Positron Corp, Houston, Tex), and two digital subtraction angiography systems (Technicare, Inc, Solon, Ohio; Siemens, Island, NJ).

The principles of stereotactic localization have been previously described, and the reader is referred to the more detailed accounts by Heilbrun³ and Kelly.²⁴ The choice of surgical technique depends on the stereotactic system used and on the surgeon's preference. A general description of a stereotactic brain biopsy is provided below.

Biopsy

Localization and planning. The head-frame can be applied with the patient under either a local or general anesthetic. When the stereotactic surgical procedure is to be performed on the same day as imaging, the frame is usually secured by four pointed

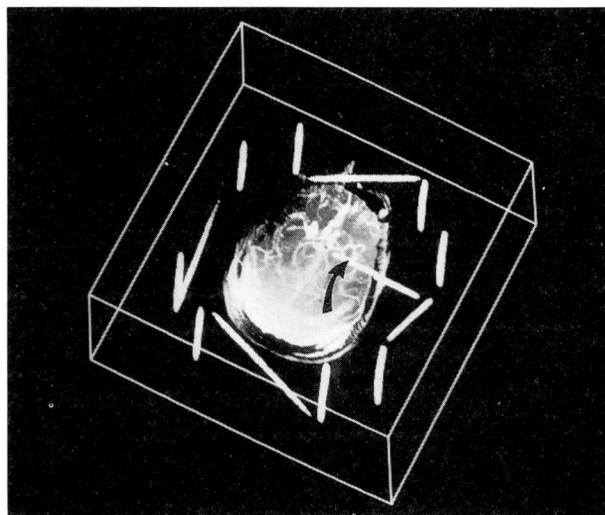


FIGURE 2. Stereotactic trajectory (arrow) projected by computer onto a stereotactically encoded magnetic resonance angiogram.

pins that, under pressure, hold the head-ring in place. If the frame is to be reapplied (such as when imaging data are obtained a day or more before surgery), holes are drilled in the skull's outer table and pin lengths are recorded to allow accurate re-fixation.

We routinely perform CT on all patients, as it is more spatially accurate than MRI or PET and can be used to confirm a target obtained from those images. Contiguous 3-mm slices are scanned through the target and along the surgical trajectory. MRI or PET images, or both, are obtained as required using appropriate localizers. Coordinates of the fiducials are obtained either manually or using the planning computer. Targets are selected and their stereotactic coordinates are calculated.

The surgical trajectory is planned so as to avoid vascular structures and functionally important areas of the brain, minimize intracranial length, and avoid traversing multiple pial planes. The trajectory can be determined by (1) selecting an "entry point" on a neuroimaging study, (2) selecting a point on the scalp at surgery, or (3) directly defining an angle of approach with respect to the target and frame. When the Brown-Roberts-Wells system is used, arc settings must be calculated regardless of which trajectory technique is chosen, whereas with target-centered systems such as the Cosman-Roberts-Wells and COMPASS, this is required only when one of the

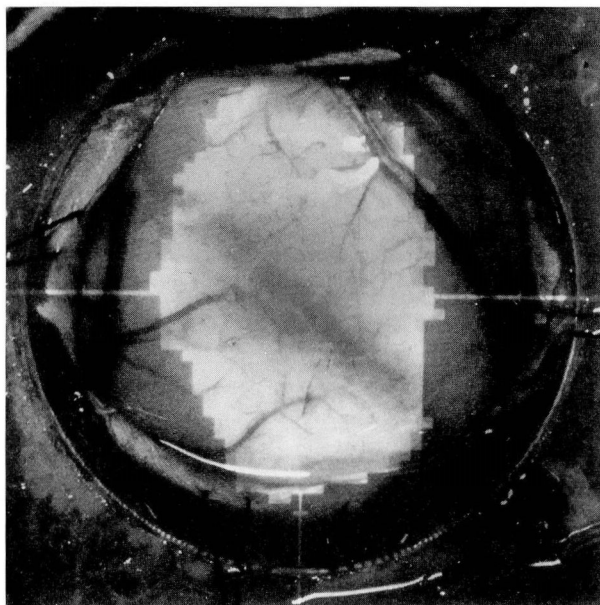


FIGURE 3. Computed image of the tumor boundary is projected onto the surgeon's field of view.

first two techniques is chosen. Computer-assisted techniques allow the surgeon to visualize the surgical trajectory as it passes through the brain and even to see its relationship to the vasculature (Figure 2).

Surgical technique. Biopsy is usually performed with the patient under general anesthesia to reduce the risk of a seizure or dislocation of the head from the frame with the biopsy cannula in place. We favor using a twist drill hole (4.5 mm) rather than a burr hole to achieve skull penetration. The dura is perforated with a stylet. A side-cutting biopsy instrument is advanced to the biopsy site. If the site is adjacent to the ventricular system or cerebrospinal fluid cisterns, or is in the brainstem, the biopsy specimen can be obtained with 1-mm cup forceps or a corkscrew device. The specimens are taken from the target and, when practical and safe, at 10-mm intervals to the periphery. The cores are labelled with their stereotactic depth and are submitted for frozen and routine permanent histologic analysis.

If bleeding is encountered during the biopsy, the guide tube is kept patent by periodically passing a stylet and irrigating the guide tube until bleeding ceases spontaneously. Other hemostatic measures include administration of hypotensive agents, elevation of the head, administration of antifibrinolytics, and, when hemorrhage can not be controlled, instillation of 0.5 mL of thrombin (5000 U/mL).³⁴

The biopsy instrument is withdrawn and the puncture site is closed with a single suture. The head-ring is removed and the patient is taken to the recovery area. A post-biopsy CT scan is obtained and, if no intracranial blood is found, the patient is transferred to a regular nursing unit for overnight neurologic observation.

Tissue handling. At surgery, the tissue specimen is divided and half of it is "snap-frozen" in liquid nitrogen. Cryostat sections stained with hematoxylin-eosin are examined by light microscopy. These frozen-section reports are critical in ensuring that adequate tissue has been obtained. The remaining tissue is placed in Hollande's fixative for paraffin embedding and, if necessary, a portion is placed in 3.75% glutaraldehyde for electron microscopy. Paraffin sections are cut in 5- μ m slices, deparaffinized, and stained with hematoxylin-eosin and, when appropriate, with Gomori's methenamine silver, Ziehl-Neelsen stain, and Gram's stain. Tissue fixed in glutaraldehyde is routinely processed and cut into 1- μ m sections for light microscopy. Thin sections (approximately 0.5 μ m) are cut from selected blocks and stained with uranyl acetate-lead citrate for electron microscopy.

Cyst aspiration or ventricular decompression

Tumor cyst drainage is performed by either direct aspiration using a stainless steel cannula, or insertion of a ventricular catheter attached to a subcutaneous Ommaya reservoir.⁷ Hydrocephalus due to lesions of the third ventricle obstructing both foramina of Monro can be treated with a single catheter by using an entry point in the posterior body of one lateral ventricle and a target in the opposite frontal horn.

Stereotactic craniotomy

Stereotaxy-assisted craniotomy is performed by itself or immediately following stereotactic biopsy. An S-shaped incision is centered about the surgical trajectory. Typically a 1.5- or 2-inch circular cranial trephination is performed and the dura is opened in a cruciate fashion. Point stereotaxy directs the surgeon to the tumor but provides little information regarding the margins of the lesion unless markers are stereotactically placed at the edges.³⁵ Soft tumors are generally "gutted out" to normal brain tissue using microsurgical techniques, whereas firm tumors are removed in one or a few pieces. When volumetric techniques are employed, the tumor margin (as seen

on CT or MRI) is traced into the computer and presented to the surgeon superimposed on the operative field (Figure 3). Frameless techniques provide near real-time visualization of the location of the tip and trajectory of the surgical instrument on multiplanar images (Figure 4).³⁶ The volumetric and frameless approaches usually require that the lesion be removed en bloc in order to minimize "brain shift" and potentially spurious localization of the lesion's boundary.³⁷

Thalamotomy

Stereotactic thalamotomy of the nucleus ventralis lateralis is performed with the patient awake so that his or her neurologic status can be monitored during the procedure. Details of the surgical techniques have been previously described. After CT of both the anterior and posterior commissures is performed, the stereotactic coordinate of the nucleus ventralis lateralis is determined.¹⁶ A burr hole is fashioned in the precoronal area and a radio-frequency electrode advanced to the target site.

Stimulation to drive or suppress the movement disorder is performed and the patient is monitored for potentially undesirable neurologic side effects.^{38,39} The electrode is repositioned as required and a test lesion is created. Barring adverse effects, a permanent lesion is created that is 4 mm in diameter.¹⁴ Care is taken to avoid the nearby corticospinal tracts, thalamic sensory nuclei, reticular activating pathways, or dorsal thalamic nuclei.

Interstitial radiation (brachytherapy)

The implantation of radioactive sources may be useful in the management of some newly diagnosed or recurrent malignant brain tumors. Thin, contiguous CT slices are obtained that transect the tumor. In order to ensure delivery of an adequate radiation dose to the target volume (typically 6000 cGy)

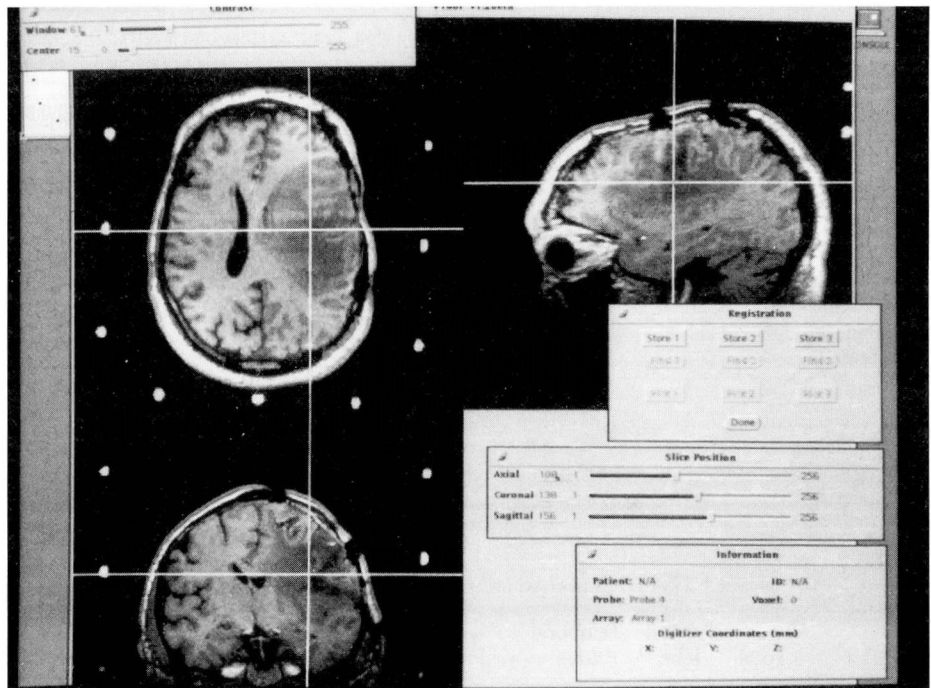


FIGURE 4. Multiplanar display showing real-time localizing information using frameless stereotactic sonic wand developed at the Cleveland Clinic.

while avoiding radionecrosis of uninvolved areas, three-dimensional computer-assisted dosimetry is used. Double-lumen afterloading catheters are inserted via the predetermined trajectory to the proper depth using a percutaneous twist drill technique. The catheters are secured to the scalp, then stereotactic skull roentgenograms are obtained to confirm catheter position. Modification of catheter location is rarely required but can be performed at this time. Iodine-125 or iridium-192 seeds are loaded into these catheters after the patient has gone to a regular nursing floor.

Depth electrode placement

Stereotactically placed depth electrodes are commonly used to define the laterality and extent of an epileptic focus in the mesial structures of the temporal lobe, as well as other areas. For temporal lobe placement, MRI of 3-mm contiguous stereotactic coronal sections is obtained, and the locations of the anterior and posterior hippocampi and amygdala are determined bilaterally. Because of possible nonlinearities in MRI stereotaxy, the coordinates are confirmed using CT stereotaxy. Target-centered arcs reduce the duration of surgery compared with multi-

TABLE 1
TYPES AND OUTCOMES OF 501 STEREOTACTIC NEUROSURGICAL PROCEDURES

Procedure	Total	Unchanged	Temporarily worse	Worse	Improved	Died
Biopsy	212	175	18	5	12	2
Brachytherapy	10	10	0	0	0	0
Craniotomy	111	84	6	4	15	2
Cyst aspiration or ventricular decompression	35	14	0	0	20	1
Depth electrode placement	48	48	0	0	0	0
Radiosurgery	59	57	2	0	0	0
Shunt placement	10	4	6	0	0	0
Thalamotomy	16	2	0	0	14	0
Totals	501	394	32	9	61	5

TABLE 2
SITES OF 212 CONSECUTIVE STEREOTACTIC BRAIN BIOPSIES

	Total	Frontal lobe	Temporal lobe	Parietal lobe	Occipital lobe	BG/T*	Pineal gland	Vent/CC†
Supratentorial								
Left:	87	48	8	23	3	4	0	1
Right:	87	40	15	20	6	6	0	0
Other:	18						6	12
Total:	192	88	23	43	9	10	6	13
Infratentorial	20							
All	212	88	23	43	9	10	6	13

*BG/T, basal ganglia or thalamus.

†Vent/CC, ventricle or corpus callosum.

ple intersecting arcs because this procedure involves multiple targets and trajectories.²⁸ Parallel trajectories through the middle temporal gyrus are defined. The semiflexible multicontact depth electrodes are advanced to their targets and secured for subsequent electrophysiologic monitoring.

Radiosurgery (photon surgery)

CT slices of 1 or 2 mm are used for target selection and dosimetry, at times with stereotactic angiograms. Thicker CT slices throughout the cranium are obtained to allow calculation of beam attenuation and scatter. Radiosurgery at the Cleveland Clinic is performed using a specially modified 6.0 MeV linear accelerator guided by a three-dimensional dosimetry program. The target is positioned in the center of rotation of the table and gantry. The

gantry is rotated in multiple predefined non-coplanar arcs so as to disperse the entry dose, resulting in a very high cumulative dose at the target with steep dose gradients at the periphery of the lesion.^{20,21}

RESULTS

Four hundred nineteen patients underwent 501 procedures. The average age of these patients was 44 years (range 2 to 91). The outcomes of each type of stereotaxy-assisted procedure are shown in Table 1.

Biopsy

Two hundred eleven patients underwent 212 biopsies, and the specimens were histologically examined from multiple stereotactic levels. The distribution of biopsy locations is shown in Table 2. A histological diagnosis could be established in 160 of 161 biopsies (99%) in patients with neoplasms, and in 43 of 51 biopsies (84%) in patients with nonneoplastic disorders. Although biopsy was only intended as a diagnostic procedure, 12 patients (6%) improved clinically after stereotactic brain biopsy, likely due to reduced mass effect from fluid aspiration at biopsy. Sustained significant neurologic deficits occurred in five patients (2%), and an additional 18 (8%) were temporarily worse after biopsy.

No deaths were related to the intracranial consequences of the stereotactic procedure. Two patients with glioblastoma multiforme and multiple medical disorders died within 1 week of stereotactic biopsy due to pneumonia. Post-biopsy CT of both patients revealed no hemorrhage at the biopsy sites. There were no wound complications in any of the patients.

Frozen-section guidance ensured diagnosis of tumor in all but one patient, whose excessive bleeding

required a second stereotactic biopsy for histologic diagnosis. A wide variety of glial and nonglial tumors was diagnosed (Table 3). The most frequent neoplasm was glioblastoma multiforme (44 patients). In many cases, immunohistochemistry was performed on frozen and paraffin-embedded tissue. This aided diagnosis, particularly in cases of lymphoma and metastatic carcinoma. Among the 50 patients with nonneoplastic disorders who underwent stereotactic biopsy, 19 had inflammatory lesions. Other diagnoses derived by stereotactic biopsy are outlined in Table 3.

Stereotaxy-assisted craniotomy

One hundred three patients underwent 111 stereotaxy-assisted craniotomies; Tables 4 and 5 detail the locations and histologic diagnoses. Of these, 37 used the Brown-Roberts-Wells arc and 18 used the Cosman-Roberts-Wells; all of these were point-stereotactic craniotomies. Another 53 craniotomies were performed using the COMPASS arc, and 20 were performed using a frameless sonic wand³³ (including 17 in which the wand was used in conjunction with the COMPASS arc). Morbidity rates were comparable with other published reports and were not statistically different between the groups ($P > .05$, chi-square test). The incidence of wound infection in the immediate postoperative period was 2%. Two patients died of causes not due to neurologic complications of the surgical procedure.

Interstitial radiation

Ten patients underwent implantation of 39 catheters. No neurologic morbidity was associated with the procedures, although two patients developed wound complications. Two patients developed radiation necrosis.

Radiosurgery

Fifty-nine patients (mean age 55 years, range 19 to 77) underwent radiosurgical treatment of 54 tumors and five vascular malformations. The histologic diagnoses of the lesions are presented in Table 6. Clinical responses (reduction or stabilization in size of tumor or malformation) occurred in 48 tumors (89%) and in four malformations. Although six of seven unilateral acoustic neuromas responded to treatment, neither of the patients with bilateral disease stabilized. Although both patients with glioblastomas < 2.5 cm in diameter responded to treatment, no response was observed in the three with larger lesions.

TABLE 3
HISTOLOGIC DIAGNOSES IN 212 CONSECUTIVE
STEREOTACTIC BRAIN BIOPSIES

Tumors	Total
Astrocytoma, anaplastic	22
Astrocytoma, low-grade	28
Astrocytoma, pilocytic	2
Brainstem glioma	2
Ependymoma	3
Ganglioglioma	1
Germinoma	8
Glioblastoma multiforme	44
Gliosarcoma	1
Hamartoma	1
Lymphoma	3
Meningioma	4
Metastasis	28
Nondiagnostic	1
Oligodendroglioma, low-grade	8
Pineal	3
Subependymoma	1
Teratoma	1
Subtotal	161
Other	
Abscess	1
Amyloid	1
Cerebritis	2
Colloid cyst	1
Demyelination	11
Encephalitis	3
Hematoma	1
Heterotopia	1
Infarct	4
Lymphomatoid granulomatosis	2
Nondiagnostic	8
Progressive multifocal leukoencephalopathy	3
Radiation necrosis	5
Vascular malformation	1
Vasculitis	3
Vasculopathy	4
Subtotal	51
Total	212

Early significant morbidity was limited to two patients with preexisting epilepsy whose seizure frequency substantially increased a few hours after treatment. Delayed radiation necrosis was observed in five patients, all of whom had also received external radiotherapy.

Cyst aspiration or ventricular decompression

Cyst aspiration was performed 10 times by itself and 25 times in association with placement of a subcutaneous reservoir. Clinical improvement was observed in 4 and 16 patients, respectively. Internal shunting of ventricles or fluid cavities was performed 10 times, with improvement noted in 6 patients. No patient's condition deteriorated, and

TABLE 4
SITES OF 111 CONSECUTIVE STEREOTACTIC CRANIOTOMIES

	Total	Frontal lobe	Temporal lobe	Parietal lobe	Occipital lobe	BG/T*	Pineal gland	Vent/CC†
Supratentorial								
Left:	54	24	9	18	1	2	0	0
Right:	53	20	8	17	8	0	0	0
Other:	3	0	0	0	1	0	0	2
Total:	110	44	17	35	10	2	0	2
Infratentorial								
	1							
All	111	44	17	35	10	2	0	2

*BG/T, basal ganglia or thalamus.
†Vent/CC, ventricle or corpus callosum.

TABLE 5
HISTOLOGIC DIAGNOSES IN 111 CONSECUTIVE STEREOTACTIC CRANIOTOMIES

Tumor	Total
Astrocytoma, anaplastic	7
Astrocytoma, low-grade	10
Astrocytoma, pilocytic	1
Ependymoma	1
Ganglioglioma	2
Glioblastoma	26
Gliosarcoma	2
Meningioma	5
Metastases	42
Neurocytoma	1
Oligodendroglioma, anaplastic	3
Oligodendroglioma, low grade	2
Subtotal	102
Other	
Colloid cyst	2
Cystercicosis	1
Hematoma	3
Radiation necrosis	1
Sarcoidosis	1
Vascular malformation	1
Subtotal	9
Total	111

there were no infectious complications. One patient died in the immediate postoperative period due to preexisting systemic sepsis unrelated to the surgical procedure.

Depth electrode placement

Forty-eight patients underwent placement of 280 depth electrodes (mean 5.8 per patient). The position of the electrodes was satisfactory in all but three cases. In 31 patients (65%), seizure foci were found that were amenable to ablative surgery. Two patients

had asymptomatic subdural hematomas that were discovered on routine postoperative MRI. There were no infections. One fractured electrode required wound exploration for retrieval.

Thalamotomy

The most common indication for ventrolateral thalamotomy in this series of 16 procedures in 14 patients was intractable intention tremor due to demyelinating disease. Eleven of 14 patients (79%) improved following ventrolateral thalamotomy. The three patients who did not improve underwent repeated thalamotomy and improved clinically. In no case was there a serious protracted complication from the procedure, although half the patients with multiple sclerosis developed new disease-related symptoms unrelated to the site of biopsy.

DISCUSSION

The various stereotaxy-assisted neurosurgical procedures reported here share a low neurologic and wound morbidity. Analyses of the clinical results and suggested use of these applications are discussed below.

Biopsy

Rational management of neurologic disease requires an accurate diagnosis. Although CT and MRI often give a strong indication of the type of lesion present, they do not offer the accuracy of a histologically verified diagnosis, which may vary from the clinical diagnosis in over 20% of cases.^{6,40,41}

The morbidity (hemorrhage, edema, seizures, neurologic deficit) and mortality rates seen in this series are low and compare favorably with those reported in other series.^{1,2,6} Of 212 consecutive stereotactic biopsies, there were 18 cases of transient neurologic deficits and 5 permanent neurologic deficits, with most complications occurring early in the series. The two deaths that occurred in the postoperative period were not related to the procedure. The proposed mechanisms for transient deficits are edema, blood, or air at the

biopsy site. Chronic deficits may be due to tissue damage from hemorrhage (four cases) or direct tissue destruction by the biopsy. The risk of severe hemorrhage is small, but is greatest for lesions that are vascular, adjacent to vascular structures or ependymal surfaces, or close to the cortex where cortical vessels are involved.

Stereotactic biopsy is commonly used for diagnosis of cerebral lesions when traditional neurosurgical techniques would be dangerous or of little therapeutic benefit. Also, stereotactic biopsy is often the diagnostic method of choice when multiple lesions (metastasis or abscess) or adverse medical conditions exist, or if the patient is of advanced age. Unlike stereotactic biopsy, free-hand CT-guided brain biopsy frequently results in bleeding and neurologic complications, and requires prolonged use of the CT scanner.

Causes of nondiagnostic biopsies include surgical inexperience, technical error, and sampling tissue from necrotic areas.¹ Necrosis may be present in a variety of neoplastic and nonneoplastic processes including glioblastoma multiforme, primary central nervous system lymphoma, metastasis, or abscess.⁴⁰ We attribute the low rate of nondiagnostic biopsies in this series (1% of neoplasms, 14% of nonneoplasms) to careful technique and the use of frozen-section confirmation at biopsy to guide the number and site of biopsies. Frozen-section interpretation also allows the neuropathologist to ensure that tissue is adequately processed for special studies, ie, electron microscopy, immunohistochemistry, or flow cytometry. It should be noted, however, that the histologic grade of biopsied tissue may not reflect the highest grade of the tumor due to sampling error.⁴⁰

The high benefit-to-risk ratio of stereotactic biopsy supports its use in a wide variety of neurologic disorders when definitive diagnosis cannot be obtained by less invasive means.

Cyst aspiration or ventricular decompression

Stereotactic decompression of cystic structures frequently resulted in neurologic improvement (20 of 35 patients, 57%) and was associated with virtually no morbidity. Its use in conjunction with placement of a subcutaneous reservoir has been shown to be of particular value in the management of cystic brain tumors.⁷ Cannulation of slit, displaced, or multiply obstructed ventricles for external drainage or shunting of cerebrospinal fluid can be accomplished using similar techniques.

TABLE 6
HISTOLOGIC DIAGNOSES IN 59 CONSECUTIVE
RADIOLOGICAL PROCEDURES

Tumor	Total
Acoustic	9
Astrocytoma, low-grade	2
Chordoma	2
Fibrosarcoma	1
Glioblastoma	5
Glomus jugulare	1
Meningioma	12
Metastasis	19
Oligodendroglioma	1
Pituitary adenoma	1
Subependymoma	1
Subtotal	54
Other	
Arteriovenous malformation	4
Cavernous angioma	1
Subtotal	5
Total	59

Stereotactic craniotomy

Adaptation of stereotactic techniques to craniotomy assists the planning of minimal craniotomy, localization of subcortical lesions, and determination of tumor boundaries.^{26,35,42,43} Low rates of wound and neurologic morbidity, reduced time of surgery and hospitalization, and access to otherwise "inoperable" lesions are among the potential benefits of this technique. The results of this series are difficult to interpret: they represent a unique population of patients, many of whom had lesions considered inoperable by other surgeons, and the more sophisticated techniques (volumetric stereotaxy and frameless localization) were applied in the most difficult cases. Nonetheless, the low incidence of serious morbidity (4%) and mortality (2%) seen in our series is comparable with the results of others.

The extent of tumor resection is increasingly recognized as an important prognostic factor in primary and metastatic brain neoplasms.⁴⁴⁻⁴⁶ Although tumor boundary definition can be achieved using simple point-stereotactic techniques,¹⁹ these methods tend to be cumbersome and define only a few points of the tumor-brain interface. Volumetric techniques provide excellent definition of the complete tumor border, but some surgeons find frame stereotaxy systems cumbersome, nonintuitive, and costly. New frameless methods of stereotactic localization promise to again revolutionize surgical resection of brain lesions by providing real-time localization data in a more streamlined process than frame-based techniques.

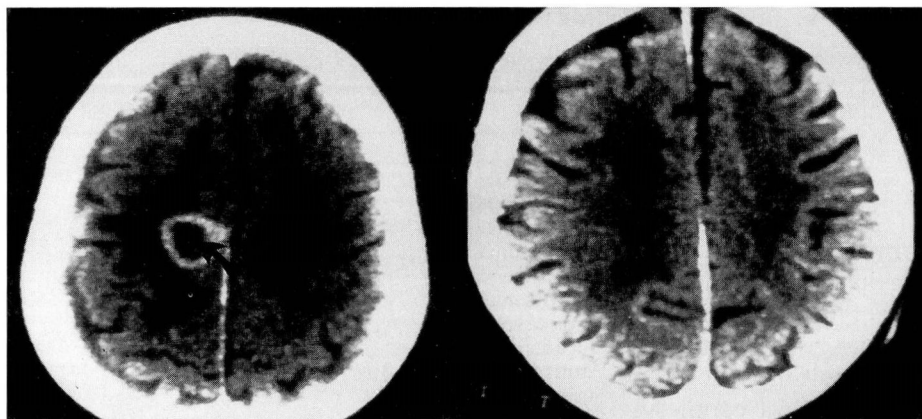


FIGURE 5. On the left, deep right frontal lung metastasis (arrow) before stereotactic radiosurgery; on the right, the same tumor 9 months later.

Radiosurgery

Although not a new technique, stereotactic radiosurgery has become an increasingly important tool in the management of brain neoplasms.^{22,47,48} The efficacy rate of this technique is high (> 85%), while early morbidity is generally infrequent when it is used to stabilize or shrink a wide variety of tumors (Figure 5), as well as small arteriovenous malformations. However, use of this technique has not been subjected to randomized comparisons with traditional surgical management in any disorder. Its role, therefore, should probably be confined to treatment of small lesions that have a morbid natural history and unacceptable surgical risk.

Thalamotomy

The use of ablative thalamic procedures became rare after the introduction of pharmacologic therapy for Parkinson's disease. Our results support the contention that ventrolateral thalamotomy remains a reasonable mode of therapy in medically intractable movement disorders. Reports that the procedure may result in therapeutic benefits unattainable with medical therapy, and that safety is enhanced using computer-guided techniques, make ventrolateral thalamotomy a consideration in selected cases of Parkinson's disease as well.^{14,49,50}

Brachytherapy

Although the number of cases in which radioactive sources were implanted in tumor beds was small in this series, the procedure appeared to be associated with low risk. The benefit of interstitial radiation in

the management of malignant glial neoplasms is controversial,^{13,51} with recent evidence suggesting that a substantial portion of the procedure's apparent benefit may be attributable to patient selection.⁵² A soon-to-be-completed multicenter, randomized study evaluating the efficacy of this technique in newly diagnosed malignant astrocytoma and glioblastoma should resolve this issue.

Depth electrodes

Stereotactically placed depth electrodes may provide information on localization of the brain's electrical activity that is otherwise unobtainable. Although the procedure is historically associated with a 1% to 2% risk of intracerebral hemorrhage or death, we have found placement of these semiflexible electrodes using CT and MRI stereotactic guidance to be accurate and safe without angiography. Angiographic visualization of the proposed electrode trajectory may further enhance safety, but the benefits must be weighed against the risks of this invasive procedure. New noninvasive means of imaging the cerebral vasculature, such as stereotactic magnetic resonance angiography or CT angiography, may prove valuable in this setting.

Advanced computer applications

As computers become more powerful and costs fall, advanced computer techniques are expected to continue to improve the benefit, efficiency, and safety of neurosurgical procedures in the coming decade. Frameless localization in other organ systems, sophisticated robotic techniques, image correlation, and detailed preoperative planning and simulations (ie, "virtual surgery") are other likely developments.

ACKNOWLEDGMENT

The authors thank Stereotactic Medical Systems, Dr. Patrick Kelly, Bruce Kall, and Steve Goerss for their collaborative efforts in developing a portion of our computer-assisted neurosurgical system; Picker International (Highland Heights, Ohio) for furnishing a ViStar Medical Imaging Supercomputer and tech-

nical assistance with the sonic wand; and Science Accessories Corporation (Stratford, Conn) for their insights into developing and optimizing accuracy of the sonic wand.

Our thanks are also extended to the personnel of the Division of Radiology, especially the Departments of Radiation Therapy, Nuclear Medicine, Magnetic Resonance Imaging, and Neuro-

diology for their unwavering support, and to the members of the Center for Computer-Assisted Neurosurgery for their ongoing development of stereotaxy and computer-assisted techniques.

We also wish to thank Ms. Sharon Preztak for her expert preparation of this manuscript.

REFERENCES

1. Apuzzo MLJ, Chandrasoma PT, Cohen D, Zee CS, Zelman V. Computed imaging stereotaxy: experience and perspective related to 500 procedures applied to brain masses. *Neurosurgery* 1987; 20:930-937.
2. Apuzzo MLJ, Sabshin JK. Computed tomographic guidance stereotaxis in the management of intracranial mass lesions. *Neurosurgery* 1983; 12:277-285.
3. Heilbrun MP, Roberts TS, Wells TH, et al. Technical Manual: Brown-Roberts-Wells (BRW) CT stereotaxic Guidance System. Burlington, Mass: Radionics Inc., 1982.
4. Dyste GN, Hitchon PW, Menezes AW, VanGilder JC, Greene GM. Stereotaxic surgery in the treatment of multiple brain abscesses. *J Neurosurg* 1988; 69:188-194.
5. Bosch DA, Rahn D, Backlund EO. Treatment of colloid cysts of the third ventricle by stereotactic aspiration. *Surg Neurol* 1978; 9:15-18.
6. Lundsford LD, Martinez AJ. Stereotactic exploration of the brain in the era of computed tomography. *Surg Neurol* 1984; 22:222-230.
7. Rogers LR, Barnett GH. Percutaneous aspiration of brain tumor cysts via the Ommaya reservoir system. *Neurology* 1991; 41:279-282.
8. Backlund EO, von Holst H. Controlled subtotal evacuation of intracerebral hematomas by stereotactic technique. *Surg Neurol* 1978; 9:99-101.
9. Matsumoto K, Hondo H. CT-guided stereotaxic evaluation of hypertensive intracerebral hematomas. *J Neurosurg* 1984; 61:440-448.
10. Lundsford LD, Latchaw RE, Vries JK. Stereotactic implantation of deep brain electrodes using computed tomography. *Neurosurgery* 1983; 13:280-286.
11. Olivier A, Bertrand G, Peters T. Stereotactic systems and procedures for depth electrode placement: technical aspects. *Appl Neurophysiol* 1983; 46:37-40.
12. Bernstein M, Gutin PH. Interstitial irradiation of brain tumors: a review. *Neurosurgery* 1981; 9:741-750.
13. Gutin PH, Phillips PL, Wara WM, et al. Brachytherapy of recurrent malignant brain tumors with removable high-activity iodine 125 sources. *J Neurosurg* 1984; 60:61-68.
14. Kelly PJ, Ahlskog JE, Goerss SJ, et al. Computer-assisted stereotactic ventralis lateralis thalamotomy with microelectrode recording control in patients with Parkinson's Disease. *Mayo Clin Proc* 1987; 62:655-664.
15. Speelman JD, Van Manen J. Stereotactic thalamotomy for the relief of intention tremor of multiple sclerosis. *J Neurol Neurosurg Psychiatry* 1984; 47:596-599.
16. Rosenfeld JV, Barnett GH, Palmer J. Computed tomography guided stereotactic thalamotomy using the Brown-Roberts-Wells System for nonparkinsonian movement disorders: technical note. *Stereotact Funct Neurosurg* 1991; 56:184-192.
17. Shieff C, Nashold BS Jr. Stereotactic mesencephalic tractotomy for the relief of thalamic pain. *Br J Neurosurg* 1987; 1:305-310.
18. Gildenberg PL. Functional neurosurgery. In: Schmidek HH, Sweet WH editors. *Operative Neurosurgery Vol II*. New York: Grune Stratton, 1982:993-1043.
19. Hassenbusch SJ, Pillay PK, Barnett GH. Radiofrequency cin-
20. Coffey RJ, Lunsford LD. Stereotactic radiosurgery using the 201 cobalt-60 source gamma knife. *Neurosurg Clin North Am* 1990; 1:933-954.
21. Lindquist C, Steiner L. Stereotactic radiosurgical treatment of arteriovenous malformations. In: Lunsford LD, editor. *Modern stereotactic neurosurgery*. Boston: Marinus Nijhoff Publishing, 1988:491-505.
22. Lutz W, Winston KR, Maleki N. A system for stereotactic radiosurgery with a linear accelerator. *Int J Radiat Oncol Biol Phys* 1988; 14:373-381.
23. Brown RA. A computerized tomography-computer graphics approach to stereotaxic localization. *J Neurosurg* 1979; 50:715-720.
24. Kelly PK. Stereotactic localization. In: Kelly PK, editor. *Tumor stereotaxis*. Philadelphia: W.B. Saunders, 1991:88-121.
25. Siddon RL, Barth NH. Stereotaxic localization of intracranial targets. *Int J Radiat Oncol Biol Phys* 1987; 13:1241-1246.
26. Kelly PJ. Volumetric stereotactic surgical resection of intra-axial brain mass lesions. *Mayo Clin Proc* 1988; 63:1186-1198.
27. Brown RA, Roberts TS, Osborn AG. Stereotaxic frame and computer software for CT-directed neurosurgical localization. *Invest Radiol* 1980; 15:308-312.
28. Pillay PK, Barnett GH, Awad, IA. MRI-guided stereotactic placement of depth electrodes in temporal lobe epilepsy: a comparison of CRW and BRW arc systems. *Br J Neurosurg* 1992; 6:47-53.
29. Kelly PK. Stereotactic instruments. In: Kelly PK, editor. *Tumor stereotaxis*. Philadelphia: W.B. Saunders, 1991:23-50.
30. Kelly PK. The computer as a neurosurgical instrument. In: Kelly PK, editor. *Tumor stereotaxis*. Philadelphia: W.B. Saunders, 1991:66-87.
31. Roberts DW, Strohbehn JW, Friets EM, Kettenberger J, Hartov A. The stereotactic operating microscope: accuracy refinement and clinical experience. *Acta Neurochir Suppl (Wien)* 1989; 46:112-114.
32. Watanabe E, Watanabe T, Manaka S, Mayanagi Y, Takakura K. Three-dimensional digitizer (neuronavigator): new equipment for computed tomography-guided stereotaxic surgery. *Surg Neurol* 1987; 27:543-547.
33. Barnett GH, Kormos DW, Steiner CP, Weisenberger J. Intraoperative localization using an armless, frameless stereotactic wand. *J Neurosurg* 1993; 78:510-514.
34. Chimowitz MI, Barnett GH, Palmer J. Treatment of intractable arterial hemorrhage during stereotactic brain biopsy with thrombin. Report of three patients. *J Neurosurg* 1991; 74:301-303.
35. Hassenbusch SJ, Anderson JS, Pillay PK. Brain tumor resection aided with markers placed using stereotaxis guided by magnetic resonance imaging and computed tomography. *Neurosurgery* 1991; 28:801-806.
36. Barnett GH, Kormos DW, Steiner CP, Weisenberger J. Intraoperative localization using an armless, frameless stereotactic wand. *J Neurosurg* 1993; 78:510-514.
37. Kelly PK. Stereotactic resection: general principles. In: Kelly PK, editor. *Tumor stereotaxis*. Philadelphia: W.B. Saunders, 1991:268-295.
38. Bravo G, Parera C, Seiquer G. Neurological side effects in a series of operations on the basal ganglia. *J Neurosurg* 1965; 24:640-647.

39. Broggi G, Angelini L, Giorgi C. Neurological and psychological side effects after stereotactic thalamotomy in patients with cerebral palsy. *Neurosurgery* 1980; **7**:127-134.
40. Chandrasoma PT, Smith MM, Apuzzo ML. Stereotactic biopsy in the diagnosis of brain masses: comparison of results of biopsy and resected surgical specimen. *Neurosurgery* 1989; **24**:160-165.
41. Kelly PJ. Computer-assisted stereotaxis: new approaches for the management of intracranial intra-axial tumors. *Neurology* 1986; **36**:535-541.
42. Hariz MI, Fodstad H. Stereotactic localization of small subcortical brain tumors for open surgery. *Surg Neurol* 1987; **28**:345-350.
43. Kelly PJ, Kall BA, Goerss SJ. Computer-interactive stereotactic resection of deep-seated and centrally located intra-axial brain lesions. *Appl Neurophysiol* 1987; **50**:107-114.
44. Mahaley MS Jr, Mettlin C, Natarajan N, Laws ER Jr, Peace BB. National survey of patterns of care for brain-tumor patients. *J Neurosurg* 1989; **71**:826-836.
45. North CA, North RB, Epstein JA, Piantadosi S, Wharam MD. Low-grade cerebral astrocytomas: survival and quality of life after radiation therapy. *Cancer* 1990; **66**:6-14.
46. Patchell RA, Tibbs PA, Walsh JW, et al. A randomized trial of surgery in the treatment of single metastases to the brain. *N Engl J Med* 1990; **322**:494-500.
47. Leksell L. Stereotactic radiosurgery. *J Neurol Neurosurg Psychiatry* 1983; **46**:797-803.
48. Loeffler JS, Kooy HM, Wen PY, et al. The treatment of recurrent brain metastases with stereotactic radiosurgery. *J Clin Oncol* 1990; **8**:576-582.
49. Ohye C, Hirai T, Miyazaki M, Shibasaki T, Nakajima H. Ventrolateral thalamotomy for the treatment of various kinds of tremor. *Appl Neurophysiol* 1982; **45**:275-280.
50. Siegfried J, Rea GL. Thalamotomy for Parkinson's disease. In: Lunsford LD, editor. *Modern stereotactic neurosurgery*. Boston: Martinus Nijhoff, 1988:333-340.
51. Munding F, Ostertag CB, Birg W, Weigel K. Stereotactic treatment of brain lesions. Biopsy, interstitial radiotherapy (iridium-192 and iodine-125) and drainage procedures. *Appl Neurophysiol* 1980; **43**:198-204.
52. Florell RC, Macdonald DR, Irish WD, et al. Selection bias, survival, and brachytherapy for glioma. *J Neurosurg* 1992; **76**:179-183.

