

JAMES K. STOLLER, MD, AND DAVID L. LONGWORTH, MD, EDITORS

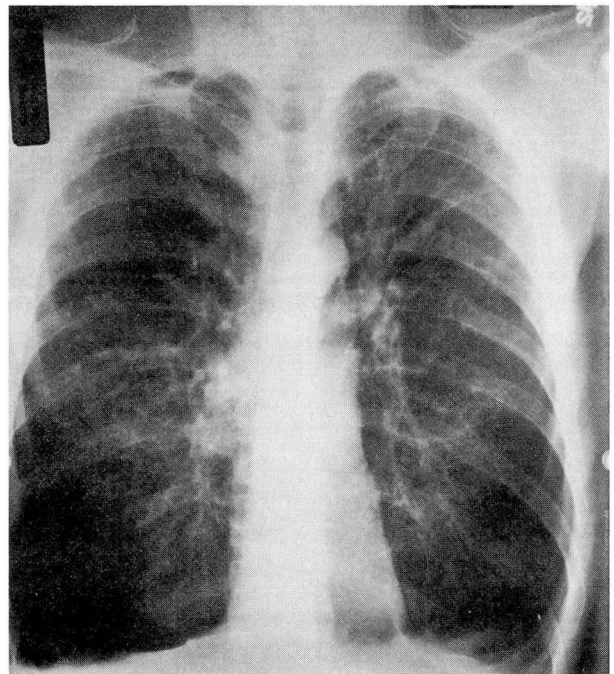
SELF-TEST

Early-onset emphysema

A 42-YEAR-OLD WHITE MAN PRESENTS WITH A 5-month history of progressive shortness of breath without wheezing. He denies a personal or family history of asthma and never smoked cigarettes or consumed illicit drugs. He has no risk factors for human immunodeficiency virus infection and takes no medications. A family history reveals childhood liver disease in his younger sister.

On physical examination, he appears thin and is breathing comfortably (16 respirations per minute) at rest. He is afebrile, his blood pressure is 122/78 mm Hg, and his heart rate is 82 beats per minute and regular. Examination reveals diminished breath sounds bilaterally without wheezing, distant heart tones, no abdominal organomegaly, and normal skin without edema.

The chest roentgenogram is shown (*Figure*). Spirometry after bronchodilator therapy shows the forced expiratory volume in 1 second is 1.32 L (48% of predicted value) and the forced expiratory volume in 1 second divided by the forced vital capacity is 0.51 (slightly diminished). Single-breath diffusing capacity for carbon monoxide is decreased (47% of predicted value with correction for alveolar volume), and room-air arterial blood gas measurement shows PaO₂ 69 mm Hg, PaCO₂ 34 mm Hg, and pH 7.44 (alveolar-arterial oxygen gradient 36 mm Hg).



FIGURE

Q1 What tests would be most appropriate to demonstrate the likeliest cause of this patient's shortness of breath?

- ☐ Echocardiography
- ☐ Formal cardiopulmonary exercise test
- ☐ Methacholine challenge test
- ☐ Serum level for alpha₁-antitrypsin
- ☐ Isoelectric focusing for alpha₁-antitrypsin

Q2 If this patient were found to have α_1 -antitrypsin deficiency, which of the following statements would not accurately characterize the patient? (Indicate all that apply.)

- ☐ A serum level of 40 $\mu\text{mol/L}$ (320 mg/dL) is detected
- ☐ The phenotype is found to be PI^*MZ
- ☐ There is a family history of panniculitis
- ☐ The phenotype is PI^*SZ
- ☐ The cause of his sister's liver disease is viral hepatitis B, but periodic acid-Schiff-positive, diastase-resistant hepatic inclusions are found on liver biopsy

Discussion

The patient described has severe deficiency of α_1 -antitrypsin, likely due to the PI^*ZZ phenotype. He presents with early-onset emphysema in the absence of antecedent smoking, a presentation which is very unusual for the more common, centriacinar emphysema typically seen in cigarette smokers in the sixth or seventh decade of life. Serum levels of α_1 -antitrypsin vary with the patient's phenotype, the most common of the severe deficient phenotypes being PI^*ZZ . The risk of emphysema with α_1 -antitrypsin deficiency is believed to show a threshold effect: the risk of emphysema does not rise until serum levels fall below 11 $\mu\text{mol/L}$ (approximately 80 mg/dL). Mean serum values for PI^*ZZ homozygotes approximate 6 $\mu\text{mol/L}$, whereas PI^*MZ heterozygotes and approximately 85% of PI^*SZ patients have serum levels exceeding 11 $\mu\text{mol/L}$, thereby protecting them from emphysema. Approximately 15% of PI^*SZ patients have serum levels below 11 $\mu\text{mol/L}$, accounting for the slightly higher than normal prevalence of emphysema among PI^*SZ populations.

The putative pathogenesis of emphysema in severe α_1 -antitrypsin deficiency is the unopposed breakdown of lung elastin by neutrophil elastase. In contrast, the liver disease (neonatal hepatitis or cirrhosis, adult-onset cryptogenic cirrhosis, or hepatoma) seen with some deficient phenotypes (ie, PI^*ZZ and PI^*Z heterozygotes, PI^*MM Malton) is caused by impaired secretion of α_1 -antitrypsin by the hepatocyte, resulting in the accumulation of these molecules within the hepatocyte.

Therapy for α_1 -antitrypsin deficiency-related emphysema includes standard treatment for chronic obstructive pulmonary disease: one should emphasize smoking cessation, vaccinate against pneumonia and influenza, give bronchodilators, prescribe pulmonary rehabilitation programs to enhance functional status, and possibly use corticosteroids or antibiotics, or both, for acute exacerbations. Proposed specific therapy for patients with severe deficiency of α_1 -antitrypsin (serum levels < 11 $\mu\text{mol/L}$) includes intravenous infusion of a purified preparation of pooled human α_1 -antitrypsin. Such therapy has biochemical efficacy based on its ability to restore serum and lung epithelial lining levels of α_1 -antitrypsin and antineutrophil elastase activity; however, evidence of clinical efficacy in preventing the development or progression of emphysema is not yet available. Because the liver disease associated with some of the severe deficient phenotypes is not related to proteolysis but rather to accumulation of α_1 -antitrypsin in the hepatocytes, augmentation therapy with intravenous purified α_1 -antitrypsin has not been entertained as treatment for the liver disease. Other therapeutic options include liver transplantation for patients with advanced liver disease, and lung transplantation (usually of a single lung) for those with advanced lung disease.

JAMES K. STOLLER, MD
Department of Pulmonary and
Critical Care Medicine
The Cleveland Clinic Foundation