

DAVID L. LONGWORTH, MD, AND JAMES K. STOLLER, MD, EDITORS

A woman with amenorrhea and galactorrhea

A 35-year-old woman presents with a 4-month history of amenorrhea and galactorrhea accompanied by nausea and fatigue. She denies headaches, visual changes, weight change, or change in bowel habits. Her only medication is acetaminophen for occasional headaches.

On physical examination, her pulse is 76, blood pressure 130/72 mm Hg, weight 60 kg, and height 64 inches. Her head, eyes, ears, nose, and throat are unremarkable. Examination of the thyroid reveals a small goiter. Examination of her breasts reveals expressible galactorrhea without masses. Her lungs are clear. Her heart has a sinus rhythm without murmurs. There are no masses or organomegaly in the abdomen. The results of the neurologic examination are normal.

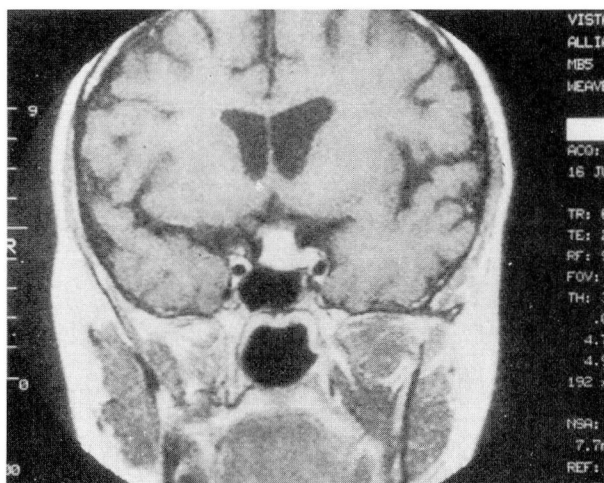
Q1 Which of the following batteries of tests is best to establish a diagnosis?

- Somatomedin C, prolactin, growth hormone
- Prolactin, computed tomography of the pituitary
- Prolactin, magnetic resonance imaging of the pituitary
- Beta human chorionic gonadotropin, thyroid-stimulating hormone, prolactin
- Prolactin, mammogram, visual field exam

A1 This patient must be screened with a prolactin measurement, as this hormone is the likely cause of her amenorrhea and galactorrhea. The physiologic role of prolactin is to stimulate lactation following delivery. At the time of nursing an infant

there are marked increases in serum prolactin levels. In fact, prolactin levels begin to go up during the course of pregnancy. The patient's amenorrhea may well be the result of a pregnancy, and her evaluation should include a pregnancy test (beta human chorionic gonadotropin). Other common causes of elevated prolactin levels in women include hypothyroidism and medications. Therefore, the fourth answer is correct.

The patient's beta human chorionic gonadotropin test was negative, her thyroid-stimulating hormone level was 35 μ U/mL (normal range 0.4 to 5.5 μ U/mL), and her prolactin level was 40 ng/mL (normal range 1.0 to 17.4 ng/mL). In addition, a magnetic resonance image was obtained and is shown in the *Figure*.



FIGURE

Q2 Based on the patient's symptoms and these findings, the most likely diagnosis is:

- Prolactinoma
- Primary hypothyroidism
- Pregnancy
- Carcinoma of the breast

A2 Both pregnancy and primary hypothyroidism may result in increased pituitary size as a result of increased trophic hormone production. Consequently, either a computed tomographic scan or

magnetic resonance image of the pituitary may show an abnormality suggesting a mass lesion in either of these circumstances. Although the patient's magnetic resonance image might lead one to believe she had a pituitary tumor, replacement therapy with levothyroxine resulted in resumption of menses, resolution of the galactorrhea, and a return of her pituitary size to normal. An elevated thyroid-stimulating hormone level is the best diagnostic test for primary hypothyroidism. Thyroid-stimulating hormone levels will revert to normal with thyroid hormone replacement therapy.

Discussion

The mechanism by which prolactin concentrations become elevated in primary hypothyroidism seems to be a combination of stimulation of prolactin secretion by the hypothalamic hormone TRH (thyrotropin-releasing hormone, which goes up in hypothyroidism), and, perhaps, diminished clearance of prolactin from the blood.

Another common cause of hyperprolactinemia is drug therapy. Common drugs include phenothiazines and dopamine antagonists such as metoclopramide. A careful history for medication use should be obtained in all patients with elevated prolactin levels.

Only when these common problems have been excluded should anatomic studies looking for a pi-

pituitary tumor (prolactinoma) be pursued. Galactorrhea without amenorrhea and with a normal prolactin concentration is not associated with any significant pathologic hormonal abnormality, and pituitary imaging is not warranted. Galactorrhea, with or without amenorrhea, may also be caused by breast manipulation, chest-wall trauma, or breast malignancies. These causes should be considered when other conditions cannot be found.

BYRON J. HOOGWERF, MD
LARRY M. KOHSE, MD
LESLIE R. SHEELER, MD
Department of Endocrinology
The Cleveland Clinic Foundation