



# The search for diagnostic criteria in Alzheimer's disease: an update

RICHARD A. PRAYSON, MD, AND MELINDA L. ESTES, MD

- **BACKGROUND** Although the pathologic findings in Alzheimer's disease are well documented, definitive diagnostic criteria are lacking.
- **OBJECTIVE** To review the histopathologic findings in Alzheimer's disease.
- **SUMMARY** In Alzheimer's disease, the brain may be normal in size or atrophic. There is selective neuronal loss associated with neurofibrillary tangles and senile plaques with amyloid deposits. Amyloid protein may also be deposited within arterioles. There may be granulovacuolar degeneration and Hirano bodies in the hippocampus. Two diagnostic schemes have been proposed based on the presence of senile plaques, but neither is entirely satisfactory.
- **CONCLUSIONS** The pathologic diagnosis is usually made in conjunction with the clinical history. Probably, neither definitive diagnostic criteria nor effective treatment for Alzheimer's disease will be possible until we understand more about its etiology. Clinicians should attempt to rule out other, potentially curable causes of dementia in elderly patients such as trauma, depression, metabolic abnormalities, infection, vascular disease, and other central nervous system diseases.

■ **INDEX TERMS:** ALZHEIMER'S DISEASE, PATHOLOGY; AMYLOID BETA-PROTEIN; NEUROFIBRILLARY TANGLES ■ CLEVE CLIN J MED 1994; 61:115-122

From the Department of Anatomic Pathology, The Cleveland Clinic Foundation.

Address reprint requests to M.L.E., Department of Anatomic Pathology, L25, The Cleveland Clinic Foundation, 9500 Euclid Avenue, Cleveland, OH 44195.

**A**LZHEIMER'S DISEASE is a progressive degenerative disorder of the central nervous system characterized by cognitive dysfunction, including disturbances of memory, judgment, and emotion. The disease usually culminates in an end-stage, severely debilitated state between 4 and 12 years after onset. It is the single most common cause of adult-onset dementia. Recent studies indicate that the lifetime incidence of Alzheimer's disease is roughly 25%.<sup>1</sup> Reported incidence rates have varied because most epidemiologic studies are based on a clinical diagnosis. Reported age-related prevalence rates vary and have ranged as high as 11.2%, although the actual prevalence is probably 2% to 6%.<sup>2-4</sup> The cost of caring for afflicted patients exceeds \$80 billion per year, and no effective treatment currently exists.<sup>5</sup> With the current trend of increasing life expectancy, the number of cases of Alzheimer's disease will probably increase over the next few decades.

In 1984, McKhann and coworkers, as part of the Department of Health and Human Services Task

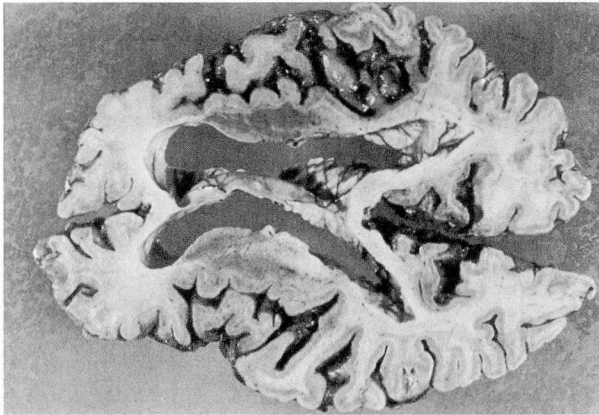


FIGURE 1. Computed tomographic plane section of brain showing prominent cortical atrophy with narrowing of gyri, widening of sulci, and ventricular dilatation.

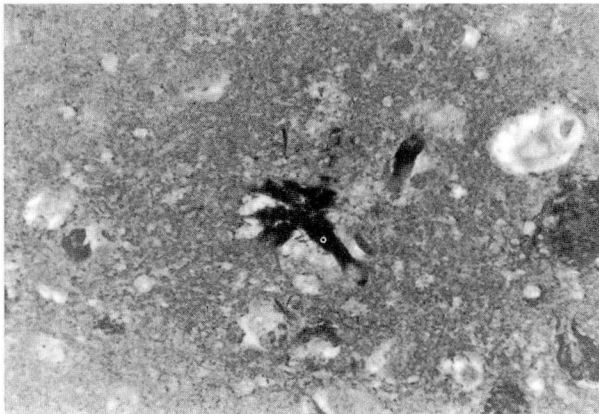

FIGURE 2. Neurofibrillary tangle composed of intracytoplasmic filaments within a pyramidal neuron (Bodian,  $\times 200$ ).

TABLE 1  
HISTOPATHOLOGIC FINDINGS  
IN ALZHEIMER'S DISEASE

Selective neuronal loss
Neurofibrillary tangles
Senile (neuritic) plaques
Classic
Primitive
Burnt-out (compact)
Granulovacuolar degeneration
Hirano bodies
Amyloid angiopathy

Force on Alzheimer's disease, published clinical criteria for diagnosing Alzheimer's disease.<sup>6</sup> Although a presumptive diagnosis can be made on clinical grounds, an unequivocal diagnosis requires pathological confirmation. Much of what we currently know about the disease comes from findings on autopsy, since there are no completely satisfactory animal models.<sup>7,8</sup> In 1907, Alois Alzheimer<sup>9</sup> took the first step in defining the disorder that would later bear his name by detailing the presence of senile plaques and neurofibrillary tangles in a woman with a 4-year history of progressive dementia.

#### PATHOLOGIC APPEARANCE

On gross examination, the brain in Alzheimer's disease may be normal or atrophic, weighing less than 1000 g (normal brains weigh 1200 to 1450 g).<sup>10</sup> Atrophy, when present, has a fronto-temporal predisposition and is usually symmetrical; however, parieto-occipital atrophy may predominate in some cases.<sup>10,11</sup> Cortical atrophy is manifested by narrowing of the gyri, widening of the sulci, and ventricular dilatation secondary to a loss of adjacent parenchyma (Figure 1). In addition, morphometric studies suggest an element of cerebral hemispheric collapse or contraction that occurs along with atrophy, since the degree of ventricular dilatation is more than would be expected from tissue loss alone.<sup>10,12</sup> The amount of atrophy may correspond to the histopathologic severity, ie, the number of senile plaques and neurofibrillary tangles.<sup>12</sup>

#### SELECTIVE NEURONAL LOSS

The histopathologic findings of Alzheimer's disease are summarized in Table 1. Neuronal loss, corresponding to atrophy in the frontal and temporal cortex, has been demonstrated in several studies.<sup>13-15</sup> From these studies, it appears that neuronal loss correlates with the severity of plaque and tangle formation. Little if any glial proliferation accompanies the neuronal loss. Interestingly, except in the anteromedial temporal lobe, neocortical neuronal loss is limited to patients younger than 80 years.

Consistent neuronal loss in Alzheimer's disease is observed in the hippocampus, amygdala, and subiculum. Various studies have attempted to measure the amount of neuronal loss; Herzog and Kemper found amygdaloid volume was reduced by 25% and amygdaloid neuronal density was reduced by up



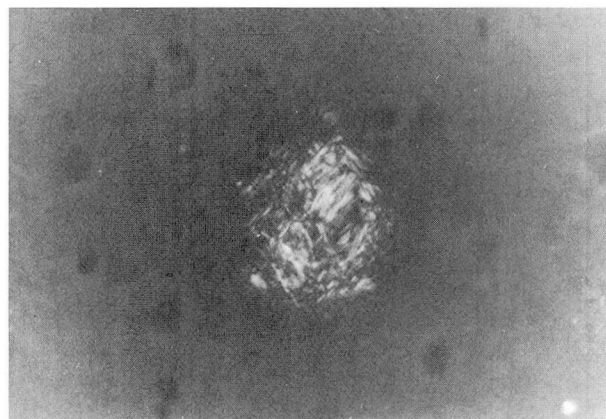
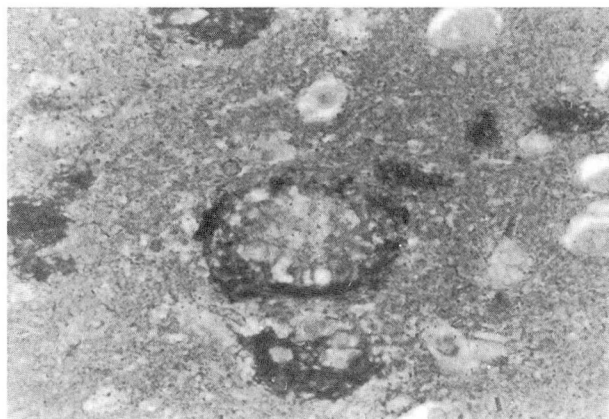


FIGURE 3. Several classic or typical senile plaques (left). Neuritic processes are highlighted with the silver stain (Bodian stain,  $\times 200$ ). At right, classic senile plaque stained with Congo red demonstrating green birefringence on polarization characteristic of amyloid deposition (Congo red,  $\times 200$ ).

to 50%, making the amygdala one of the most severely affected structures.<sup>16</sup>

It is well known that neurochemical abnormalities in Alzheimer's disease involve the cholinergic system.<sup>17,18</sup> Severe neuronal loss has been described in the nucleus basalis of Meynert (a cholinergic nucleus)<sup>19,20</sup> and the locus ceruleus (a noradrenergic nucleus).<sup>21,22</sup> Loss of neurons in these two locations is, in part, secondary to changes elsewhere in the brain. Loss of neurons in the serotonergic nucleus raphe dorsalis and the nucleus centralis superior is more variable and more prominent in younger patients.<sup>23</sup>

#### NEUROFIBRILLARY TANGLES

Neurofibrillary tangles are nonmembrane-bound masses of abnormal filaments that occupy a variable portion of the cytoplasm in medium-sized and large pyramidal cells of the hippocampus, cortical layers III and V, basal forebrain nuclei, and certain brain stem nuclei.<sup>24,25</sup> Neurofibrillary tangles are best seen using silver (Bielschowsky, Bodian), Congo red, or thioflavine S stains (Figure 2). Neuronal loss in some locations appears to be associated with the formation of neurofibrillary tangles. Electron-microscopic examination of the neurofibrillary tangles shows them to be composed of bundles of filaments twisted about each other in pairs.<sup>26,27</sup> Each filament is approximately 10 nm wide and twists around the adjacent filament, crossing over at 80-nm intervals.<sup>28</sup> Each has a substructure comprising four protofilaments of 3 to 5 nm. Neurofibrillary tangles also contain variable numbers of straight filaments with

diameters ranging from 10 to 20 nm.<sup>29</sup>

Recent work has uncovered abnormalities in the proteins associated with these filaments. The microtubule-associated tau protein promotes tubule stability and assembly and may play a role in maintaining neuronal polarity.<sup>30</sup> Abnormal phosphorylation of tau proteins to form protein A68 has been found in the neurofibrillary tangles of Alzheimer's disease.<sup>31</sup> Abnormalities in the tau protein may destabilize the microtubules and alter axonal function.

Aluminum has been reported to accumulate in neurons affected by neurofibrillary tangles and plaques in Alzheimer's disease.<sup>10,32</sup> Likewise, aluminum has been demonstrated in the neurons of patients with other neurodegenerative disorders such as amyotrophic lateral sclerosis and Parkinson-dementia complex.<sup>10,33</sup> In addition, animal studies have demonstrated that aluminum salts can produce neurofibrillary alterations. Exactly what role, if any, aluminum plays in Alzheimer's disease is unknown; it may represent a secondary phenomenon rather than a primary factor.

#### SENILE (NEURITIC) PLAQUES

Senile (neuritic) plaques are spherical structures measuring 5 to 200  $\mu\text{m}$  in diameter.<sup>10,28</sup> They were first described in 1892 by Blocq and Marinesco; the term "senile plaque" was applied by Simchowicz in 1911.<sup>10,28,34</sup> Senile plaques often lie near or contain a capillary as part of their structure. Plaques are composed of a heterogeneous mixture of degenerating neuronal processes (neurites), extracellular amyloid



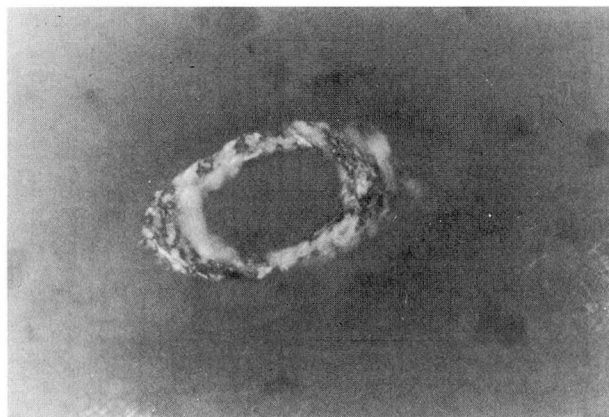


FIGURE 4. Small arteriole with amyloid angiopathy characterized by green birefringence on polarization (Congo red,  $\times 400$ ).

protein, microglia, and astrocytes (Figure 3).<sup>28</sup>

Three types of plaques have been described, differing in their morphology and relative proportion of components.<sup>35</sup> First are classic or typical plaques, which have a central compact amyloid core surrounded by a zone of swollen neurites and amyloid fibrils. When stained with silver, a dark central core is seen surrounded by an irregular clear halo and a ring of filamentous or granular structures. Astrocyte processes and occasional microglial cells are present at the periphery. Second are primitive plaques, which are composed of scattered clusters or fibrils of amyloid intermixed with swollen neurites. Microscopically, primitive plaques appear as small (up to 5- $\mu$ m) areas of granularity in the neuropil. Third are burnt-out or compact plaques consisting of stellate amyloid deposits with few or no neurites.

Much has been written about the amyloid deposits seen within the plaque cores. Amyloid protein consists of collections of 6- to 10-nm fibrils that can be visualized with a variety of stains including Congo red, periodic acid-Schiff, thioflavine S, and crystal violet. The birefringence of amyloid deposits is related to a beta-pleated sheet arrangement of its subunits.<sup>36</sup> Purification of amyloid from senile plaque cores yields a 4.2-kd subunit referred to as "beta-amyloid" or "A4 protein," which is derived from larger precursor proteins (amyloid precursor protein [APP]) encoded by a gene on chromosome 21.<sup>5,37-42</sup>

The metabolism of APP is complex and not completely understood.<sup>35</sup> The best understood pathway involves cleavage of APP by alpha-secretase, which does not generally result in beta-amyloid formation.

Another pathway (endosomal-lysosomal) involves cleavage near the N-terminal of beta-amyloid, yielding C-terminal derivatives that are potentially amyloidogenic. Presumably, mutations in the APP gene affect phenotype by increasing the rate of beta-amyloid deposition. Research is continuing in this area in an attempt to fully understand the role of amyloid in Alzheimer's disease.

Linkage of the amyloid abnormality in Alzheimer's disease with a chromosomal locus has helped to explain the increased beta-amyloid deposits in patients who have increased numbers of certain loci on chromosome 21 (ie, trisomy 21 or Down's syndrome). Individuals older than 40 years with Down's syndrome frequently develop pathologic changes very similar to those seen in Alzheimer's disease.<sup>43,44</sup> In addition, several large families with multiple members afflicted with Alzheimer's disease have been described that demonstrate an autosomal dominant pattern of inheritance.<sup>45</sup> The only apparent differences between these patients and "sporadic" cases is the younger age of presentation. Gene mapping studies have localized the defect to chromosome 21 (21q11.2-21q22.3 region).<sup>45</sup> This has prompted some to suggest that Alzheimer's disease may be related to an incompletely penetrant gene on chromosome 21.<sup>45</sup>

The presence of amyloid plaques in mice infected with scrapie (a slow viral infection of sheep) raises the question of whether Alzheimer's disease may be related to or caused by an infectious agent.<sup>46</sup> Repeated failure in transmitting the disease provides strong evidence against an infectious cause.<sup>10</sup>

#### AMYLOID ANGIOPATHY

Some degree of amyloid deposition within cerebral vessels, particularly arterioles and small arteries within the cortex or leptomeninges, is present in most cases of Alzheimer's disease (Figure 4).<sup>28,47</sup> The same beta-amyloid found in senile plaques has also been discovered to be the main component in amyloid angiopathy, thus suggesting that the two processes are pathogenetically related.<sup>28,42,48</sup> Masters and coworkers<sup>49</sup> have suggested that the amyloid found both in plaques and within vessels is of neuronal origin, with plaque-related amyloid deposition occurring earlier and vessel-associated deposition occurring later. An alternate hypothesis suggests that a common precursor for amyloid may be blood-derived, possibly related to disruptions in the blood-



brain barrier.<sup>47</sup> Histologically, an amorphous, acellular thickening of the vessel wall can be seen.<sup>50</sup>

Not all patients with amyloid angiopathy suffer from Alzheimer's disease. In fact, only about 40% of these patients have associated dementia.<sup>50</sup> A group of patients clearly develops amyloid angiopathy in the setting of hypertension and is predisposed to intracerebral hemorrhage.<sup>10,51-53</sup> These cerebral hemorrhages are often multiple and large with a predilection for the frontal and temporal lobes, a distribution that differs from the typical basal ganglial hemorrhages related to hypertension.<sup>50,53-56</sup> Interestingly, patients with Alzheimer's disease and amyloid angiopathy do not have as high a rate of massive intracerebral hemorrhages as one might expect. Whether amyloid angiopathy in the two situations shares a similar pathogenesis is a matter of debate.

#### GRANULOVACUOLAR DEGENERATION

Granulovacuolar degeneration in the hippocampus of a demented patient was first described by Simchowicz in 1911.<sup>34</sup> The process is confined primarily to the large pyramidal neurons of the hippocampus. Microscopically, the lesion appears as simple or multiple vacuoles measuring 3 to 5  $\mu\text{m}$  in diameter that contain a central granule measuring 0.5  $\mu\text{m}$  in diameter (Figure 5).<sup>10,28</sup> They may coexist in the same neuron with neurofibrillary tangles. Ultrastructurally, they appear as cytoplasmic membrane-bound inclusions with an electron-dense granular core.<sup>57</sup> The rarity of these vacuoles outside the hippocampus suggests they may not play a major role in the pathogenesis of Alzheimer's disease. The granules have been shown to have tubulin-like reactivity on immunohistochemical staining.<sup>58</sup> In addition, the granules also stain with monoclonal antibodies to the tau protein and to ubiquitin, a protein related to the nonlysosomal breakdown of certain proteins.<sup>59,60</sup> These findings suggest that granulovacuolar degeneration may represent a degenerative autophagocytic process involving normal or abnormal cytoskeleton proteins.<sup>10</sup>

#### HIRANO BODIES

Hirano bodies are rodlike or oval eosinophilic structures located within neuronal cell processes or adjacent to the nucleus in pyramidal cells of the hippocampus.<sup>10,28</sup> The inclusions measure 10 to 30  $\mu\text{m}$  in length and 8  $\mu\text{m}$  in width. They were first

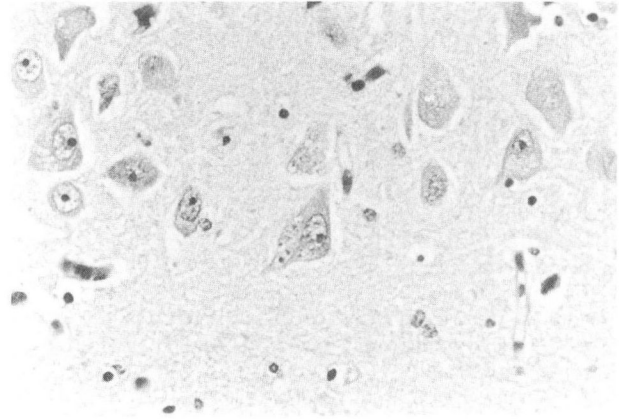


FIGURE 5. Granulovacuolar degeneration in hippocampal neurons seen as multiple clear vacuoles containing a central granule (hematoxylin-eosin,  $\times 200$ ).

described by Hirano and coworkers in 1966 in patients with the Parkinson-dementia complex of Guam.<sup>61</sup> Not until 11 years later was their presence in patients with Alzheimer's disease recognized.<sup>62</sup>

Their ultrastructure consists of parallel arrangements of filaments 60 to 100 nm long, which alternate with a latticelike configuration.<sup>63,64</sup> Immunohistochemical studies have demonstrated reactivity with actin and actin-associated proteins (tropomyosin, alpha-actinin, and vinculin).<sup>65,66</sup> Additionally, reactivity with antibodies to the tau protein has been reported.<sup>67</sup> Exactly what Hirano bodies represent is uncertain; however, given their immunoreactivity, they may represent abnormal microfilament configurations.

#### PATHOLOGIC DIAGNOSIS OF ALZHEIMER'S DISEASE

Although the pathologic findings in Alzheimer's disease have been well documented, the debate over histopathologic diagnostic criteria continues.<sup>68</sup> Findings from a 1984 consensus workshop including minimal microscopic criteria for diagnosing Alzheimer's disease were published by Khachaturian.<sup>33</sup> In this scheme, the diagnosis depends on an age-related minimum number of senile plaques per microscopic field of neocortex encompassing 1  $\text{mm}^2$  at a suggested microscopic magnification of  $200\times$ .<sup>33</sup>

There are several problems with this approach, including the arbitrary quantitative criteria selected, failure to account for variation in staining techniques among laboratories, differences in interpretation among pathologists, and the impracticality of

**TABLE 2**  
A CLINICOPATHOLOGIC DIFFERENTIAL  
DIAGNOSIS FOR ALZHEIMER'S DISEASE

---

Pick's disease
Cerebral vascular diseases
Multi-infarct dementia
Binswanger's disease
Congophilic angiopathy
Subcortical degeneration
Parkinson's disease
Huntington's disease
Progressive supranuclear palsy
Multisystem atrophy
Infections or inflammatory diseases
Syphilis
Slow virus diseases (Creutzfeldt-Jakob Disease)
Encephalitis
Human immunodeficiency virus infection
Multiple sclerosis
Progressive multifocal leukoencephalopathy
Toxic or metabolic diseases
Tumors (primary or secondary)
Hydrocephalus
Injury or trauma

---

counting plaques in a 1 mm<sup>2</sup> area at 200 × magnification. Studies have shown substantial variation in counts of senile plaques and neurofibrillary tangles among different laboratories.<sup>69</sup> Particular problems arise when trying to apply criteria in atypical cases. For example, what diagnosis should be rendered if the pathologic findings are typical for Alzheimer's disease but if no clinical history is available or if the patient has demonstrated no evidence of dementia?<sup>70</sup> Additional problems are encountered when the clinical presentation is atypical or overlaps with other neurodegenerative disorders. All of the histopathologic findings in Alzheimer's disease have been reported to occur in "normal" aging brains as well as in a host of pathologic entities, many of which can also cause dementia (Table 2).<sup>10</sup> Of recent note is the recognition of Alzheimer-like changes in a subset of patients with Parkinson's disease.<sup>71</sup> What exactly constitutes "normal" in an aging brain, particularly in the absence of clinical evidence of dementia, is still a matter of debate. Generally, the pathologic findings associated with Alzheimer's disease are more frequent and numerous in patients with Alzheimer's disease than in normal age-matched controls.<sup>10</sup> However, there are clearly reports of "normal" patients who have plaque counts

that constitute Alzheimer's disease by Khachaturian's criteria.

Semiquantitative approaches to diagnosing Alzheimer's disease have also been attempted. One such approach, developed by the Consortium to Establish a Registry for Alzheimer's Disease, involved an age-related plaque score based on a semiquantitative assessment of plaque frequency correlated with the patient's age.<sup>72</sup> Using the age-related plaque score and clinical history, one can generate a level of certainty in diagnosing Alzheimer's disease. However, there are shortcomings to this approach: it does not address issues of staining standardization and variations in interobserver interpretation. One may also argue against using senile plaques as the sole histopathologic criteria for diagnosing Alzheimer's disease.

Despite the shortcomings of semiquantitative approaches to diagnosing Alzheimer's disease, they are still useful in corroborating the diagnosis in difficult cases. Fortunately, the diagnosis in a majority of cases of Alzheimer's disease encountered at autopsy is straightforward, if clinical findings, history, and pathologic findings are considered. It is important to assess the clinical history to rule out other potentially treatable causes of dementia such as trauma, depression, metabolic abnormalities, infection, vascular disease, and other central nervous system diseases. Careful gross examination of the brain, paying particular attention to the presence of atrophy and its distribution and to evidence of multiple infarcts, may be helpful in excluding Pick's disease (marked frontal or temporal atrophy) and multi-infarct dementia. Microscopic examination of "high-yield" areas of the brain including the hippocampus, inferior parietal lobule, middle frontal gyrus, and nucleus basalis of Meynert is more likely to demonstrate the pathologic features of Alzheimer's disease. Careful microscopic examination must be done, specifically looking for histologic features that suggest other causes of dementia, eg, spongiform change of Creutzfeldt-Jakob disease, inflammation, demyelination, or tumors.

---

#### SUMMARY

---

Although much is known about the histopathologic findings of Alzheimer's disease, definitive criteria for its diagnosis are still lacking. Recent advances, particularly in the molecular biologic aspects of the disease, have suggested possible patho-



genetic mechanisms. Only with an understanding of the etiology can an early and accurate diagnosis of Alzheimer's disease be made and potentially effective treatment modalities be developed.

## REFERENCES

- Hagnell O, Ojesjo L, Roisman B. Incidence of dementia in the Lundby study. *Neuroepidemiology* 1992; 11(Suppl 1):61-66.
- Evans DA, Funkenstein HH, Albert MS, et al. Prevalence of Alzheimer's disease in a community population of older persons; higher than previously reported. *JAMA* 1989; 262:2551-2556.
- Rocca WA, Amaducci LA, Schoenberg BS. Epidemiology of clinically-diagnosed Alzheimer's disease. *Ann Neurol* 1986; 19:415-424.
- Pfeffer RI, Afifi AA, Chanca JM. Prevalence of Alzheimer's disease in a retirement community. *Am J Epidemiol* 1987; 125:420-436.
- Selkoe DJ. Amyloid protein and Alzheimer's disease. *Sci Am* 1991; 265:68-78.
- McKhann G, Drachman D, Folstein M, Katzman R, Price D, Stadlan EM. Clinical diagnosis of Alzheimer's disease: report of the NINCDS-ADRDA Work Group under the auspices of the Department of Health and Human Services Task Force on Alzheimer's disease. *Neurology* 1984; 34:939-944.
- Merlino GT. Transgenic animals in biomedical research. *FASEB J* 1991; 5:2996-3001.
- Price DL, Martin LJ, Sisodia SS, et al. Aged non-human primates: an animal model of age-associated neurodegenerative disease. *Brain Pathology* 1991; 1:287-296.
- Alzheimer A. Über eine eigenartige Erkrankung der Hirnrinde. *Zentralblatt für Nervenheilkunde Psychiatrie* 1907; 18:177-179.
- Tomlinson BE. Aging and the dementias. In: Adams JH, DuChen LW, editors. *Greenfield's Neuropathology*. New York, New York: Oxford University Press, 1992:1284-1410.
- Brün A, Englund E. Regional pattern of degeneration in Alzheimer's disease: neuronal loss and histopathological grading. *Histopathology* 1981; 5:549-564.
- de la Monte SM. Quantitation of cerebral atrophy in preclinical and end-stage Alzheimer's disease. *Ann Neurol* 1989; 25:450-459.
- Terry RD, DeTeresa R, Hansen LA. Neocortical cell counts in normal human adult aging. *Ann Neurol* 1987; 21:530-539.
- Hubbard BM, Anderson JM. Age related variations in the neuron content of the cerebral cortex in senile dementia of the Alzheimer type. *Neuropathol Appl Neurobiol* 1985; 11:369-382.
- Mann DMA, Yates PO, Marcyniuk B. Some morphometric observations on the cerebral cortex and hippocampus in presenile Alzheimer's disease, senile dementia of Alzheimer type and Down's syndrome in middle age. *J Neurol Sci* 1985; 69:139-159.
- Herzog AG, Kemper TL. Amygdaloid change in aging and dementia. *Arch Neurol* 1980; 37:625-629.
- Boven DM, Smith CB, White P, Davison AN. Neurotransmitter-related enzymes and indices of hypoxia in senile dementia and other abiotrophies. *Brain* 1976; 99:459-496.
- Perry EK, Perry RH, Blessed G, Tomlinson BE. Neurotransmitter enzyme abnormalities in senile dementia-choline acetyltransferase and glutamic acid decarboxylase necropsy brain tissue. *J Neurol Sci* 1977; 34:247-265.
- Arendt T, Bigl V, Arendt A, Tennstedt A. Loss of neurons in the nucleus basalis of Meynert in Alzheimer's disease, paralysis agitans and Korsakoff's disease. *Acta Neuropathologica* 1983; 61:101-108.
- Whitehouse PJ, Price DL, Clark AW, Coyle JT, DeLong MR. Alzheimer disease: evidence for selective loss of cholinergic neurons in the nucleus basalis. *Ann Neurol* 1981; 10:122-126.
- Tomlinson BE, Irving D, Blessed G. Cell loss in the locus ceruleus in senile dementia of Alzheimer type. *J Neurol Sci* 1981; 49:419-428.
- Bondareff W, Mountjoy CJ, Roth M. Loss of neurons of origin of the adrenergic projection to cerebral cortex (nucleus locus ceruleus) in senile dementia. *Neurology* 1982; 32:164-168.
- Mann DMA, Yates PO, Marcyniuk B. Monaminergic transmitters in presenile Alzheimer's disease and in presenile dementia of Alzheimer type. *Clin Neuropathol* 1984; 3:199-205.
- Hirano A, Zimmerman HM. Alzheimer's neurofibrillary change: a topographic study. *Arch Neurol* 1962; 7:73-88.
- Curcio CA, Kamper T. Nucleus dorsalis in dementia of the Alzheimer type: neurofibrillary changes and neuronal packing density. *J Neuropathol Exp Neurol* 1984; 43:359-368.
- Kidd M. Paired helical filaments in electron microscopy of Alzheimer's disease. *Nature* 1963; 197:192-193.
- Kidd M. Alzheimer's disease—an electron microscopic study. *Brain* 1964; 87:307-321.
- Probst A, Langui D, Ulrich J. Alzheimer's disease: a description of the structural lesions. *Brain Pathol* 1991; 1:229-239.
- Yagashita ST, Itoh T, Nan W, Amano N. Re-appraisal of the fine structure of Alzheimer's neurofibrillary tangles. *Acta Neuropathologica* 1981; 54:239-246.
- Lee VM-Y, Balin BJ, Otvos L Jr, Trojanowski JQ. A68:A major subunit of paired helical filaments and derivatized forms of normal tau. *Science* 1991; 251:675-678.
- Goedert M, Spillantini MG, Cairns NJ, Crowther RA. Tau-proteins of Alzheimer paired helical filaments—abnormal phosphorylation of all six brain isoforms. *Neuron* 1992; 8:159-168.
- Crapper DR, Krishnan SS, Quittkat S. Aluminum, neurofibrillary degeneration and Alzheimer's disease. *Brain* 1976; 99:67-80.
- Khachaturian ZS. Diagnosis of Alzheimer's disease. *Arch Neurol* 1985; 42:1097-1105.
- Simchowicz T, Nissl F, Alzheimer A. Histologische studien über die senile demenz. *Histologische und Histopathologische Arbeiten* 1911; 4:267-444.
- Terry RD, Wisniewski HH. The ultrastructure of the neurofibrillary tangle and senile plaque. In: Wolstenholme GEW, O'Connor M, editors. *Alzheimer's disease and related conditions*. Ciba Foundation Symposium. London: J & A Churchill, 1990:145-168.
- Glenner GG. Amyloid deposits and amyloidosis: the -fibrilloses. *N Engl J Med* 1980; 302:1283-1292.
- Glenner GG, Wong CW. Alzheimer's disease: initial report of the purification and characterization of a novel cerebrovascular amyloid protein. *Biochem Biophys Res Commun* 1984; 120:885-890.
- Selkoe DJ, Abraham CR, Podlisny MB, Duffy LK. Isolation of low-molecular-weight proteins from amyloid plaque fibers in Alzheimer's disease. *J Neurochem* 1986; 146:1820-1834.
- Younkin SG. Processing of the Alzheimer's disease A4 amyloid protein precursor (APP). *Brain Pathol* 1991; 1:253-262.
- Goldgaber D, Lerman MI, McBride OW, Saffiotti U, Gajdusek DC. Characterization and chromosomal localization of a cDNA encoding brain amyloid of Alzheimer's disease. *Science* 1987; 235:877-880.
- Tanzi RE, Gusella JF, Watkins PC, et al. Amyloid -protein gene: cDNA, mRNA distribution and genetic linkage near the Alzheimer locus. *Science* 1987; 235:880-884.
- Robakis NK, Wisniewski HM, Jenkins EC, et al. Chromosome 21q21 sublocalization of gene encoding beta-amyloid peptide in cerebral vessels and neuritic (senile) plaques of people with Alzheimer's disease and Down syndrome. *Lancet* 1987; 1:384-385.

## ACKNOWLEDGMENT

Special thanks to Alice J. Kiffer for her help in preparing the manuscript and to Mark J. Melaragno, MD for reviewing the manuscript.

43. Ropper AH, Williams RS. Relationships between plaques, tangles and dementia in Down syndrome. *Neurology* 1980; 30:639-644.
44. Mann DMA, Yates PO, Marcyniuk B, Ravinda CR. The topography of plaques and tangles in Down's syndrome patients of different ages. *Neuropathol Appl Neurobiol* 1986; 12:447-457.
45. St George-Hyslop PH, Tanzi RE, Polinsky RJ, et al. The genetic defect causing familial Alzheimer's disease map on chromosome 21. *Science* 1987; 235:885-890.
46. Bruce ME, Dickinson AG, Fraser H. Cerebral amyloidosis in scrapie in the mouse: effect of agent strain and mouse genotype. *Neuropathol Appl Neurobiol* 1976; 2:471-478.
47. Glenner GG, Henry JH, Fujihara S. Congophilic angiopathy in the pathogenesis of Alzheimer's degeneration. *Ann Pathol* 1981; 1:120-129.
48. Glenner GG, Wong CW. Alzheimer's disease and Down's syndrome: sharing a unique cerebrovascular amyloid fibril protein. *Biochem Biophys Res Commun* 1984; 122:1131-1135.
49. Masters CL, Multhaup G, Simms G, et al. Neuronal origin of a cerebral amyloid: neurofibrillary tangles of Alzheimer's disease contain the same protein as the amyloid of plaque cores and blood vessels. *EMBO J* 1988; 4:2757-2763.
50. Vinters HV. Cerebral amyloid angiopathy. A critical review. *Stroke* 1987; 18:311-324.
51. Ojemann RG, Heros RC. Spontaneous brain hemorrhage. *Stroke* 1983; 14:458-475.
52. Cosgrove GR, Leblanc R, Meagher-Villemure K, Ethier R. Cerebral amyloid angiopathy. *Neurology* 1985; 35:625-631.
53. Gilles C, Brucher JM, Khoubessenen P, Vanderhaeghen JJ. Cerebral amyloid angiopathy as a cause of multiple intracerebral hemorrhages. *Neurology* 1984; 34:730-735.
54. Ishii N, Nishibara Y, Horie A. Amyloid angiopathy and lobar cerebral haemorrhage. *J Neurol Neurosurg Psychiatry* 1984; 47:1203-1210.
55. Mandybur TI. Cerebral amyloid angiopathy: the vascular pathology and complications. *J Neuropathol Exp Neurol* 1986; 45:79-90.
56. Vinters HV, Gilbert JJ. Cerebral amyloid angiopathy: incidence and complications in the aging brain. II. The distribution of amyloid vascular changes. *Stroke* 1983; 14:924-928.
57. Hirano A, Dembeter HM, Kurland LT, Zimmerman HM. The fine structure of some intraganglionic alterations. *J Neuropathol Exp Neurol* 1968; 27:167-182.
58. Price DL, Altschuler RJ, Stuble RG, Casanova ME, Cork ME. Sequestration of tubulin in neurons in Alzheimer's disease. *Brain Res* 1986; 385:305-310.
59. Dickson DW, Koziek-Redding H, Davies P, Yen SH. A monoclonal antibody that recognizes a phosphorylated epitope in Alzheimer neurofibrillary tangles, neurofilaments and tau proteins immunostains granulovacuolar degeneration. *Acta Neuropathologica* 1985; 73:254-258.
60. Leigh PN, Probst A, Dale GE, et al. New aspects of the pathology of neurodegenerative disorders as revealed by ubiquitin antibodies. *Acta Neuropathol* 1989; 79:61-72.
61. Hirano A, Malamud N, Elizan TS, Kurland LT. Amyotrophic lateral sclerosis and Parkinsonism-dementia complex on Guam. *Arch Neurol* 1966; 15:35-51.
62. Gibson P, Tomlinson BE. The numbers of Hirano bodies in the hippocampus of normal and demented subjects with Alzheimer's disease. *J Neurol Sci* 1977; 33:199-206.
63. Tomonaga M. Ultrastructure of Hirano bodies. *Acta Neuropathologica* 1974; 28:365-366.
64. Schochet SS, McCormick WF. Ultrastructure of Hirano bodies. *Acta Neuropathologica* 1972; 21:50-60.
65. Goldman JE. The association of actin with Hirano bodies. *J Neuropathol Exp Neurol* 1983; 42:146-152.
66. Galloway PG, Perry G, Gambetti P. Hirano body filaments contain actin and actin associated proteins. *J Neuropathol Exp Neurol* 1987; 46:185-199.
67. Galloway PG, Perry G, Kosik KS, Gambetti P. Hirano bodies contain tau protein. *Brain Res* 1987; 403:337-340.
68. Mirra SS, Hart MN, Terry RD. Making the diagnosis of Alzheimer's disease. A primer for practicing pathologists. *Arch Pathol Lab Med* 1993; 117:132-144.
69. Mirra SS, McKeel D, Crain BJ, et al. Quality assurance (QA) in the neuropathology assessment of Alzheimer's disease (AD): a multicenter study of the consortium to establish a registry for Alzheimer's disease (CERAD). *J Neuropathol Exp Neurol* 1990; 49:336.
70. Katzman R, Terry RD, DeTeresa R, et al. Clinical, pathological and neurochemical changes in dementia: a subgroup with preserved mental status and numerous neocortical plaques. *Ann Neurol* 1988; 23:138-144.
71. Hughes AJ, Daniel SE, Blankson S, Lees AJ. A clinicopathologic study of 100 cases of Parkinson's disease. *Arch Neurol* 1993; 50:140-148.
72. Mirra SS, Heyman A, McKeel D, et al. The consortium to establish a registry for Alzheimer's disease (CERAD). Part II. Standardization of the neuropathologic assessment of Alzheimer's disease. *Neurology* 1991; 41:479-486.



To earn CME Category I credit, see test on p. 161