



# Right pleural effusion due to a migrating ventriculoperitoneal shunt

DAVID P. MEEKER, MD, AND GENE H. BARNETT, MD

- **BACKGROUND** Pseudotumor cerebri or benign intracranial hypertension is a collection of disorders characterized by papilledema and increased intracranial pressure without associated neurologic abnormalities and wherein the cerebrospinal fluid composition is normal. Therapy may consist of diuretics, acetazolamide, and, in more severe cases, ventricular shunts.
- **SUMMARY** A patient with pseudotumor cerebri and a ventriculoperitoneal shunt presented with dyspnea early in her pregnancy. Chest roentgenography revealed a right pleural effusion and a shunt catheter in the right pleural space. The patient underwent four thoracenteses, and a new shunt was placed after the baby was born.
- **CONCLUSIONS** Physicians should recognize the potential for a ventriculoperitoneal shunt to migrate from the peritoneum to the pleural space. In a pregnant patient, it is reasonable to perform serial thoracenteses as a temporizing measure, and the shunt can be definitively revised in an elective surgical procedure postpartum.

■ **INDEX TERMS:** PSEUDOTUMOR CEREBRI; VENTRICULOPERITONEAL SHUNT; PLEURAL EFFUSION; PREGNANCY ■ *CLEVE CLIN J MED* 1994; 61:144-146

From the Departments of Pulmonary and Critical Care Medicine (D.P.M.) and Neurological Surgery (G.H.B.), The Cleveland Clinic Foundation.

Address reprint requests to D.P.M., Department of Pulmonary and Critical Care Medicine, A90, The Cleveland Clinic Foundation, 9500 Euclid Avenue, Cleveland, OH 44195.

**P**SEUDOTUMOR cerebri or benign intracranial hypertension is a collection of disorders characterized by papilledema and increased intracranial pressure without associated neurologic abnormalities and in which the composition of the cerebrospinal fluid is normal.<sup>1</sup> Therapy is similar to that for hydrocephalus, consisting of diuretics, acetazolamide, and, in more severe cases, ventricular shunts. We report the development of a right pleural effusion caused by migration of a ventriculoperitoneal shunt into the pleural space in a pregnant woman.

## CASE HISTORY

A 29-year-old white woman, gravida 4 para 3, complained of a 2-week history of increased shortness of breath. Pseudotumor cerebri had developed after a motor vehicle accident with associated head trauma when the patient was 5 years old. She had been treated initially with a ventriculoatrial shunt, which was subsequently converted to a ventriculoperitoneal shunt. The

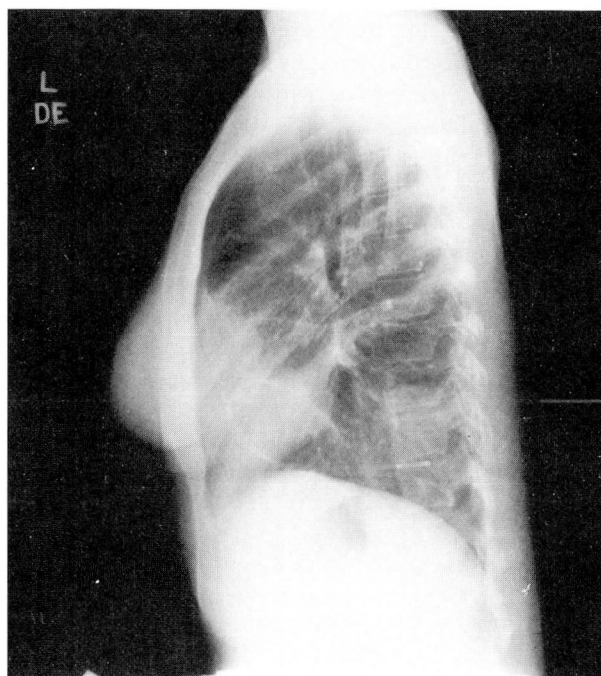
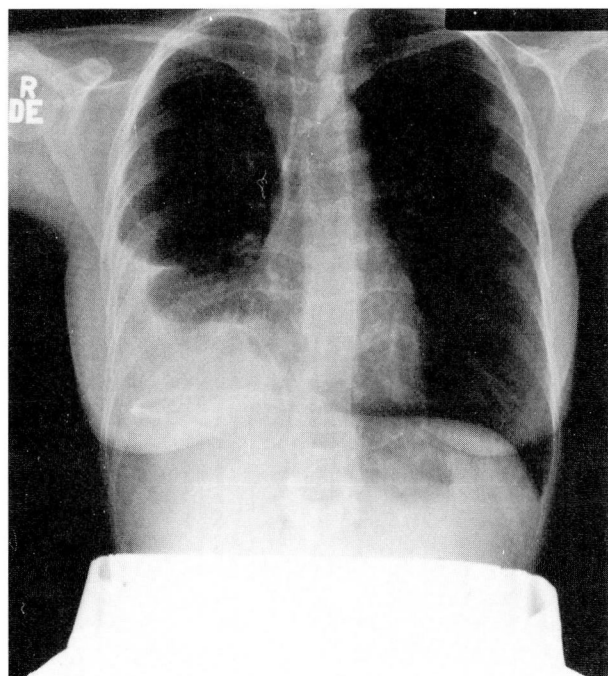


FIGURE. Posterior-anterior and lateral roentgenogram of the chest demonstrating a right pleural effusion and the catheter in the right pleural space.

operative note described passage of a subcutaneous tunneling device from the neck incision over the mastoid through the neck, below the clavicle, under the right breast, over the rib cage, and down to a right upper-quadrant incision. A Holter-Salmon catheter had then been passed from the neck incision to the right upper quadrant. The distal tip of the catheter had then been passed intraperitoneally using an abdominal trocar to perforate the peritoneum, and the tubing had been fed into the peritoneum. An anteroposterior roentgenogram taken immediately after surgery had revealed a "25% right pneumothorax and a long shunt tube superimposed on the right side of the thorax and abdomen." This film was no longer available.

Her physical examination revealed findings consistent with a right pleural effusion. A posterior-anterior and lateral roentgenogram (*Figure*) showed the shunt catheter in the right pleural space and a moderate-sized right pleural effusion. The patient underwent four thoracenteses in which a total of 4725 mL of fluid was drained, and she subsequently had an uncomplicated vaginal delivery. The shunt was removed 2 months postpartum, and a new ventriculoperitoneal shunt was placed.

#### DISCUSSION

Migration of a ventriculoperitoneal shunt into the right pleural cavity was previously reported by Cooper,<sup>2</sup> who suggested the catheter entered the pleural cavity along the right xiphocostal margin where the superior epigastric vessels perforate the diaphragm. The diaphragmatic defect is exposed during dissection beneath the rectus abdominis muscle and may permit the catheter to migrate into the chest. In our patient, the presence of a pneumothorax immediately after the shunt was placed in 1972 suggests the catheter may have been tunneled through the pleural cavity en route to the peritoneum and had subsequently migrated back into the pleural space.

Two possible scenarios may explain the onset of shortness of breath with her pregnancy. The catheter may have coincidentally migrated into the pleural space during pregnancy while the amount of cerebrospinal-fluid drainage remained constant. Alternatively, the catheter may have migrated earlier, and pregnancy may have caused the volume of cerebrospinal-fluid drainage to increase, leading to pleural-fluid accumulation. However, despite case

reports of pseudotumor cerebri developing with or worsening during pregnancy,<sup>1,3</sup> a case-control study of 40 patients and 35 control subjects did not confirm this relationship.<sup>4</sup> Whether pregnancy contributed to increased drainage of cerebrospinal fluid into the pleural space in our patient cannot be ascertained from the available data.

In summary, this is an unusual cause for a pleural effusion. Physicians should be aware of the potential for a ventriculoperitoneal shunt to migrate from the peritoneum to the pleural space. In a pregnant patient, serial thoracenteses are a reasonable temporiz-

ing measure, and the shunt can be definitively revised in an elective surgical procedure postpartum.

# REFERENCES

1. Sorensen PS, Krogsaa B, Gjerris F. Clinical course and prognosis of pseudotumor cerebri. A prospective study of 24 patients. *Acta Neurol Scand* 1988; **77**:164-172.
2. Cooper JR. Migration of ventriculoperitoneal shunt into the chest. *J Neurosurg* 1978; **48**:146-147.
3. Koontz WL, Herbert WNP, Cefalo RC. Pseudotumor cerebri in pregnancy. *Obstet Gynecol* 1983; **62**:324-327.
4. Ireland B, Corbett JJ, Wallace RB. The search for causes of idiopathic intracranial hypertension: a preliminary case-control study. *Arch Neurol* 1990; **47**:315-320.

