



JAMES THOMAS, MD, EDITOR

## Transesophageal echocardiography: why and when to use it

ANTHONY DEMARIA, MD; ALLAN KLEIN, MD; GUIDO BELLI, MD; KINGSLEY ANNAN, MD; JAMES THOMAS, MD;

**T**his discussion focuses on a health care utilization issue: exactly when and why should transesophageal echocardiography (TEE) be used? Several clinical situations will be discussed by Anthony DeMaria, MD, Chief of Cardiology, University of California at San Diego, and Allan Klein, MD, Director of Cardiovascular Imaging Research, Cleveland Clinic. They bring views on this issue that are both contrasting and concordant. Also taking part in the discussion are James Thomas, MD, Director of Cardiovascular Imaging, Cleveland Clinic, and Guido Belli, MD and Kingsley Annan, MD, first-year cardiology fellows.

---

### CASE 1: TEE FOR CARIOVERSION IN ATRIAL FIBRILLATION

---

**DR. KLEIN:** The first case is a 44-year-old man with hypertrophic cardiomyopathy who had undergone myectomy approximately 6 months before pre-

senting to the Cleveland Clinic in atrial fibrillation. He was scheduled for cardioversion and underwent transthoracic echocardiography, which showed a very thick-walled ventricle, a small cavity, and the myectomy site. The left atrium was enlarged and no thrombus was noted (*Figure 1*). Because the patient had a history of embolism, we decided to perform TEE before cardioversion and saw a thrombus in the left atrial appendage, with severe spontaneous echocardiographic contrast ("smoke") in the left atrial cavity as well as in the appendage (*Figure 2*). This was seen despite the patient's long-term warfarin therapy, with a prothrombin time of 16 seconds. The cardioversion was canceled, rate control was initiated, and he was admitted to the hospital.

The patient received an intensive regimen of intravenous heparin; several days later, repeat TEE showed a much smaller thrombus in the left atrial appendage, though still with severe smoke. The patient was discharged with an increased dose of warfarin. Follow-up TEE 2 months later demonstrated no thrombus, after which he underwent successful cardioversion without embolus (*Figure 2*).

**DR. THOMAS:** Obviously, Dr. Klein sees the utility of TEE before cardioversion. Dr. DeMaria, what are your views on this, first in this patient, then in patients in general undergoing cardioversion?

**DR. DEMARIA:** Basically, I like TEE before cardioversion, mainly to decrease the duration of anticoagulation. The alternative is to treat the patient in atrial fibrillation with warfarin for 3 weeks,

---

From the Department of Cardiology, University of California at San Diego (A.D.) and the Department of Cardiology, The Cleveland Clinic Foundation (A.K., G.B., K.A., J.T.).

Address reprint requests to A.K., Department of Cardiology, F15, The Cleveland Clinic Foundation, 9500 Euclid Avenue, Cleveland, OH 44195.

This series is based on the Cleveland Clinic Heart Center's "Controversies in Cardiology" conferences, at which a visiting clinician-professor and a Cleveland Clinic Heart Center clinician give contrasting perspectives on the application of current technology or the management of cardiologic diseases.

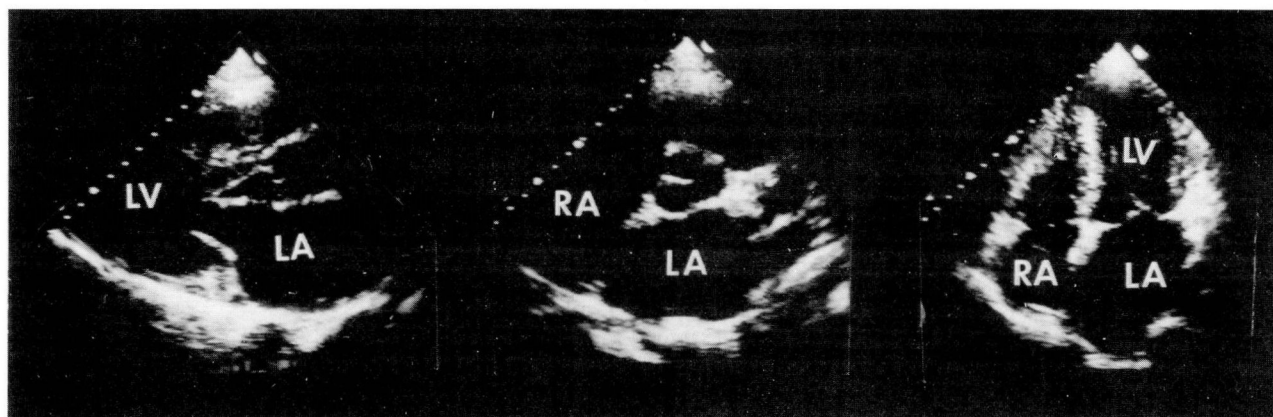


FIGURE 1. Transthoracic echocardiogram in parasternal long-axis view (left), parasternal short-axis view (middle), and apical four-chamber (right) prior to cardioversion, showing a hypertrophic left ventricle (LV) with a small left ventricular cavity size and a dilated left atrium (LA). A thrombus is present in the left atrium but cannot be seen. (RA, right atrium)

in which case the incidence of systemic embolus is very low. At the moment, no study has compared 3 weeks of warfarin therapy with simple clearance by TEE. As a matter of fact, a study has not been done—and probably never will be done—to perform cardioversion in people with left atrial appendage clots. I am sure that, for years, 10% to 15% of the people in whom we performed cardioversion had left atrial appendage thrombus, and they didn't have embolic events. Now, we have a self-fulfilling prophecy: if you don't perform cardioversion and the patient doesn't have an embolism, you say "See that? We've prevented an embolism and another stroke." A lot of what we are doing is not based on science. There is no evidence I know of that the patient would have had an embolism if cardioversion had been done initially. And there is no evidence that giving him the anticoagulant regimen that you did was better than just 3 to 6 more weeks of warfarin. Certainly, from a financial standpoint, this patient had three TEE studies, and that has to cost more than 3 to 6 weeks of warfarin therapy.

The real proven benefit of TEE is it gives the clinician the basis to proceed with cardioversion quickly. For instance, if a patient comes in with atrial fibrillation and heart failure, you would like to perform cardioversion quickly, but you do not know how long he has been in atrial fibrillation. If you perform TEE and do not see atrial thrombi, the potential for embolization is minuscule and immediate cardioversion is justified. This has been my approach for several years, and no patient of mine who did not have a left atrial appendage clot has ever had an embolus.

**DR. KLEIN:** I agree with Dr. DeMaria that TEE is ideal for the patient who needs cardioversion quickly. Beyond this, though, it is worthwhile to review the literature and see where the recommendations for 3 weeks of anticoagulation before and 4 weeks after cardioversion came from. These were based on several nonrandomized studies from the 1960s that showed anticoagulation effective in preventing stroke. Additionally, from the Cleveland Clinic several years ago, there was a retrospective study of embolic complications in 454 elective direct-current cardioversions in which the embolism rate was 1.3%, all in patients who had not undergone anticoagulation. The key question is: Does TEE offer advantages over this full course of anticoagulation? I believe it could, in detecting occult clots that might be dislodged with cardioversion, particularly in the left atrial appendage. Furthermore, TEE does shorten the course of anticoagulation, which might be surprisingly cost-effective, since it would reduce both the medication and monitoring costs of warfarin. Finally, even a small reduction in stroke rate would make this approach quite cost-effective. We estimate that a stroke costs approximately \$64 000 in direct and indirect costs to the patient. If TEE can reduce the stroke rate from approximately 1.6% down to 0.1%, this would result in a 39% cost savings over conventional therapy.

The problem is that we simply don't know what these percentages are, and this has motivated us to begin a multicenter study, the Assessment of Cardioversion Using Transesophageal Echocardiography (ACUTE). In this study, patients are random-

ized to undergo either 3 weeks of anticoagulation followed by cardioversion and another 4 weeks of anticoagulation, or TEE with therapeutic anticoagulation at the time of cardioversion and for 4 weeks after. The pilot study is underway and has attracted 17 centers in the United States, Europe, and Australia. We hope it will provide definitive guidance for clinical care in the future.

**DR. THOMAS:**

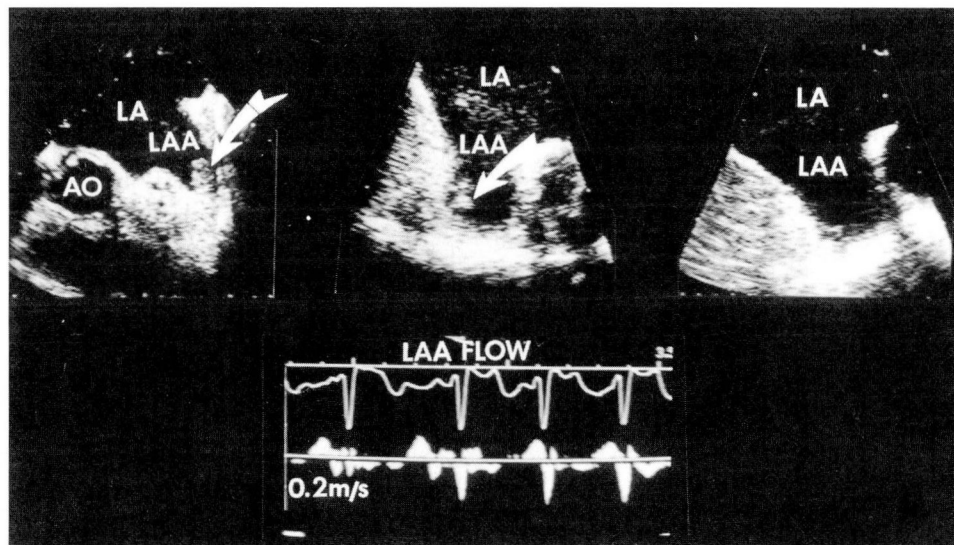
Dr. DeMaria, what is your policy on anticoagulation following cardioversion?

**DR. DEMARIA:** If I have performed TEE and find no evidence of a clot, I do not institute anticoagulation at all. So far, we have had no late embolic events. I recognize that there is some atrial dysfunction following cardioversion, something we have known since 1974 from M-mode echocardiography. It's a theoretical concern, but it has not been a problem in my experience.

**DR. KLEIN:** We have been very interested in the issue of anticoagulation after cardioversion, and in general we favor 3 weeks of warfarin therapy after cardioversion. Indeed, we recently gathered 17 cases from around the world in which patients underwent cardioversion with negative TEE and then went on to have embolic events. We do not know if a clot might have been missed, but the one unifying clinical factor in all these patients was that none was receiving adequate anticoagulation at the time of the embolic event. Indeed, based on the appearance of increased spontaneous echocardiographic contrast (smoke) after cardioversion, there appears to be more stasis after cardioversion than before, making it a more thrombogenic milieu.

**DR. DEMARIA:** Why should there be more stasis after cardioversion than before?

**DR. THOMAS:** One thing I have learned in the past year is how remarkably contractile the atrial



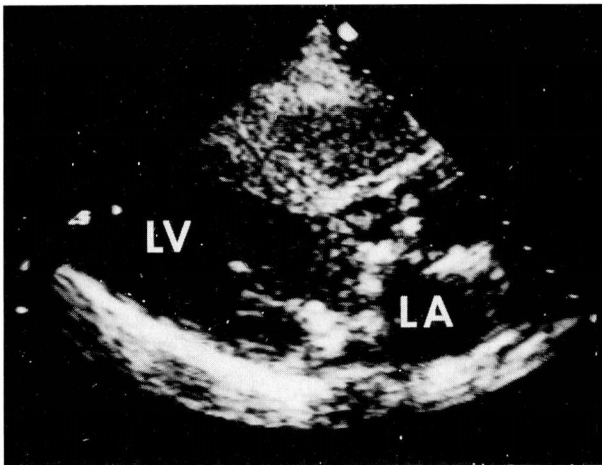
**FIGURE 2.** Transesophageal echocardiogram, in a patient with atrial fibrillation (top left), after 72 hours of intravenous heparin therapy (top middle), and after 2 months of warfarin therapy (top right). Note the presence of a thrombus in the left atrial appendage (LAA) (arrow), residual thrombus at 72 hours, and complete resolution at 2-month follow-up. The bottom panel shows a pulsed-Doppler recording of the left atrial appendage showing low amplitude, fibrillatory velocities in the left atrial appendage. (AO, aorta; LA, left atrium)

appendage is in atrial fibrillation. Typically, the appendage in fibrillation displays dramatic swings of velocity at 400 to 600 beats per minute, with velocities up to about 100 cm/second in and out of the appendage. These velocities are much lower following cardioversion, and thus the local shear rate is likewise diminished. This reduction in shear rate makes for a more thrombogenic situation after cardioversion than before and makes a case for 3 weeks of anticoagulation following cardioversion, even if TEE is negative.

**DR. DEMARIA:** I think in designing his trial Dr. Klein should include one arm where anticoagulants are not used after cardioversion, because, based on my experience, I do not believe these patients are at significant risk after successful cardioversion if TEE shows that the atrium is perfectly clean. It would be an interesting hypothesis to test.

It is hard to know what to do with your 17 anecdotes of postcardioversion embolization despite negative TEE. Perhaps clots were present but were missed by the examiners.

**DR. THOMAS:** Let me explore the outer limits of Dr. Klein's policy. As you know, one of the most common settings for atrial fibrillation is in the patient who has just undergone open heart surgery.



**FIGURE 3.** Transthoracic echocardiogram showing a Saint Jude prosthesis in the mitral valve position with an ill-defined mass attached to the left atrial side of the prosthesis. (LA, left atrium; LV, left ventricle)

If a patient goes into atrial fibrillation 2 days after surgery, the arrhythmia is obviously caught on the monitor immediately. Does the patient need TEE before cardioversion? What do you think the duration limit is for cardioversion without anticoagulation or TEE?

**DR. KLEIN:** The general rule of thumb has been that atrial fibrillation of less than 48 hours will respond to cardioversion without anticoagulation and, by implication, without TEE. Again, this policy is based on remarkably sparse data, but that is the overall approach we have taken. However, if the arrhythmia persists for more than 48 hours, we would recommend anticoagulation with heparin, TEE to rule out atrial thrombus, cardioversion, and then 3 weeks of warfarin therapy. In our experience, we found two patients with thrombi in this setting.

**DR. THOMAS:** Dr. DeMaria, how do you approach postoperative atrial fibrillation?

**DR. DEMARIA:** In general, I agree with the 48-hour cutoff. If the duration of fibrillation is less than that, cardioversion is in order. If fibrillation has persisted more than 48 hours, I favor TEE to rule out atrial thrombus. If TEE is negative, I prefer cardioversion without anticoagulation.

#### CASE 2: TEE IN PROSTHETIC VALVE DYSFUNCTION

**DR. BELLI:** The second patient was a 46-year-old woman transferred to the Cleveland Clinic for evaluation of a transient neurologic deficit, consist-

ing of left arm paresis and some gait instability. She had a history of rheumatic heart disease and had undergone mitral valve commissurotomy in 1977 and 1985, followed by mitral valve replacement in 1992 with a Saint Jude prosthesis (*Figure 3*). She had undergone anticoagulation therapy, but 1 month before admission she had decreased her warfarin dose. At the time of her neurologic event, her prothrombin time was below the therapeutic level at 13.7 seconds.

**DR. THOMAS:** Dr. DeMaria, do you feel TEE is necessary in the management of this patient at this point?

**DR. DEMARIA:** No. There is only one form of therapy that would help anything you could find by TEE—anticoagulation—and that is indicated regardless of what you see. TEE will add nothing to the management of this patient at this point.

**DR. KLEIN:** Despite the obvious need for therapeutic anticoagulation in this patient, we felt that TEE either would yield important information for guiding therapy or perhaps would show evidence of endocarditis.

**DR. DEMARIA:** Was there any clinical evidence for endocarditis? Fever, chills, abnormal white blood cell count? Was the valve functioning normally on the basis of transthoracic echocardiography?

**DR. KLEIN:** At the time of the examination, there was no clinical evidence of endocarditis, and Doppler velocities across the valve were normal by transthoracic echocardiography.

**DR. DEMARIA:** Suppose you perform TEE and see no clot. Would you withhold anticoagulation therapy?

**DR. KLEIN:** No. But it would help me tailor how aggressive to be with anticoagulation, or perhaps it would identify a need for surgical intervention. Also, if she were having gastrointestinal bleeding, one might argue for less anticoagulation.

**DR. DEMARIA:** Regardless of gastrointestinal bleeding, I believe this patient needs anticoagulation. I can always resort to blood transfusion if she bleeds, but I can't give her Betz's cells if she has a stroke. If she truly cannot tolerate anticoagulation therapy, then she needs a different type of prosthetic valve.

**DR. THOMAS:** What were the TEE findings?

**DR. KLEIN:** TEE demonstrated several large, highly mobile masses on the left atrial side of the prosthetic valve (*Figure 4*). Because of their size and

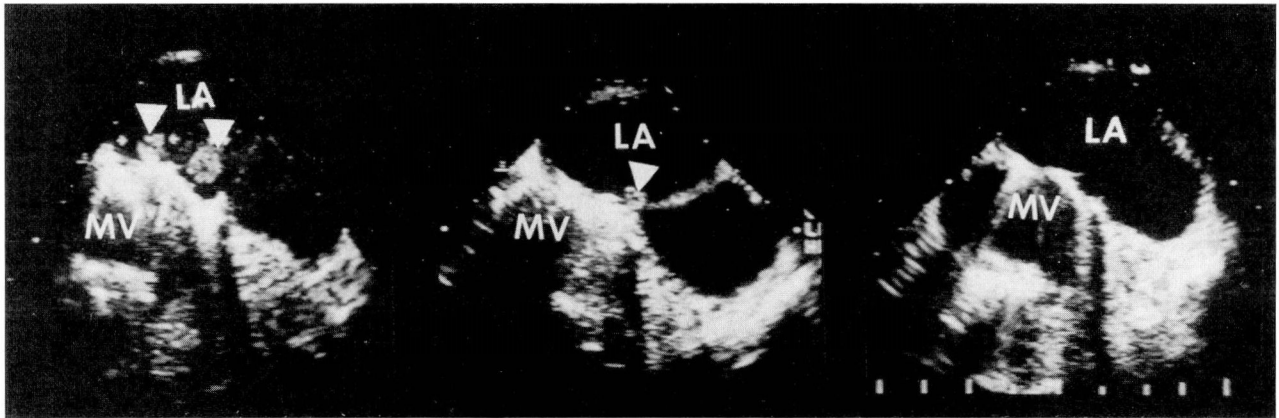


FIGURE 4. Transesophageal echocardiogram showing two mobile masses (arrow heads) attached to the left atrial side of the mitral valve prosthesis (left), partial resolution after urokinase treatment at 24 hours (middle), and complete resolution of the masses 9 days later (right). (LA, left atrium; MV, mitral valve)

the prior transient ischemic attack, we approached the surgeons about surgical exploration, but as this would be her fourth operation, they advised a trial of medical therapy.

**DR. BELLI:** At this time, about 1 week after the first TEE study, her blood cultures became positive for *Staphylococcus epidermidis*.

**DR. DEMARIA:** Well, I doubt that her valve infection was caused by TEE, but it does point out that these are not entirely risk-free procedures.

**DR. THOMAS:** Dr. Belli, how was the patient managed at this point?

**DR. BELLI:** After consulting with the surgeons, we decided to treat her with urokinase. After 24 hours, repeat TEE showed some shrinkage of the masses, and urokinase therapy was continued. TEE performed about 9 days later showed virtually complete resolution of the masses (Figure 4).

**DR. KLEIN:** Dr. DeMaria, do you see any role for TEE in the management of this patient?

**DR. DEMARIA:** I must admit that, had this patient been in my hospital, there is very little chance she would have avoided TEE during the course of her treatment. However, I think we must continuously ask ourselves if the results of TEE are going to change the management. Simple risk stratification of a patient makes little sense if there is no change in medical therapy. In this case, the patient had three or four TEE studies, and there is at least some question historically as to whether TEE might have contributed to the endocarditis.

**DR. THOMAS:** I think the issue of thrombolytic therapy in this case is very interesting. I must

say I get nervous thinking about the urokinase eating away at the tiny stalk holding these masses onto the valve, and allowing these middle cerebral artery-sized balls to flip out into the periphery. Dr. DeMaria, what is your approach to thrombolytic therapy in prosthetic valve thrombosis?

**DR. DEMARIA:** I obviously have not heard all the facts of this case, but in general I do not prescribe thrombolytic therapy unless the valve is hemodynamically dysfunctional. Not that I don't think it will work—but I share your fears of peripheral embolization, so I just go with traditional anticoagulation therapy.

**DR. KLEIN:** I too am concerned, but given the size of the masses on the prosthetic valve, we decided to proceed with thrombolytic therapy in this case.

**DR. THOMAS:** The trouble is that none of us has enough experience with this sort of case to know what is the right thing to do. Most experience with this is merely anecdotal.

**DR. DEMARIA:** There are a few very small studies. We recently reviewed the literature on prosthetic valve thrombolysis and found a few disturbing reports of patients who had serious embolic phenomena after thrombolytic therapy. It is clearly not completely benign, but we just do not know how dangerous it is.

**DR. THOMAS:** Let's broaden the discussion a bit, still keeping with endocarditis. Suppose a 37-year-old man presents with fever, chills, *Streptococcus viridans* bacteremia, and an obvious mitral valve vegetation. Does he need TEE?

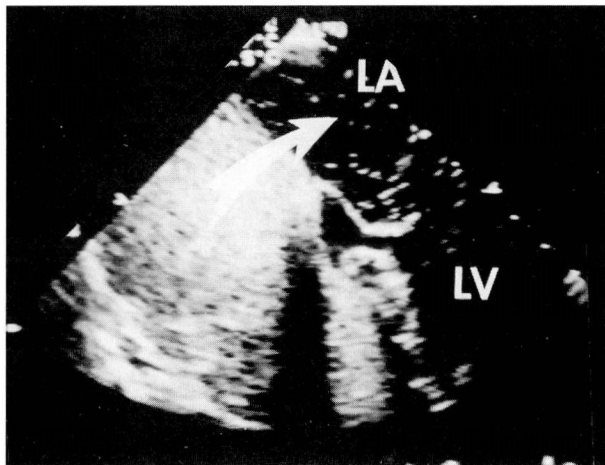


FIGURE 5. Transesophageal echocardiogram with agitated saline injected into the right atrium, showing the presence of a patent foramen ovale, with bubbles crossing into the left atrium (LA). Note the bubbles in the left atrium (arrow). (LV, left ventricle)

**DR. DEMARIA:** No. The diagnosis is secure. The organism is not aggressive, and the mitral valve is not one that is associated with a high incidence of perivalvular complications.

**DR. KLEIN:** I agree. The scenario you describe is very benign, with a high likelihood of a medical cure, so I would just follow the patient with serial transthoracic echocardiography.

**DR. THOMAS:** What facts of the case would change your approach to this, Dr. DeMaria?

**DR. DEMARIA:** You have to consider the organism, the valve involved, and other associated conditions. For instance, *Staphylococcus aureus* is a much more aggressive organism, and I think routine TEE is useful to assess valvular destruction and extravalvular complications. Also, if the endocarditis is on the aortic valve, there is a much higher risk of extravalvular complications, such as root abscess, and I believe TEE gives useful information in such a case. Also, if the patient has a prosthetic valve and bacteremia, I believe TEE is essential.

**DR. THOMAS:** The critical point is that we use the additional information wisely. The 37-year-old man I described was actually one I recall from my fellowship a few years back, in the days before TEE, when 2-dimensional echocardiography was still relatively novel. The appearance of the mitral vegetation prompted the attending physician to fear an embolism and to send the patient for mitral valve replacement that same day. I've always

thought that without the echocardiogram, the patient would have simply been treated with penicillin, with a very high probability of a medical cure.

**DR. DEMARIA:** That's an important point. A related issue is the question of ruling out endocarditis. We're seeing an increasing number of patients referred for TEE on the basis of bacteremia and a nondiagnostic transthoracic echocardiogram. It's just not clear to me that finding a tiny vegetation on one valve with TEE is going to significantly affect management of the patient. This is an important area for multicenter collaboration to gather data on the clinical utility of TEE, particularly as it relates to patient outcome.

**DR. KLEIN:** TEE has such high spatial resolution that you often see tiny structures that might be vegetations but usually are not. For instance, we commonly see a number of 1-mm linear strands coming off the aortic valve, Lambl's excrescences, but these are entirely benign structures.

**DR. THOMAS:** A lot of vancomycin has probably been given for Lambl's excrescences over the years.

---

#### CASE 3: TEE FOR SOURCE OF EMBOLUS

---

**DR. ANNAN:** A 47-year-old man with no history of medical problems had a sudden onset of dizziness, disorientation, and peripheral vision loss lasting for about 2 hours. His only residual symptom was a left frontal headache. He underwent a neurologic workup: carotid ultrasound was normal, and computed tomography and magnetic resonance imaging of the brain were negative. Transthoracic echocardiography was entirely normal, and the patient was referred for TEE to evaluate for a possible cardiac source of embolus.

**DR. THOMAS:** This man has a transient neurologic syndrome and a negative transthoracic echocardiogram. Dr. DeMaria, do you think he needs TEE?

**DR. DEMARIA:** No. The patient's symptoms are not particularly suggestive of an embolic episode, and the yield in this case is going to be extremely low. If we do TEE in everybody who gets weak and dizzy, we will need to buy a lot more echocardiography machines.

**DR. THOMAS:** I presume that since this patient is being presented at this conference he underwent TEE. Dr. Klein, what was found?

**DR. KLEIN:** He did undergo TEE (Figure 5).

We were able to demonstrate a patent foramen ovale with a small amount of left-to-right flow by color Doppler ultrasonography. Furthermore, when agitated saline was injected as echocardiographic contrast, there was a small amount of right-to-left flow when the patient performed a Valsalva maneuver.

**DR. THOMAS:** Given that patent foramen ovale is present in up to 25% of the population, what importance do you attach to finding it in this patient?

**DR. KLEIN:** I don't believe the data are in on this subject yet. In this particular case, in consultation with the neurologists, we prescribed aspirin.

**DR. DEMARIA:** But aspirin is good for all that ails you. It ought to be in the water supply. I'm terribly unimpressed that a patent foramen ovale is related to most neurologic events. First of all, patent foramina ovale are very small, generally only probe-patent. Right-to-left shunting in the absence of a Valsalva maneuver is very unusual, and even with a major Valsalva the risk is usually not that great. The combination of coincidences is tremendous: a small clot must be exactly in the vicinity of the foramen ovale at the precise moment the patient performs the Valsalva maneuver to enable it to get across with a microscopic amount of right-to-left blood flow. In fact, the incidence of paradoxical embolus in patients with large atrial septal defects is tremendously low, and nearly all who have been reported to have paradoxical embolus have had clear-cut thrombophlebitis, usually with elevated pulmonary artery pressure. Other than the isolated observation that patent foramen ovale tends to be a bit more common in people with unexplained cerebral ischemia, I see little to indicate a causal relationship.

**DR. KLEIN:** And yet we have seen several cases of large deep venous thromboses-in-transit across the patent foramen ovale, so paradoxical embolus clearly can occur. Overall, however, I agree with Dr. DeMaria and would reserve my most aggressive workup for young patients who have recurrent symptoms of transient cerebral ischemia. I think neurologists must be fairly selective about which patients they refer to us, since at the Cleveland Clinic only about 15% of our TEE volume is referred for investigation of a cardiac source of embolus, whereas it may be up to 40% of the TEE volume in other medical centers.

**DR. THOMAS:** Let me ask about another proposed source of embolus, the atrial septal aneurysm. How do you approach that?

**DR. DEMARIA:** I put it in the same category as patent foramen ovale, with the exception that I use warfarin a bit more quickly, since I think there is some risk of in situ clot formation with this aneurysm. Realize, though, that I am talking about a real atrial septal aneurysm, with a windsock-like morphology, not just a little bowing of the interatrial septum.

**DR. KLEIN:** You raise a good point about definitions. There is a need in this whole field for more strict definitions of what we are diagnosing. How many contrast bubbles need to cross to make the diagnosis of patent foramen ovale? What really constitutes an atrial septal aneurysm? Until we can agree on these terms, we won't be able to make any sense out of the literature.

In addition, there is a great deal of interest in intra-aortic atherosclerotic debris as a source of embolus in cardiac surgery. There are suggestions that routine screening by epi-aortic imaging at the time of cardiac surgery may allow modification of cannulation and cross-clamp technique and may lower the incidence of postsurgical stroke, but there is no evidence for this yet.

**DR. THOMAS:** At the Cleveland Clinic, we perform about 3500 cardiac operations annually. The idea of adding 3500 epi-aortic studies to our echocardiography laboratory volume is daunting indeed.

I would like to thank our discussants for a most instructional and provocative discussion.

---

SUGGESTED READING

---

Daniel WG, Nellessen U, Schoder E, et al. Left atrial spontaneous echo contrast in mitral valve disease: an indicator for an increased thrombus embolic risk. *J Am Coll Cardiol* 1988; 11:1204-1211.

Grimm AG, Stewart WA, Black IW, Thomas JD, Klein AL. Should all patients undergo transesophageal electrocardiography before electrical cardioversion of atrial fibrillation? *J Am Coll Cardiol* 1994; 23:533-541.

Grimm RA, Stewart WJ, Maloney JD, et al. Impact of electrical cardioversion for atrial fibrillation on left atrial appendage function and spontaneous echo contrast: characterization by simultaneous transesophageal echocardiography. *J Am Coll Cardiol* 1993; 22:1359-1366.

Karalis DG, Chandrasekaran K, Victor MF, et al. Recognition and embolic potential of intra-aortic atherosclerotic debris. *J Am Coll Cardiol* 1991; 17:73-78.

Klein AL, Grimm RA, Black IW, et al. Cost effectiveness of TEE-guided cardioversion with anticoagulation compared to conventional therapy in patients with atrial fibrillation [abstract]. *J Am Coll Cardiol* 1994; 23:128A.

Kronzon I, Tunick PA. Transesophageal echocardiography as a tool in evaluation of patients with embolic disorders. *Prog Cardiovasc Dis* 1993; 36:39-60.

Lechat PH, Mas JL, Lascault G, et al. Prevalence of patent foramen ovale in patients with stroke. *N Engl J Med* 1988; **318**:1148-1152.

Manning WJ, Silverman DI, Gordon SP, Krumholz HM, Douglas PS. Cardioversion from atrial fibrillation without prolonged anticoagulation with use of transesophageal echocardiography to exclude the presence of atrial thrombi. *N Engl J Med* 1993; **328**:750-755.

Mugge A, Daniel WG, Frank G, et al. Echocardiography of infective endocarditis: reassessment of the prognostic implication of vegetation site determined by the transthoracic and the transesophageal approach. *J Am Coll Cardiol* 1989; **14**:631-638.

Pearson AC, Labowitz AJ, Tatineni, Gomez, CP. Superiority of transesophageal echocardiography in detecting cardiac sources of embolization in patients with cerebral ischemia of uncertain etiology. *J Am Coll Cardiol* 1991; **17**:66-72.

Pop G, Sutherland GR, Koudstaal PJ, et al. Transesophageal echocardiography in the detection of intracardiac embolic sources in patients with transit and ischemic attacks. *Stroke* 1990; **21**:560-565.



**CME CREDIT**

To earn CME Category I credit, see test on p. 240



**THE CLEVELAND CLINIC FOUNDATION**

in joint sponsorship with the  
**American Society of Echocardiography**  
presents

**FIFTH ANNUAL  
INVASIVE  
ECHOCARDIOGRAPHY**

**A Live Demonstration Course in  
Intraoperative Transesophageal  
Echocardiography**

For cardiologists, anesthesiologists, and cardiac surgeons familiar with echocardiographic technology and diagnosis. Current uses of these techniques will be demonstrated via direct video link with Cleveland Clinic outpatient clinic, cardiac catheterization laboratory, and operating rooms. Applications to be covered include endocarditis, source of embolus, diastolic dysfunction, valve repair, valve replacement, myectomy, complex congenital cardiac surgery, and many others.

**ATTENDANCE IS LIMITED TO 250**  
Registration fee: \$400.00  
Registration fee ASE members: \$320.00

**September 28-30, 1994**

**Bunts Auditorium  
The Cleveland Clinic Foundation  
Cleveland, Ohio**

For further information, write or call:

**The Cleveland Clinic Educational Foundation  
Continuing Education Department  
9500 Euclid Avenue, TT-31  
Cleveland, OH 44195  
216-444-5696 800-762-8173  
216-445-9406 (Fax)**