



# An unusual ocular manifestation of discoid lupus erythematosus

ROBERT E. FOSTER, MD; CAREEN Y. LOWDER, MD; DAVID M. MEISLER, MD;  
RAFAEL VALENZUELA, MD; JAMES T. McMAHON, PhD; CHARLES CAMISA, MD

- **BACKGROUND** Discoid lupus erythematosus is a chronic skin disease characterized by well-demarcated papules and plaques. Mucous membrane changes are common; however, conjunctival involvement is unusual. We report a case of unilateral, chronic, isolated discoid lupus erythematosus of the conjunctiva.
- **OBSERVATIONS** A 32-year-old man presented for evaluation of chronic conjunctivitis of the right eye that had persisted for 9 years. A biopsy of the bulbar conjunctiva revealed a mixed mononuclear cellular infiltrate distributed along the epithelial basement membrane zone and around the stromal blood vessels. Immunohistopathologic examination revealed a diffuse, granular pattern of fluorescence corresponding to immunoglobulins and complement components along the epithelial basement membrane zone and in the walls of the stromal blood vessels. Electron microscopy demonstrated changes in the epithelial basal lamina consistent with discoid lupus erythematosus, including areas that were multilayered. Immunoelectron microscopy identified sub-basal lamina deposits of immunoglobulin G.
- **CONCLUSIONS** Discoid lupus erythematosus should be a suspected cause of chronic conjunctival inflammation; the diagnosis is substantiated by immunopathologic and ultrastructural studies.

■ **INDEX TERMS:** LUPUS ERYTHEMATOSUS, DISCOID; CONJUNCTIVAL DISEASES  
■ CLEVE CLIN J MED 1994; 61:232-237

From the Departments of Ophthalmology (R.E.F., C.Y.L., D.M.M.), Immunopathology (R.V.), Pathology (J.T.M.), and Dermatology (C.C.), The Cleveland Clinic Foundation.

Address reprint requests to C.Y.L., Department of Ophthalmology, A31, The Cleveland Clinic Foundation, 9500 Euclid Avenue, Cleveland, OH 44195.

Presented in part at the Annual Meeting of the Georgiana Dvorak Theobald Society, Hilton Head, South Carolina, May 24, 1991, and the Ocular Microbiology and Immunology Group Annual Meeting, Anaheim, California, October 12, 1992.

**D**ISCOID LUPUS erythematosus (DLE) is a chronic skin disease characterized by scaly, erythematous, well-demarcated papules and plaques on the face, scalp, ears, and other sun-exposed areas of the body.<sup>1-3</sup> Lesions on the eyelid are the most frequently observed ophthalmic feature,<sup>3,4</sup> and isolated DLE of the eyelid has been reported anecdotally.<sup>3,5-9</sup>

Mucous membrane lesions may be found in up to 24% of patients with DLE<sup>10</sup> and are usually observed on the buccal or labial mucosa, vermillion border, gingiva, or anogenital mucosa; conjunctival changes are less common.<sup>10-14</sup> It has been uncertain if isolated conjunctival involvement without other apparent skin or mucous membrane lesions can occur in DLE.

We report the clinicopathologic findings of DLE of the conjunctiva in a patient who lacked other lesions characteristic of DLE on the skin or other mucous membranes.

## CASE HISTORY

In March 1988, a 32-year-old man presented for evaluation of chronic conjunctivitis of his right eye that had persisted for 9 years despite treatment with topical and

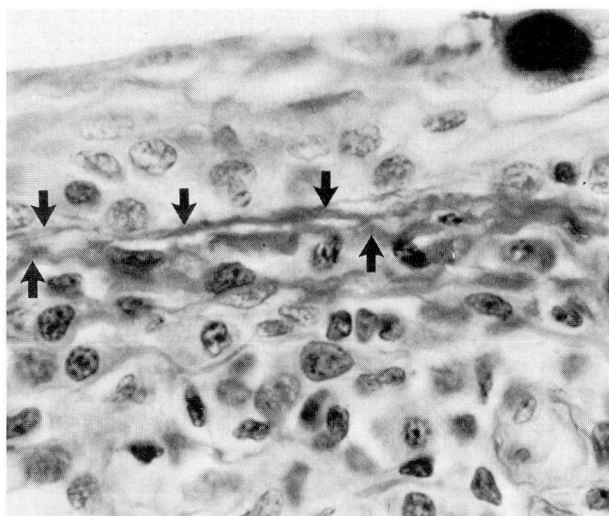


FIGURE 1. Light micrograph of conjunctival biopsy specimen from 1988 showing an irregular, thickened, multilayered epithelial basement membrane (arrows) and lymphocytic and histiocytic infiltrate that is concentrated along the conjunctival basement membrane zone (periodic acid-Schiff, original magnification  $\times 400$ ).

systemic antibiotics and topical corticosteroids. Ophthalmic examination revealed an uncorrected visual acuity of 20/15 bilaterally. Slit-lamp biomicroscopic examination revealed moderate bulbar conjunctival injection, chemosis, and redundancy and a mild tarsal conjunctival papillary reaction of the right eye.

To establish a diagnosis, a biopsy of the inferior bulbar conjunctiva of the right eye was done. Tissues stained with Gram's stain, Fite's stain, and Grocott-Gomori methenamine-silver nitrate stain did not demonstrate bacteria, acid-fast bacilli, or fungi, respectively. No polarizable foreign material was identified. Histopathologic examination showed a lymphocytic and histiocytic cellular infiltrate concentrated along the basement membrane zone of the conjunctival epithelium and around the stromal blood vessels. Sections stained by the periodic acid-Schiff method demonstrated a thickened and irregular basement membrane (Figure 1).

The patient was treated with fluorometholone 0.1% drops every 2 hours while awake in the right eye, with substantial improvement of the conjunctival injection over a 2-week period. Subsequently, the drops were tapered in frequency over several weeks and then discontinued. Within 2 weeks, however, the conjunctival injection recurred; it again responded to topical corticosteroid treatment. The

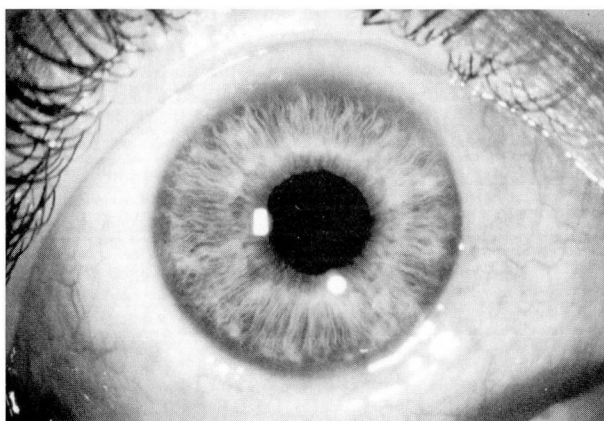


FIGURE 2. Photograph from 1991, showing conjunctival injection, chemosis, and redundancy.

patient took fluorometholone drops twice daily as maintenance therapy, and he was reexamined at regular intervals.

In March 1991, ophthalmic examination of the right eye revealed an uncorrected visual acuity of 20/15. Slit-lamp biomicroscopic examination revealed minimal conjunctival injection, moderate conjunctival chemosis and redundancy, and a well-healed conjunctival scar from the biopsy. No symblepharon, forniceal foreshortening, or other cicatrizing change was observed. The fluorometholone drops were discontinued because of concerns regarding long-term topical corticosteroid use. Within 3 days, moderately severe bulbar conjunctival injection and chemosis recurred (Figure 2); the inferior tarsal conjunctiva was chemotic and exhibited a mild papillary reaction. To establish a more definitive diagnosis, we performed another biopsy of the inferior bulbar conjunctiva.

We divided a 10- $\times$  8-mm biopsy specimen of inferior bulbar conjunctiva into three pieces. A 3- $\times$  3-mm segment was submitted in formalin for light microscopy, a 5- $\times$  4-mm segment was submitted in saline for immunopathologic evaluation, and a 2- $\times$  1-mm segment was submitted in glutaraldehyde for electron microscopy. Samples for culture were obtained at the time of surgery from the excised conjunctiva.

Light microscopy revealed a mixed lymphocytic and histiocytic cellular infiltrate concentrated along the basement membrane zone of the epithelium and around the stromal blood vessels (Figure 3). No giant cells or polarizable foreign body inclusions were observed, although the infiltrate appeared more



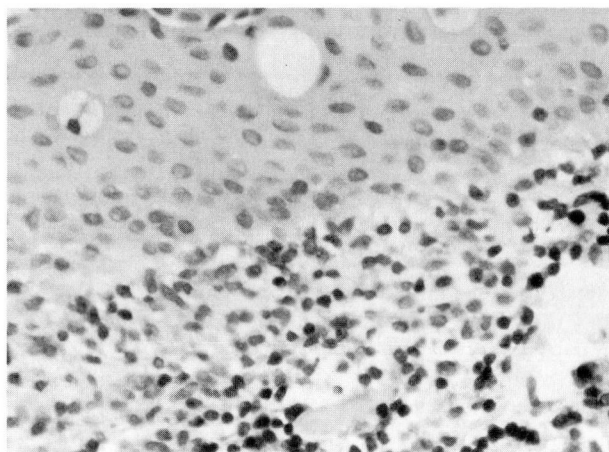


FIGURE 3. Light micrograph of conjunctival biopsy specimen from 1991 showing a lymphocytic and histiocytic infiltrate concentrated along the conjunctival epithelial basement membrane zone that appears more granulomatous than in the previous biopsy specimen (hematoxylin-eosin, original magnification  $\times 100$ ).

granulomatous than in the previous biopsy specimen. No bacteria, fungi, or acid-fast bacilli were detected in tissues stained with Gram's stain, Grocott-Gomori methenamine-silver nitrate stain, or Ziehl-Neelsen stain, respectively, and no organisms, including *Chlamydia*, were recovered in culture.

Immunohistopathologic examination revealed a diffuse granular pattern of fluorescence corresponding to deposits of the immunoglobulins IgG (3+), IgM (3+), and IgA (trace), the complement factors C3 (1+) and C1q (1+), and fibrinogen-related products (1+) along the basement membrane zone of the conjunctival epithelium (Figure 4). Focal, granular deposits of IgG, IgM, and C3 were detected in the walls of conjunctival stromal blood vessels (Figure 5).

Electron microscopic examination of the conjunctiva demonstrated changes in the epithelial basal lamina. The lamina densa was irregularly thickened and focally redundant or multilayered (Figure 6). Other areas of the lamina densa were thinned or missing. Finely granular, amorphous, electron-dense deposits were detected in the subbasal lamina region (Figure 6). Immunoelectron microscopic examination revealed IgG deposits in the subbasal lamina (Figure 7). The basal lamina of the dermal blood vessels displayed similar but less pronounced changes.

DLE of the conjunctiva was diagnosed on the basis of the histopathologic, immunohistopathologic, and immunoelectron microscopic findings.

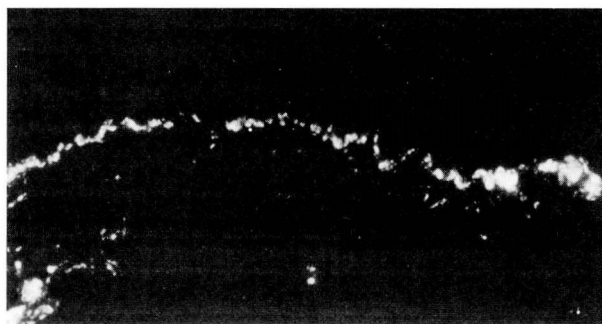

FIGURE 4. Direct immunofluorescence light micrograph of the conjunctiva, showing a diffuse, granular pattern of fluorescence along the basement membrane zone of the epithelium (anti-human IgM staining, original magnification  $\times 100$ ).

Topical corticosteroid and antibiotic treatment was started, and the biopsy site healed without sequelae. Dermatologic examination did not reveal lesions on the skin or scalp or on other mucous membranes.

Six months later, the topical corticosteroid therapy was again discontinued. Within 3 days, the conjunctival injection recurred, and the patient was treated with hydroxychloroquine 200 mg by mouth twice daily. Due to gastrointestinal side effects, the hydroxychloroquine was discontinued shortly thereafter. Topical fluorometholone therapy was restarted, and the conjunctival injection resolved over several days.

Results of laboratory studies done in 1991 were normal; these included a complete blood count, serum chemistry survey, angiotensin-converting enzyme level, erythrocyte sedimentation rate, complement studies (including C3, C4, C1q, and total hemolytic complement), and nonreactive rapid plasma reagin and fluorescent treponemal antibody absorption tests. A test for antinuclear antibody was borderline-positive at a titer of 1:40 with a homogenous pattern; tests for anti-extractable nuclear antibody and antideoxyribonucleic acid antibody were negative.

## DISCUSSION

DLE is generally considered a benign skin disease.<sup>4,7,9</sup> However, recognition of this condition is important because discoid lesions may result in scarring and permanent disfigurement that can be avoided with appropriate treatment.<sup>3,4</sup> The diagnosis of DLE is partly based on the recognition of characteristic skin lesions, but definitive diagnosis requires



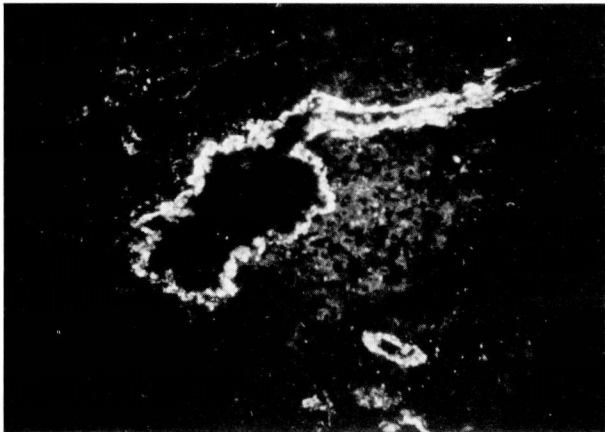


FIGURE 5. Direct immunofluorescence light micrograph of the conjunctiva, showing granular pattern of fluorescence in the wall of a conjunctival stromal blood vessel (anti-human IgG staining, original magnification  $\times 400$ ).

histopathologic confirmation.<sup>9,15</sup> The dermal-epidermal basement membrane zone is commonly thickened or multilayered<sup>16</sup> and is the primary focus of inflammation.<sup>17</sup> A patchy, lymphohistiocytic cellular infiltrate may be observed along the basement membrane zone and around dermal blood vessels and pilosebaceous structures.<sup>3,16,18</sup> Chronic lesions may have granulomatous features.<sup>19</sup> Dermal edema and vasodilatation are common findings.<sup>16</sup> Basal epidermal cells often demonstrate liquefactive (hydropic) degeneration characterized by intracellular edema and vacuole formation and focal necrosis of basal epidermal cells.<sup>3,16,18</sup>

Direct immunofluorescent studies of the skin may confirm the diagnosis and reveal a granular pattern of fluorescence along the dermal-epidermal basement membrane zone.<sup>20</sup> These immune deposits include immunoglobulins, typically IgG and IgM, and complement components such as C3 and C1q, although other immune reactants may be observed.<sup>20</sup> This granular immunofluorescent pattern may also be detected around dermal blood vessels and pilosebaceous structures.<sup>20</sup>

Ultrastructural features of discoid skin lesions include a thickened and multilayered epidermal basal lamina.<sup>3,18</sup> Immune deposits are usually found in the subbasal lamina region.<sup>3,16-18,21-23</sup>

The clinical features of conjunctival involvement in DLE are not well characterized. None of the cases of DLE described by Huey and associates<sup>3</sup> had associated conjunctival changes. However, in their review, 12 of the previously reported cases of DLE of

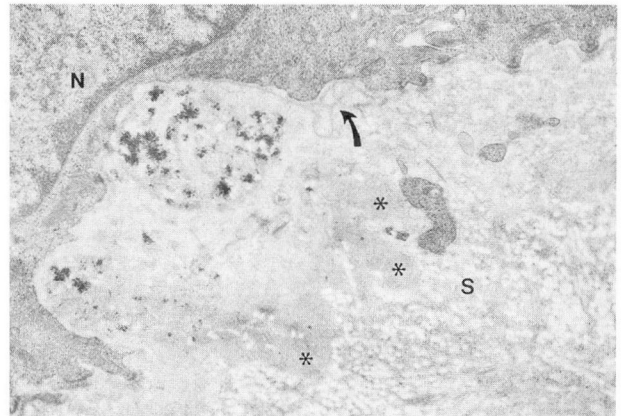


FIGURE 6. Transmission electron micrograph of the conjunctival epithelial basal lamina, showing focal multilayering of the lamina densa (arrow), and finely granular, amorphous, moderately electron-dense, subbasal lamina deposits (asterisks) in the superficial stroma (S). A conjunctival epithelial cell nucleus (N) is seen above. The identity of the dense particulate matter, which was irregularly distributed beneath the basal lamina, is uncertain (uranyl acetate and lead citrate staining, original magnification  $\times 9100$ ).

the eyelid had concomitant conjunctival involvement. Frith and associates<sup>24</sup> described the external ocular features of 30 patients with DLE that included chronic episcleral injection in 2 patients, one of whom had unilateral involvement. Bilateral conjunctival inflammation recurring over a 40-year period was reported in another case.<sup>10</sup> Tarsal conjunctival lesions have been described as erythematous, edematous patches with a velvety appearance.<sup>10,12,14</sup> Tarsal conjunctival scarring and symblepharon formation, although rare, have also been reported.<sup>10,24</sup> Our patient had chronic injection, chemosis, and redundancy of the bulbar conjunctiva and chemosis of the tarsal conjunctiva with a mild papillary reaction. No symblepharon formed, even after two conjunctival biopsies.

There is a paucity of information regarding conjunctival histopathologic findings in DLE. Vilanova and associates<sup>14</sup> studied conjunctival tissue taken at biopsy from a patient with chronic DLE; they found a mixed lymphocytic and histiocytic infiltrate along the basement membrane zone and around stromal blood vessels. Hydropic degeneration of the basal epithelial cells was not described, although basal cell degeneration and loss was observed. Recently, Frith and associates<sup>24</sup> demonstrated multiple immune reactants along the basement membrane zone of clinically uninvolved bulbar conjunctiva in 10 of



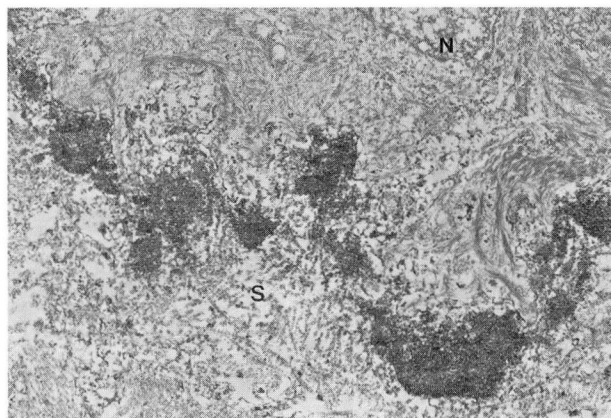


FIGURE 7. Transmission immunoelectron micrograph of the conjunctival epithelial basal lamina stained using anti-IgG antibody, showing subbasal lamina deposits in the superficial stroma (S). A conjunctival epithelial cell nucleus (N) is seen above (uranyl acetate and lead citrate staining, original magnification  $\times 6000$ ).

21 patients (48%) previously found to have DLE. Our patient's conjunctival biopsy specimen exhibited histopathologic findings consistent with those found in skin and conjunctiva in DLE, including a characteristic immunofluorescent pattern.

Localized DLE usually responds to treatment with topical or intralesional corticosteroids.<sup>10,17,25</sup> Systemic corticosteroids or aminoquinolone antimalarial agents, such as hydroxychloroquine, may be effective when topical or intralesional corticosteroid therapy is ineffective, when DLE is generalized, or when lesions are particularly destructive.<sup>17,25</sup> However, DLE does not respond to antimalarial therapy in approximately 25% of patients,<sup>1</sup> and these patients may benefit from subsequent intralesional corticosteroids.<sup>7</sup> Our patient's condition responded well to topical corticosteroid therapy. He was treated with hydroxychloroquine because of concerns regarding complications associated with long-term topical corticosteroid use. However, gastrointestinal side effects precluded an adequate therapeutic trial with this systemic agent.

DLE should be distinguished from other chronic conjunctival inflammatory diseases. Ocular cicatricial pemphigoid (OCP) almost always occurs in the elderly and is characterized by a progressive, cicatrizing course. Immunohistopathologic studies of conjunctival biopsies from patients with OCP typically demonstrate a linear pattern of immunofluorescence along the conjunctival basement membrane zone.<sup>15,20,26–31</sup> However, anecdotal reports have de-

scribed granular<sup>28,32</sup> immunofluorescent patterns in conjunctival biopsy specimens from patients with OCP similar to the granular immunofluorescent pattern of DLE. All of the patients with OCP described had cicatrizing conjunctival changes and other sequelae of OCP, such as nonocular mucous membrane lesions; our patient did not. Furthermore, immunoelectron microscopic studies of biopsy specimens in OCP have revealed immune deposits within the lamina lucida of the basal lamina,<sup>23,33,34</sup> in contradistinction to the subbasal lamina deposits that are observed in DLE.<sup>3,16–18,21–23</sup> Our patient's conjunctival biopsy specimen exhibited subbasal lamina deposits.

Other mucocutaneous diseases that may involve the conjunctiva and that have immunohistopathologic findings include lichen planus,<sup>20,23</sup> pemphigus,<sup>20,23,26,35,36</sup> paraneoplastic pemphigus,<sup>37</sup> bullous pemphigoid,<sup>20,34,36</sup> Stevens-Johnson syndrome,<sup>20</sup> and epidermolysis bullosa acquisita.<sup>38</sup> These disorders may be distinguished from DLE on the basis of historical, clinical, histopathologic, and immunohistopathologic findings.

It is important to recognize DLE because discoid lesions may herald the development of systemic lupus erythematosus (SLE) in approximately 5% to 10% of patients with generalized DLE.<sup>1</sup> The likelihood that SLE will develop in patients with DLE partly depends on the extent of skin involvement in DLE. When the lesions are confined to the head, DLE is classified as localized and has a better prognosis. When lesions are below the head, DLE is classified as generalized and has a worse prognosis.<sup>1,4</sup> Factors associated with an increased risk of DLE progressing to SLE include generalized DLE, an antinuclear antibody titer of 1:50 or greater, chronic anemia or leukopenia, a false-positive Venereal Disease Research Laboratory test, and positive immunofluorescence in biopsy specimens of clinically uninvolved skin, which by definition constitutes a positive lupus band test.<sup>39,40</sup> According to one study,<sup>41</sup> the yield of immunofluorescence in uninvolved conjunctiva is higher than the yield of immunofluorescence in uninvolved skin or oral mucosa in patients with DLE. Since normal conjunctiva in healthy patients without DLE has a low rate of positive immunofluorescence,<sup>24</sup> conjunctival biopsy may provide more diagnostic information in patients suspected of having DLE than biopsy of the skin or other mucous membranes. Care should be taken to remove only a small portion of conjunctiva in order to decrease the risk of

conjunctival scarring or symblepharon formation.

DLE should be a suspected cause of chronic conjunctival inflammation. Patients suspected of having DLE involving the conjunctiva should receive a

complete dermatologic examination to detect other mucocutaneous lesions, and a medical evaluation, including serial laboratory investigations, to exclude SLE.<sup>39</sup>

## REFERENCES

1. Callen JP. Chronic cutaneous lupus erythematosus. Clinical, laboratory, therapeutic, and prognostic examination in 62 patients. *Arch Dermatol* 1982; 118:412-416.
2. Estes D, Christian CL. The natural history of systemic lupus erythematosus studied by prospective analysis. *Medicine* 1971; 50:85-95.
3. Huey C, Jakobiec FA, Iwamoto T, Kennedy R, Farmer ER, Green WR. Discoid lupus erythematosus of the eyelids. *Ophthalmology* 1983; 90:1389-1398.
4. Donzis PB, Insler MS, Buntin DM, Gately LE. Discoid lupus erythematosus involving the eyelids. *Am J Ophthalmol* 1984; 98:32-36.
5. Meiusi RS, Cameron JD, Holland EJ, Summers CG. Discoid lupus erythematosus of the eyelid complicated by wound dehiscence. *Am J Ophthalmol* 1991; 111:108-109.
6. Tosti A, Tosti G, Giovannini A. Discoid lupus erythematosus solely involving the eyelids: report of three cases. *J Am Acad Dermatol* 1987; 16:1259-1260.
7. Ziv R, Schewach-Millet M, Trau H. Discoid lupus erythematosus of the eyelids. *J Am Acad Dermatol* 1986; 15:112-113.
8. Kearns W, Wood W, Marchese A. Chronic cutaneous lupus involving the eye lid. *Ann Ophthalmol* 1982; 14:1009-1010.
9. Friler-Ofry VF, Isler Z, Hanau D, Godel V. Eyelid involvement as the presenting manifestation of discoid lupus erythematosus. *J Pediatr Ophthalmol Strabismus* 1979; 16:365-397.
10. Burge SM, Frith PA, Juniper RP, Wojnarowska F. Mucosal involvement in systemic and chronic cutaneous lupus erythematosus. *Br J Ophthalmol* 1989; 121:727-741.
11. Anderson HE, Musgrave DP. Lupus erythematosus of the conjunctiva and lid margin. *Arch Dermatol Syph* 1949; 59:247-248.
12. Klauder JV, DeLong P. Lupus erythematosus of the conjunctiva, eyelids, and lid margins. *Arch Ophthalmol* 1932; 7:856-867.
13. DeLong P, Klauder JV. Lupus erythematosus of the eyelids and conjunctiva. *Arch Ophthalmol* 1932; 16:321-322.
14. Vilanova VX, Cardenal C, Capdevila JM. Chronischer lupus erythematosus der conjunctiva. *Dermatologica* 1956; 113:226-231.
15. Griffith MR, Fukuyama K, Tuffanelli D, Silverman S. Immunofluorescent studies in mucous membrane pemphigoid. *Arch Dermatol* 1974; 109:195-199.
16. Lever WF, Schaumburg-Lever G. Connective tissue diseases. In: Lever WF, Schaumburg-Lever G, editors. *Histopathology of the skin*. London: JB Lippincott, 1983:445-471.
17. Sontheimer RD, Rothfield N, Gilliam JN. Lupus erythematosus. In: *Dermatology in general medicine*. 3rd ed. New York: McGraw-Hill, 1987:chap 152.
18. Ogawa K. Ultrastructure of cutaneous lesions in lupus erythematosus: a comparison between the cutaneous and systemic types. *J Dermatol* 1981; 8:175-186.
19. Duke-Elder S. The ocular adnexa. In: *Systems of ophthalmology*. St. Louis, MO: CV Mosby, 1974:322-325.
20. Valenzuela R, Bergfeld WF, Deodhar SD. Lupus erythematosus: immunohistopathology. In: *Interpretation of immunofluorescent patterns in skin diseases*. Chicago, IL: American Society of Clinical Pathologists Press, 1984.
21. Schreiner E, Wolff K. Systemic lupus erythematosus: electron microscopic localization of in vivo bound globulins at the dermal-epidermal junction. *J Invest Dermatol* 1970; 55:325-328.
22. Wolff-Schreiner E, Wolff K. Immunoglobulins at the dermal-epidermal junction in lupus erythematosus: ultrastructural investigations. *Arch Dermatol Forsch* 1973; 246:193-210.
23. Harriest TJ, Mihm MC. Cutaneous immunopathology. The diagnostic use of direct and indirect immunofluorescence techniques in dermatologic disease. *Hum Pathol* 1979; 10:625-653.
24. Frith P, Burge SM, Millard PR, Wojnarowska F. External ocular findings in lupus erythematosus: a clinical and immunopathological study. *Br J Ophthalmol* 1990; 74:163-167.
25. Provost TT. Lupus erythematosus. In: Provost TT, Farmer ER, editors. *Current therapy in dermatology*. Philadelphia, PA: BC Decker, 1985.
26. Furey N, West C, Andrews T, Paul PD, Bean SF. Immunofluorescent studies of ocular cicatricial pemphigoid. *Am J Ophthalmol* 1975; 80:825-831.
27. Fine JD, Neises GR, Katz SI. Immunofluorescence and immunoelectron microscopic studies in cicatricial pemphigoid. *J Invest Dermatol* 1984; 82:39-43.
28. Leonard JN, Hobday CM, Haffenden GP, et al. Immunofluorescent studies in ocular cicatricial pemphigoid. *Br J Dermatol* 1988; 118:209-217.
29. Venning VA, Frith PA, Bron AJ, Millard PR, Wojnarowska F. Mucosal involvement in bullous and cicatricial pemphigoid. A clinical and immunopathological study. *Br J Dermatol* 1988; 118:7-15.
30. Mondino BJ, Ross AN, Rabin BS, Brown SI. Autoimmune phenomena in ocular cicatricial pemphigoid. *Am J Ophthalmol* 1977; 83:443-450.
31. Foster CS, Wilson LA, Ekins MB. Immunosuppressive therapy for progressive ocular cicatricial pemphigoid. *Ophthalmology* 1982; 89:340-353.
32. Proia AD, Foulks GN, Sanfilippo FP. Ocular cicatricial pemphigoid with granular IgA and complement deposition. *Arch Ophthalmol* 1985; 103:1669-1672.
33. Nieboer C, Boersma DM, Woerdeman MJ. Immunoelectron microscopic findings in cicatricial pemphigoid: their significance in relation to epidermolysis bullosa acquisita. *Br J Dermatol* 1982; 106:419-422.
34. Person JR, Rogers RS. Bullous and cicatricial pemphigoid. Clinical, histopathologic, and immunopathologic correlations. *Mayo Clin Proc* 1977; 52:54-66.
35. Korman N. Pemphigus. *J Am Acad Derm* 1988; 18:1219-1238.
36. Fitzmaurice M. The immunopathology of pemphigus vulgaris: recent advances. *Cleve Clin Q* 1986; 53:283-289.
37. Lam S, Stone MS, Goeken JA, et al. Paraneoplastic pemphigus, cicatricial conjunctivitis, and acanthosis nigricans with pachydermatoglyphy in a patient with bronchogenic squamous cell carcinoma. *Ophthalmology* 1992; 99:108-113.
38. Sontheimer RD, Fine JD. Biology of the dermal-epidermal interface and the pathophysiology of bullous pemphigoid, epidermolysis bullosa acquisita, and lupus erythematosus. In: Soter NA, Baden HP. *Pathophysiology of dermatologic diseases*. 2nd ed. New York: McGraw-Hill, 1991:chap 19.
39. Millard LG, Rowell NR. Abnormal laboratory test results and their relationship to prognosis in discoid lupus erythematosus. *Arch Dermatol* 1979; 115:1055-1058.
40. Grossman J, Callera ML, Condemi JJ. Skin immunofluorescence studies on lupus erythematosus and other antinuclear antibody-positive diseases. *Ann Intern Med* 1974; 80:496-500.
41. Burge M, Frith PA, Millard PR, Wojnarowska F. The lupus band test in oral mucosa, conjunctiva, and skin. *Br J Dermatol* 1989; 121:743-752.

To earn CME Category I credit, see test on p. 240

