

DAVID L. LONGWORTH, MD, AND JAMES K. STOLLER, MD, EDITORS

## Chest pain in a patient with congenital heart disease

**A** 25-YEAR-OLD WOMAN who had undergone repair of a coarctation of the aorta at age 12 presents for evaluation of severe chest pain on the left side that radiates to the upper left shoulder and hand.

**1** What other cardiac abnormality is associated with coarctation of the aorta?

- Aortic stenosis
- Bicuspid aortic valve
- Sinus of Valsalva aneurysms
- Aortic insufficiency
- Mitral stenosis

Coarctation of the aorta is most commonly associated with a bicuspid aortic valve, as well as patent ductus arteriosus and ventricular septal defect. Endocardial fibroelastosis has been reported, and there is an association between coarctation and anomalies of the mitral valve.

The patient takes birth-control pills and prophylactic antibiotics. She is one of 10 children, the product of a normal pregnancy, and none of her siblings has congenital heart disease.

**2** A woman with congenital heart disease has what chance of having an affected child?

- None
- 5%
- 20%
- 30%

The chances of passing on an inherited abnormality range from 5% to 50%, depending on which congenital heart disease the person has. Marfan's syndrome or hypertrophic obstructive cardiomyopathy can have a 50% likelihood of inheritance, while atrial septal defects, ventricular septal defects, coarctation, and most congenital anomalies have a 5% chance of inheritance. Although coarctation is not X-linked, there is a predilection for it in males.

On physical examination, the blood pressure is 118/84 mm Hg in the right arm, 112/84 mm Hg in the left. There are no heart murmurs, but there is a soft ejection click. The abdomen and the extremities are normal.

**3** What would be a characteristic finding on physical examination for coarctation of the aorta?

- Fixed splitting of S2
- Diastolic rumble at the apex
- Differential cyanosis between arms and legs
- Abnormal differences in upper and lower extremity pulses

The hallmark physical finding is lower blood pressure in the legs than in the arms, which is accentuated with exercise (evaluated by simultaneous palpation of the brachial and femoral pulses). Uncomplicated coarctation is not a cause of cyanosis of the lower extremities. Differential cyanosis indicates a reversed shunt through an existing patent ductus arteriosus distal to the coarctation. Fixed splitting of S2 is characteristic of an atrial septal defect; a diastolic rumble is heard in mitral stenosis.

A chest roentgenogram and magnetic resonance imaging (MRI) scan were obtained and are shown in *Figures 1 and 2*, respectively.

**4** The chest roentgenogram and MRI scan are most consistent with which diagnosis?

- Recurrent aortic coarctation
- Poststenotic dilatation of the aorta
- Normal postoperative state
- Pseudoaneurysm of the thoracic aorta

During follow-up of patients who have undergone coarctation repair, the coarctation can recur (67% in some series, not all requiring repeat surgery) or an aneurysm can form. The abnormality on this patient's chest roentgenogram is more than "post-stenotic dilation." The MRI suggests pseudoaneurysm of the aorta in the area of the patch annuloplasty. This is not uncommon; in one study of 152 patients who underwent patch annuloplasty repair, 35% had significant dilation and 19.5% required a repeat operation.

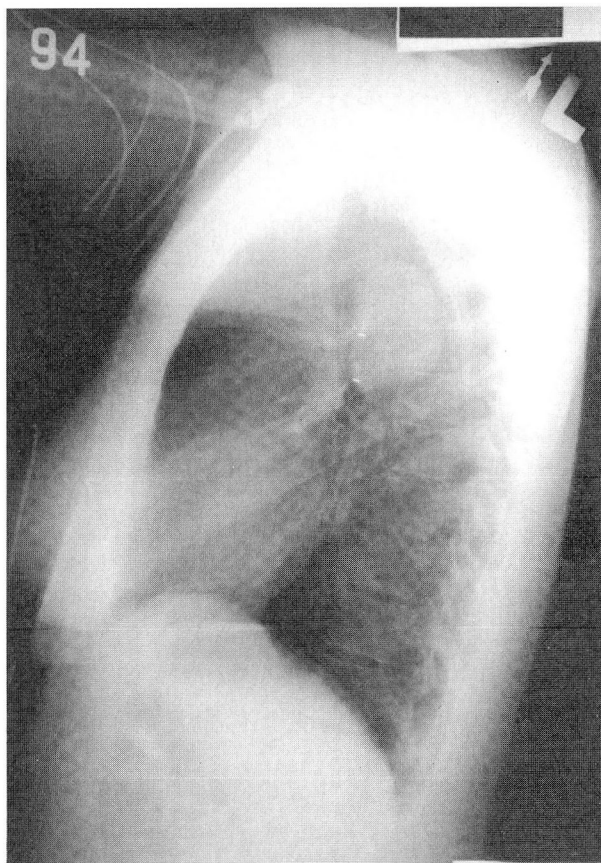
**5** What is the most common noncardiac anomaly in patients with coarctation of the aorta?

- Asplenia
- Circle of Willis aneurysm
- Renal artery stenosis
- Pulmonary hypertension

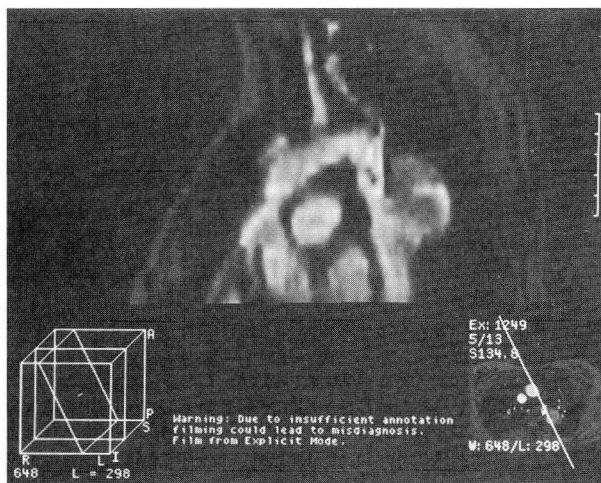
Circle of Willis aneurysms are found in 10% of patients with coarctation. It may be clinically silent or manifest as abrupt rupture.

#### DISCUSSION

This case illustrates the need to be aware of problems in adult patients with repaired congenital heart defects. Coarctation of the aorta accounts for 15% of adult congenital heart abnormalities. There is a male predominance, and one third have a bicuspid aortic valve. Symptoms include headache, epistaxis, forceful carotid impulses, and lower extremity claudication. Two thirds of patients with untreated coarctation develop congestive heart failure as adults. A cerebrovascular accident can occur in 20% of cases.



**FIGURE 1.** Chest roentgenogram in a 25-year-old woman with chest pain who had undergone repair of a coarctation of the aorta 13 years previously.



**FIGURE 2.** Magnetic resonance imaging scan in the same patient.

# CLEVELAND CLINIC JOURNAL OF MEDICINE



## UPCOMING FEATURES

*Perioperative  
management of  
common medical  
conditions*

*Coronary heart disease  
in African Americans:  
primary and secondary  
prevention*

*An update  
on prostate cancer*

### INTERNAL MEDICINE BOARD REVIEW

Clinically, the hallmark is a discrepancy in pulses, the pressure in the arms being greater than the legs, a difference often accentuated after exercise.

Electrocardiographic findings are nonspecific until the third or fourth decade, when left ventricular hypertrophy develops in untreated patients. Roentgenography of the chest can be diagnostic. An indentation followed by a poststenotic dilation of the aorta is known as the "three sign." An important finding is rib notching, because the more severe the coarctation, the more developed are the collaterals.

Intervention should be undertaken before the patient reaches school age to decrease mortality. Balloon aortoplasty is an option, but it carries the risk of late aneurysm, which may be lessened with placement of a metallic stent. Surgical repair requires preoperative assessment of adequate collateral circulation to permit safe aortic cross-clamping without the risk of spinal-cord ischemia. Postoperative prophylaxis against subacute bacterial endocarditis should continue for life.

ANITA M. ARNOLD, DO  
Milwaukee Cardiology Associates

### SUGGESTED READING

Aebert H, Laas J, Bednarski P, Koch U, Prokop M, Borst HG. High incidence of aneurysm formation following patch plasty repair of coarctation. *Eur J Cardiothorac Surg* 1993; 7:200-204.

Kappetein PA, Guit GL, Bogers AJ, et al. Noninvasive long-term follow-up after coarctation repair. *Ann Thorac Surg* 1993; 55:1153-1159.

Liberthson RR. *Congenital heart disease diagnosis and management in children and adults*. Boston: Little, Brown, and Co., 1989.