

# Current status of stress echocardiography in the diagnosis of coronary artery disease

THOMAS MARWICK, MD

**SUMMARY** Stress echocardiography is a cost-effective and reliable diagnostic test for patients with suspected coronary artery disease.

**KEY POINTS** Stress echocardiography should be used in preference to exercise electrocardiography as the primary test in patients with uninterpretable ST segments. It is attractive for use as the primary test in patients with coexisting valvular disease. It probably is the optimal test for women. Stress echocardiography should be used as a secondary test when the result of exercise electrocardiography is inconsistent with the clinical status. In patients requiring nonexercise stress testing, an imaging test is mandatory. The ability of stress echocardiography to identify the location and extent of myocardial ischemia makes it appropriate in situations where decisions regarding revascularization will be made on these grounds. The overall accuracy of stress echocardiography and perfusion scintigraphy is comparable in expert hands, but one must always consider the expertise of the operator and the quality of each test in the environment in which it is performed.

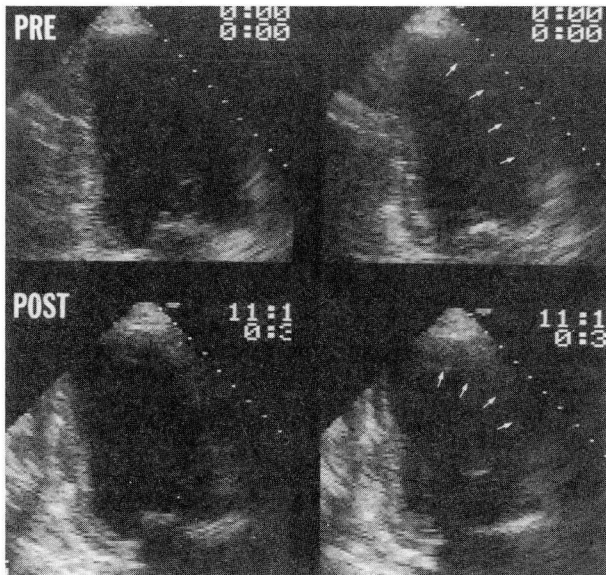
**INDEX TERMS:** ECHOCARDIOGRAPHY; EXERCISE TEST; CORONARY DISEASE  
CLEVE CLIN J MED 1995; 62:227-234

From the Department of Cardiology, The Cleveland Clinic Foundation.  
Address reprint requests to T.M., Department of Cardiology, F15, The Cleveland Clinic Foundation, 9500 Euclid Avenue, Cleveland, OH 44195.

**S**TRESS echocardiography is now an accepted test for diagnosing coronary artery disease. This article considers its use in routine clinical practice and discusses strengths and shortcomings that the ordering physician needs to know about. We outline the principles of stress echocardiography and analyze its feasibility and practical considerations, its accuracy for diagnosing significant coronary stenoses, and its role in relation to other noninvasive tests.

## PRINCIPLES

Echocardiography is able to detect regional left ventricular dysfunction that develops in myocardium that has become ischemic in response to stress (*Figure*). Ischemic regional myocardial dysfunction is an early event in the "ischemic cascade,"<sup>1</sup> upon which the whole rationale of cardiac stress imaging is based. In contrast, the standard clinical markers of myocardial ischemia—angina and ischemic ST-segment depression—usually occur after prolonged stress



**FIGURE.** Freeze-frame images of the left ventricle in diastole (on the left) and systole (on the right) before exercise (above) and following exercise (below) in a quad-screen display. Resting wall motion is normal; after stress, the anteroseptal wall fails to contract (arrows), consistent with the development of myocardial ischemia.

and at a high level of cardiac work (measured as the rate-pressure product). These late events are preceded by regional dysfunction and perfusion defects, which themselves are preceded by flow heterogeneity.

#### FEASIBILITY AND PRACTICAL ISSUES

The images shown in the *Figure* are deceptive in that they do not illustrate the skills required to adequately perform stress echocardiography and interpret the results. The performance of stress echocardiography mandates the availability of a good two-dimensional echocardiography machine, a device for digitizing the echocardiographic images, a stress system able to control this digitizing device, a trained technician, and an expert observer. In practical terms, the referring physician must first select the stressor, ie, either exercise or a pharmacologic stressor, each of which has various alternatives. Of the former, bicycle stress is the most sensitive for detecting coronary artery disease, as it permits the acquisition of images at peak stress. (Ischemia may resolve rapidly after stress.) However, it has the disadvantage of being technically more difficult than

treadmill studies. Of the pharmacologic stressors, dobutamine is the optimal agent. A comparison of dobutamine and the vasodilators adenosine and dipyridamole is presented below.

One of the benefits of using echocardiography (in preference to the other stress imaging tests) is the ability to examine cardiac structure and function before stress using M-mode and Doppler techniques. However, there is often too little time for a complete Doppler study within the confines of a standard stress echocardiography schedule; patients with complex valvular problems may need special arrangements for a full resting study. Electrodes are positioned for stress electrocardiography (ECG) in the usual fashion and may be adjusted out of the echocardiographic windows if required. After stress, images should be acquired as rapidly as possible, optimally in less than 1 minute. Satisfactory images should be obtainable in more than 95% of patients.<sup>2</sup>

Once the quad-screen image has been acquired, the next task is to identify the presence of normal, ischemic, or infarcted myocardium.<sup>3</sup> In general, this is currently performed by qualitatively comparing wall motion at rest and under stress using the algorithm shown in *Table 1*.

Normal myocardium is characterized by normal function at rest and augmented function after stress. There is some heterogeneity of contraction in the normal heart, and normal segments may be hypokinetic at rest; such hypokinetic areas should improve with maximal stress (though this may not be true with pharmacologic or submaximal exercise stress).

Ischemic myocardium is characterized by normal function at rest and some degree of deterioration after stress. Classically, deterioration of function has been used as the hallmark of ischemia; more subtle indices include failure to improve and delayed contraction, both of which are more readily appreciated using the side-by-side comparison available with the digital technique. Finally, and usually in the presence of severe or extensive coronary artery disease, the global function of the left ventricle deteriorates, with a reduction of ejection fraction and increasing systolic volumes.

Infarction is identified if a segment shows akinesis or dyskinesis at rest. These patterns do not, however, preclude the presence of viable myocardium, which may be identified by improvement of regional function in response to low-dose dobutamine stress. In contrast, a truly akinetic area that appears to improve after exercise most likely reflects visualization

of adjacent segments or rotational and translational cardiac movement.

This qualitative system of evaluation has been criticized for being overly subjective, and attempts have been made to standardize the grading of wall motion and the segments in which wall motion is evaluated. One such method is the 16-segment model adopted by the American Society of Echocardiography, in which various degrees of abnormal movement are scored in proportion to the severity of wall-motion disturbance.<sup>4</sup> The importance of the learning curve in this subjective assessment cannot be overrated. While the length and content of the optimal training period are ill defined, data obtained using pharmacologic stress echocardiography suggest that it should comprise about 100 supervised studies.<sup>5</sup>

Apart from being subjective, this method has a number of other shortcomings. Image quality is obviously critically important, and for the study to be meaningful, comparisons need to be made in the same imaging planes. There may be particular problems after a myocardial infarction: first, because abnormal regional wall motion adjacent to the infarct site after stress may be a manifestation of ischemia or "tethering," and second, because left ventricular dysfunction at rest is not necessarily synonymous with infarction.

Stress echocardiography offers a wealth of diagnostic information that is not limited to the presence or absence of myocardial ischemia. Resting images may provide important diagnostic information independent of the presence or absence of coronary artery disease, such as the presence of pericardial disease, hypertrophic cardiomyopathy, or valvular disease. The presence or absence of stress-induced wall-motion abnormalities, the extent and severity of these abnormalities, the time of onset during stress, and their duration after stress are all indices of the severity of coronary artery disease. The site of coronary stenoses may also be identified. Finally, global left ventricular function may be evaluated either qualitatively or quantitatively at rest and during stress.

**TABLE 1**  
CRITERIA FOR THE QUALITATIVE EVALUATION OF STRESS ECHOCARDIOGRAPHY

Diagnosis	Resting function	Peak and post-stress function
Normal	Normal	Hyperkinetic or normal (depending on stress)
Ischemic	Normal	Reduction vs rest Reduction vs other hyperkinetic segments Delayed contraction
	Hypokinetic	Reduction compared with rest
Infarction	Akinetic or dyskinetic	Not interpretable

#### ACCURACY OF EXERCISE ECHOCARDIOGRAPHY

The sensitivity of exercise echocardiography is calculated as the proportion of patients with "significant" coronary artery disease (generally defined as > 50% stenosis in one or more major coronary vessels) who have abnormal test results. Specificity relates to the number of patients without significant coronary artery disease who have normal test results. *Table 2* documents these values in several large studies.<sup>6-11</sup>

The sensitivity of echocardiography after treadmill exercise at The Cleveland Clinic Foundation, reported in 1991, was 84% overall and 80% among patients with coronary artery disease without previous infarction.<sup>8</sup> In single-vessel disease, the sensitivity was 81% overall and 68% in those without previous infarction; in multivessel disease the sensitivities were 87% and 96%, respectively. In the overall group, the specificity was 86% and the accuracy was 85%; in those without infarction, the accuracy was 81%.

Incorrect results are not readily predictable on the basis of patient population or test variables: age, sex, weight, and medical therapy have no impact on the accuracy of the test. False-negative results may occur in patients who undergo submaximal stress (achieving < 85% of the predicted maximal heart rate), and those with moderate (50% to 70%) coronary stenoses and single-vessel disease. Other widely discussed causes of false-negative studies are the presence of stenoses that do not limit flow, operator inexperience, delay in imaging after exercise, anti-anginal medication, and inadequate images after exercise.

Although the sensitivity for detecting coronary artery disease was greater in patients with multivessel disease in our study, the ability to predict the

**TABLE 2**  
ACCURACY OF EXERCISE ECHOCARDIOGRAPHY  
FOR DIAGNOSING CORONARY ARTERY DISEASE (> 50% STENOSIS) IN LARGE STUDIES\*

Author	Technique <sup>†</sup>	Number of patients				Sensitivity, %			Specificity, %
		Overall	With CAD <sup>‡</sup>	With SVD <sup>§</sup>	Without MI <sup>  </sup>	Overall	With SVD	Without MI	
Armstrong, 1987 <sup>6</sup>	Treadmill	123	101	42	51	88	81	78	86
Crouse, 1991 <sup>7</sup>	Treadmill	228	175	66	—	97	92	—	64
Marwick, 1992 <sup>8</sup>	Treadmill	150	114	60	59	84	77	80	86
Quinones, 1992 <sup>9</sup>	Treadmill	112	86	41	—	74	58	—	81
Hecht, 1993 <sup>10</sup>	Supine bicycle	180	137	55	82	93	84	100	86
Ryan, 1993 <sup>11</sup>	Upright bicycle	309	211	85	126	91	86	95	78

\*Adapted in part from Marwick T. Stress echocardiography. Boston: Kluwer, 1994, with permission

<sup>†</sup>All studies used image digitization

<sup>‡</sup>Coronary artery disease

<sup>§</sup>Single-vessel disease

<sup>||</sup>Myocardial infarction

presence of multivessel disease as such varied according to whether the patients had previous infarction. In the 26 patients with previous infarction, multivessel disease was correctly recognized as such in 81%, showing that stress echocardiography is effective in identifying "ischemia at a distance." In contrast, in those without previous infarction, the presence of multivessel disease was predicted correctly in only 50%. The latter reflects two phenomena: observers tend to concentrate on the most abnormal segment, and ischemic symptoms arising from one stenosis limit exercise before a significant wall-motion abnormality caused by another stenoses becomes apparent.

The only avoidable causes of false-negative stress echocardiograms are delay in imaging after exercise and submaximal exercise. Patients who are either unable to exercise or likely to exercise submaximally should undergo nonexercise stress. These nonexercise protocols include pharmacologic, pacing, and physiologic stimuli (such as the cold-pressor test); the pharmacologic stimuli are the best tolerated in our experience.

#### PHARMACOLOGIC STRESS ECHOCARDIOGRAPHY

The pharmacologic agents include dobutamine (a beta-sympathomimetic agonist that simulates exercise by increasing the heart rate and blood pressure) and the coronary vasodilators dipyridamole and adenosine (which provoke perfusion heterogeneity but less commonly cause ischemic wall-mo-

tion abnormalities). The side effects limiting the completion of these protocols are similar<sup>12</sup>; in the case of adenosine, approximately one third of tests are terminated prematurely, most commonly because of dyspnea or symptomatic hypotension. The dobutamine test is terminated prematurely less frequently, most commonly because of asymptomatic hypotension, arrhythmias, and hypertension. Compared with vasodilators, dobutamine causes a significantly greater increase in peak heart rate, systolic blood pressure, and rate-pressure product. Because dipyridamole provokes lower cardiac work loads, vasodilator stress echocardiography is significantly less sensitive than dobutamine echocardiography (Table 3).<sup>12-19</sup> As there is no significant difference in specificity between these agents, the Department of Cardiology at the Cleveland Clinic performs pharmacologic stress testing only with dobutamine.

Pharmacologic stress echocardiography is technically less challenging than the exercise techniques because the patient is stationary, and for this reason there has been considerable interest in using it in preference to exercise testing. However, exercise constitutes a significantly more vigorous hemodynamic stress than does dobutamine, manifested as a higher heart rate, blood pressure, and rate-pressure product. Although there is no significant difference in specificity between the two tests, the sensitivity of dobutamine testing is comparable to that of exercise echocardiography only in patients who receive maximal doses of dobutamine or attain an ischemic endpoint.<sup>20,21</sup> Exercise echocardiography is substan-

**TABLE 3**  
SENSITIVITY AND SPECIFICITY OF ECHOCARDIOGRAPHY WITH PHARMACOLOGIC STRESS\*

Author	Technique <sup>†</sup>	Significant stenosis, %	Number of patients			Sensitivity, %		Specificity, %
			Overall	With CAD <sup>‡</sup>	With SVD <sup>§</sup>	Overall	With SVD	
Marwick, 1993 <sup>12</sup>	Adenosine 0.18 µg/kg/min	> 50	97	59	31	58	52	87
Picano, 1986 <sup>13</sup>	Dipyridamole 0.84 mg/kg	> 70	93	72	12	74	50	100
Mazeika, 1991 <sup>14</sup>	Dipyridamole 1.0 mg/kg	> 70	55	40	10	40	0	93
Marwick, 1993 <sup>15</sup>	Dobutamine 40 µg/kg/min	> 50	217	142	68	72	66	83
Marcowitz, 1992 <sup>16</sup>	Dobutamine 30 µg/kg/min	> 50	141	109	62	96	95	66
Mazeika, 1992 <sup>17</sup>	Dobutamine 20 µg/kg/min	> 70	50	36	12	78	50	93
Sawada, 1991 <sup>18</sup>	Dobutamine 30 µg/kg/min	> 50	103	81	38	95	89	77
Cohen, 1991 <sup>19</sup>	Dobutamine 40 µg/kg/min	> 70	70	51	16	86	69	95

\*Adapted from Marwick T. Stress echocardiography. Boston: Kluwer, 1994, with permission

<sup>†</sup>Low-dose positivity permits conclusion of study before stated "peak" dose

<sup>‡</sup>Coronary artery disease

<sup>§</sup>Single-vessel disease

tially more sensitive than dobutamine echocardiography in patients treated with beta blockers or unable to conclude the test. Indeed, even in patients who have a positive test by both techniques, the extent of wall-motion abnormality is significantly greater during exercise than during dobutamine testing.<sup>20</sup> Thus, even though the image quality of dobutamine echocardiography may be better than that of exercise echocardiography, the diagnostic certainty of the observer may be lower, owing to the smaller area of ischemia in these positive tests.

#### COMPARISON OF STRESS ECHOCARDIOGRAPHY WITH STRESS ECG

ST-segment depression during stress is the standard clinical criterion for myocardial ischemia, but the wide acceptance of stress ECG should not hide its limitations. Many patients have repolarization abnormalities that make the electrocardiogram uninterpretable, while others cannot exercise maximally. Indeed, patients who exercise maximally and have interpretable ST segments may account for only 35% of patients referred to some exercise laboratories at tertiary care hospitals.<sup>22</sup> We should consider these groups separately in comparing exercise echocardiography with exercise ECG. An uninterpretable stress electrocardiogram is already accepted as a standard indication for a stress imaging test,<sup>6</sup> and this will not be discussed further in this review. Stress ECG is particularly difficult in women, who frequently have false-positive results.<sup>23</sup> Stress echo-

cardiography does not share this inaccuracy,<sup>24</sup> but whether stress echocardiography can be justified as the test of first choice in all women with suspected coronary artery disease remains to be determined.

Largely because of referral bias, the reported accuracy of stress ECG varies widely. In men, both sensitivity and specificity show average values of about 73%; in women, the average sensitivity is 65% and the specificity is 71%.<sup>25</sup> In our experience,<sup>8</sup> even after excluding patients with myocardial infarction and nondiagnostic stress electrocardiograms, the sensitivity of exercise ECG was 63%, significantly lower than that of exercise echocardiography (87%). The specificity of exercise ECG was somewhat lower, ie, 74% compared with 82% for exercise echocardiography, but in this population the difference did not reach statistical significance. The accuracy was also significantly less. These results are consistent with others in the literature, showing a significantly better sensitivity with exercise echocardiography as well as a trend to higher specificity, which did not reach statistical significance in individual studies because of smaller population numbers.

In patients who undergo pharmacologic stress testing because they cannot exercise, stress ECG is insensitive for coronary artery disease. In 120 patients with interpretable stress electrocardiograms who underwent two-dimensional echocardiography and technetium-99m-methoxyisobutyl isonitrile (MIBI) scintigraphy in addition to ST-segment evaluation, the sensitivity of stress ECG was signifi-

**TABLE 4**

COMPARISON OF SENSITIVITY AND SPECIFICITY OF ECHOCARDIOGRAPHY AND MYOCARDIAL PERFUSION IMAGING AFTER VARIOUS STRESSORS FOR DETECTING CORONARY ARTERY DISEASE\*

Author	Technique	Nuclide	Number of patients			Overall sensitivity, %		Sensitivity in SVD, ‡ %		Overall specificity, %	
			Overall	With CAD <sup>†</sup>	With SVD <sup>‡</sup>	Echo	Nuclear	Echo	Nuclear	Echo	Nuclear
Quinones, 1992 <sup>9</sup>	Treadmill	Thallium	112	86	41	74	76	58	61	88	81
Marwick, 1993 <sup>12,5</sup>	Adenosine	MIBI <sup>  </sup>	97	59	31	58	86	52	81	87	71
Marwick, 1993 <sup>15,5</sup>	Dobutamine	MIBI	217	142	68	72	76	66	74	83	67
Pozzoli, 1991 <sup>28,  </sup>	Upright bicycle	MIBI	75	49	33	71	84	60	82	96	88
Hecht, 1993 <sup>29</sup>	Supine bicycle	Thallium	71	51	22	90	92	77	95	80	65

\*All studies used &gt; 50% stenosis as the criterion for coronary artery disease, and all studies used single-proton emission computed tomography; adapted from Marwick T. Stress echocardiography. Boston: Kluwer, 1994, with permission

<sup>†</sup>Coronary artery disease<sup>‡</sup>Single-vessel disease<sup>§</sup>Excluded patients with previous myocardial infarction<sup>||</sup>Technetium-99m-methoxyisobutyl isonitrile<sup>¶</sup>Excluded patients with abnormal resting electrocardiographic findings

cantly lower than that of the imaging tests in patients with coronary artery disease of all degrees of severity.<sup>26</sup> However, the specificity of stress ECG was high, a pattern that may suggest the use of inappropriate diagnostic criteria. In order to determine whether other criteria should be used during dobutamine stress, we investigated various ST-segment criteria, using receiver operating curve analysis to determine the ST-segment level giving the optimal sensitivity and specificity. Unfortunately, no other cutoff offered substantially greater sensitivity.

To conclude, exercise echocardiography should be used in preference to exercise ECG as the primary test in patients with uninterpretable ST segments. It is attractive for use as the primary test in patients with coexistent valvular disease, and it probably is the optimal test for women, although the acceptance of this conclusion will need further data. It should be used as a secondary test when the exercise ECG result is inconsistent with the clinical status. In patients requiring nonexercise stress testing, an imaging test is mandatory. Finally, the ability of stress echocardiography to identify the location and extent of myocardial ischemia makes it appropriate in situations where decisions regarding revascularization will be made on these grounds.

#### STRESS ECHOCARDIOGRAPHY VS PERFUSION SCINTIGRAPHY

The place of stress echocardiography in relation to nuclear stress imaging techniques in the investigation of coronary artery disease remains controversial. An observation of overwhelming importance in this respect is that although there is less reported variation regarding the sensitivity and specificity of perfusion scintigraphy than there is for exercise ECG, there are nonetheless important variations,<sup>27</sup> which relate not only to patient referral but also to the quality of the test and its interpretation. Both tests should be interpreted by experts for comparisons between stress echocardiography and nuclear studies to be meaningful. The corollary of this statement is that good, comparative studies between the techniques are not applicable to clinical practice unless the appropriate expertise is available to provide data of similar quality.

Comparisons of stress echocardiography and perfusion scintigraphy, performed by groups who have expertise in both tests, are summarized in Table 4.<sup>9,12,15,28,29</sup> The sensitivity of stress echocardiography is comparable to that of perfusion scintigraphy, the only exception being a marked inferiority of vasodilator stress echocardiography compared with

perfusion scintigraphy, which reflects the inadequacies of vasodilator stress for echocardiography discussed above. The slightly lower sensitivity of stress echocardiography as compared with perfusion scintigraphy in many studies may reflect a lower sensitivity for single-vessel disease, demonstrated to be statistically significant in one study.<sup>26</sup> The two tests have comparable sensitivity in patients with multivessel disease. These results are concordant with the initial discussion of the ischemic cascade: in the presence of single-vessel disease the amount of ischemia is small and a degree of flow heterogeneity is likely to be apparent using scintigraphic techniques before metabolic and wall-motion evidence of ischemia emerges.

Several studies show that echocardiography has greater specificity than does perfusion scintigraphy. Preliminary data suggest that in some subgroups of patients without coronary artery disease, stress echocardiography may have particular advantages. In 38 patients without myocardial infarction or significant coronary artery disease who underwent perfusion scintigraphy and stress echocardiography, the specificity of perfusion scintigraphy was significantly lower in patients with left ventricular hypertrophy or left bundle branch block than in those without these abnormalities, 50% vs 85%.<sup>12</sup> These findings are concordant with the results of separate studies, which show that perfusion scintigraphy has problems in identifying coronary artery disease in the setting of left ventricular hypertrophy that are not shared by stress echocardiography. Similarly, conduction defects pose problems for the specificity of exercise perfusion scintigraphy, but probably not stress echocardiography.

The results discussed above focus on the relative ability of echocardiography and perfusion scintigraphy to identify the presence of coronary artery disease. An equally important matter pertains to the ability of the two tests to differentiate myocardial ischemia and infarction—a more difficult analysis because segments demonstrating either abnormality are subtended by coronary stenoses, and no ready “gold standard” is available. In patients without resting wall-motion abnormalities, there is a high concordance between the findings of stress echocardiography and those of thallium imaging in detecting ischemic wall-motion abnormalities.<sup>9</sup> In contrast, in those with resting wall-motion abnor-

malities, there was discordance between the tests caused by diagnosis of ischemia by thallium imaging in many of these segments. Because of the difficulties in discerning minor degrees of change within dysfunctional segments, perfusion imaging may be a more accurate indicator of the presence of ischemia, but this issue remains to be resolved.

To summarize, the overall accuracy of both stress echocardiography and perfusion scintigraphy is comparable in expert hands. The sensitivity of perfusion scintigraphy may be greater than that of stress echocardiography, particularly in patients with single-vessel disease. However, the specificity is significantly greater with echocardiography, especially in the settings of left ventricular hypertrophy and left bundle branch block. Finally and probably most importantly, one must always consider the expertise of the operator and the quality of each test in the environment in which it is performed. Good scintigraphy can always be expected to be better than bad stress echocardiography, and conversely, good echocardiography can be expected to be better than bad scintigraphy.

## CONCLUSIONS

Although the growth of stress echocardiography as a clinical test was initially slow, its acceptance has grown recently, driven partly by cost considerations and partly by the technical developments that enhanced image quality. Its current form is probably not the zenith of its development; the technique continues to evolve, and future developments should reduce concerns about image quality and subjectivity. The next advancements are expected to improve edge detection, provide techniques for better analysis which may facilitate quantitation of results, and enable identification of ultrasonic signals of myocardial ischemia in addition to wall-motion abnormalities.

Currently, stress echocardiography is as imperfect as any of the stress imaging tests for the diagnosis of coronary artery disease. Its disadvantages are its technical challenge and subjectivity, but these are balanced by its specificity for ischemia and ability to examine other aspects of valvular function. On the basis of available data, stress echocardiography represents a cost-effective and reliable diagnostic test for patients with suspected coronary artery disease.

## REFERENCES

- Hauser AM, Vellappillil G, Ramos RG, et al. Sequence of mechanical, electrocardiographical and clinical effects of repeated coronary artery occlusion in human beings: echocardiographic observations during coronary angioplasty. *J Am Coll Cardiol* 1985; 5:193-197.
- Ginzton LE. Stress echocardiography and myocardial contrast echocardiography. *Cardiol Clin* 1989; 7:493-509.
- Marwick T, Salcedo EE, Stewart WJ. Exercise echocardiographic and Doppler evaluation of left ventricular function. *Am J Card Imaging* 1991; 5:281-290.
- Broderick T, Sawada S, Armstrong WF, et al. Improvement in rest and exercise-induced wall motion abnormalities after coronary angioplasty: an exercise echocardiographic study. *J Am Coll Cardiol* 1990; 15:591-599.
- Picano E, Lattanzi F, Orlandini A, Marini C, L'Abbate A. Stress echocardiography and the human factor: the importance of being expert. *J Am Coll Cardiol* 1991; 17:666-669.
- Armstrong WF, O'Donnell J, Ryan T, Feigenbaum H. Effect of prior myocardial infarction and extent and location of coronary disease on accuracy of exercise echocardiography. *J Am Coll Cardiol* 1987; 10:531-538.
- Crouse LJ, Harbrecht JJ, Vacek JL, Rosamond TL, Kramer PH. Exercise echocardiography as a screening test for coronary artery disease and correlation with angiography. *Am J Cardiol* 1991; 67:1213-1218.
- Marwick T, Nemec J, Pashkow F, Stewart WJ, Salcedo E. Accuracy and limitations of exercise echocardiography in a routine clinical setting. *J Am Coll Cardiol* 1992; 19:74-81.
- Quinones MA, Verani MS, Haichin RM, Mahmarian JJ, Suarez J, Zoghbi WA. Exercise echocardiography versus Tl-201 single photon emission computed tomography in evaluation of coronary artery disease. Analysis of 292 patients. *Circulation* 1992; 85:1026-1031.
- Hecht HS, DeBord L, Shaw R, et al. Digital supine bicycle stress echocardiography: a new technique for evaluating coronary artery disease. *J Am Coll Cardiol* 1993; 21:950-956.
- Ryan T, Segar DS, Sawada SG, et al. Detection of coronary artery disease with upright bicycle exercise echocardiography. *J Am Soc Echocardiogr* 1993; 6:186-197.
- Marwick T, Willemart B, D'Hondt AM, et al. Selection of the optimal non-exercise stress for the evaluation of ischemic regional myocardial dysfunction and malperfusion: comparison of dobutamine and adenosine using echocardiography and Tc-99m MIBI single photon emission computed tomography. *Circulation* 1993; 87:345-354.
- Picano E, Lattanzi F, Massini M, Distanti A, L'Abbate A. High dose dipyridamole echocardiography test in effort angina pectoris. *J Am Coll Cardiol* 1986; 8:848-854.
- Mazeika P, Nihoyannopoulos P, Joshi J, Oakley CM. Evaluation of dipyridamole-Doppler echocardiography for detection of myocardial ischemia and coronary artery disease. *Am J Cardiol* 1991; 68:478-484.
- Marwick T, D'Hondt A, Baudhuin T, et al. Optimal use of dobutamine stress for the detection and evaluation of coronary artery disease: combination with echocardiography, scintigraphy or both? *J Am Coll Cardiol* 1993; 22:159-167.
- Marcowitz P, Armstrong WF. Accuracy of dobutamine stress echocardiography in detecting coronary artery disease. *Am J Cardiol* 1992; 69:1269-1273.
- Maziaka PK, Nadazdin A, Oakley CM. Dobutamine stress echocardiography for detection and assessment of coronary artery disease. *J Am Coll Cardiol* 1992; 19:1203-1211.
- Sawada SG, Segar DS, Ryan T, et al. Echocardiographic detection of coronary artery disease during dobutamine infusion. *Circulation* 1991; 83:1605-1614.
- Cohen JL, Greene TO, Ottenweller J, Binenbaum SZ, Wilchfort SD, Kim CS. Dobutamine digital echocardiography for detecting coronary artery disease. *Am J Cardiol* 1991; 67:1311-1318.
- Marwick T, D'Hondt AM, Mairesse G, et al. Comparative ability of dobutamine and exercise stress in inducing myocardial ischemia in active patients. *Br Heart J* 1994; 72:31-38.
- Hoffmann R, Lethen H, Kleinhans E, Flachskampf FA, Hanrath P. Comparison of bicycle and dobutamine stress echocardiography for identification of coronary artery disease [abstract]. *Circulation* 1991; 84:II-476.
- Marwick T. Current status of non-invasive techniques for the diagnosis of myocardial ischemia. *Acta Clin Belg* 1992; 47:1-5.
- Sketch MH, Mohiuddin SM, Lynch JD, Zencka AE, Runco V. Significant sex differences in the correlation of electrocardiographic exercise testing and coronary arteriograms. *Am J Cardiol* 1975; 36:169-173.
- Sawada SG, Ryan T, Fineberg NS, et al. Exercise echocardiographic detection of coronary artery disease in women. *J Am Coll Cardiol* 1989; 14:1440-1447.
- Detrano R, Froelicher VF. Exercise testing: uses and limitations considering recent studies. *Prog Cardiovasc Dis* 1988; 31:173-204.
- Mairesse G, Marwick T, D'Hondt AM, Wyns W, Melin JA, Detry JM. How reliable is the dobutamine stress ECG for the diagnosis of coronary disease? A receiver operating curve analysis [abstract]. *J Am Coll Cardiol* 1993; 21:174A.
- Kotler TS, Diamond GA. Exercise thallium-201 scintigraphy in the diagnosis and prognosis of coronary artery disease. *Ann Intern Med* 1990; 113:684-702.
- Pozzoli MM, Fioretti PM, Salustri A, Reijs AE, Roelandt JR. Exercise echocardiography and technetium-99m MIBI single photon emission computed tomography in the detection of coronary artery disease. *Am J Cardiol* 1991; 67:350-355.
- Hecht HS, DeBord L, Shaw R, et al. Supine bicycle stress echocardiography versus tomographic thallium-201 exercise imaging for the detection of coronary artery disease. *J Am Soc Echocardiogr* 1993; 6:177-185.