

DAVID L. LONGWORTH, MD, AND JAMES K. STOLLER, MD, EDITORS

A 47-year-old woman with a swollen leg

A 47-YEAR-OLD WOMAN presents to the emergency department with intermittent right knee pain and leg swelling. Three weeks previously, after a plane trip to Europe, she had noted the acute onset of right calf and knee pain with calf swelling. She was hospitalized in France and treated initially with heparin for a presumed deep venous thrombosis (DVT). Plethysmographic (IPG) studies were inconclusive, and a venogram performed 5 days later demonstrated patent veins. She recalled having arthralgia during an episode of the "flu" the previous summer, but denied previous episodes of leg pain, joint pain, swelling, or trauma. Physical examination revealed swelling and warmth in the right calf. There was a minimally tender bulge in the popliteal fossa and an ecchymosis below the right lateral malleolus. There was no fever, joint effusion, or joint laxity.

DIAGNOSIS

1 Which of the following should be included in the differential diagnosis?

- ☐ Deep venous thrombosis
- ☐ Superficial thrombophlebitis
- ☐ Gastrocnemius tear
- ☐ Plantaris muscle tear
- ☐ Popliteal cyst

The acute onset of painful swelling in one calf can present a diagnostic dilemma (Table 1). Consideration must be given to all of the possibilities listed

above, although superficial thrombophlebitis does not usually cause significant distal edema.

The most serious acute problem would be a proximal DVT (with the attendant risk of pulmonary embolism). Duplex ultrasonography or IPG can be used as the initial diagnostic study in confirming this diagnosis. Venography can demonstrate thrombosis in cases of high clinical suspicion in which noninvasive studies were negative, and has greater sensitivity than ultrasonography for thrombosis limited to the calf. However, given the cost and discomfort associated with venography, it is generally reserved for more complex cases if noninvasive studies are available. The preferred treat-

TABLE 1
CAUSES OF UNILATERAL LEG SWELLING

Lymphatic or venous obstruction or damage
Radiation injury
Infection
Previous inguinal procedures
Tumor
Venous insufficiency
Deep venous thrombosis
Popliteal cyst
Popliteal aneurysm
Gastrocnemius muscle tear
Plantaris muscle tear
Soleus muscle tear
Necrotizing fasciitis
Cellulitis
Hematoma
Benign or malignant neoplasm

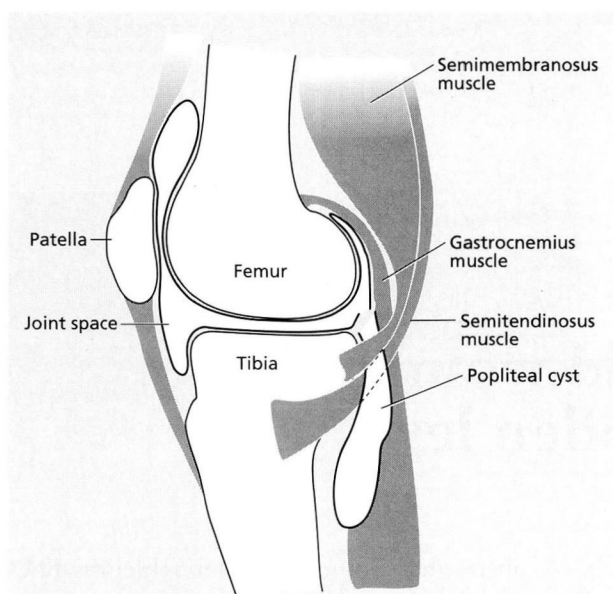


FIGURE. Location of a popliteal cyst.

ment for uncomplicated proximal DVT consists of initial anticoagulation with heparin followed by at least 3 months of oral warfarin therapy. Treatment of superficial thrombophlebitis consists of primarily local measures such as leg elevation, heat, and, perhaps, aspirin.

Rupture of the gastrocnemius or plantaris muscles can cause pain and swelling of the lower extremity. Patients often describe a sharp, knife-like pain in the calf upon standing or taking a sudden step. The pain may change to become a constant aching, exacerbated by movement. These symptoms can occur with either complete muscle tears or partial tears, either of which may be associated with local hemorrhage. The treatment is initially conservative and includes rest, ice, elevation of the affected leg, and limited weight-bearing. Localized muscle tenderness to palpation, often with ecchymosis, is common. Magnetic resonance imaging (MRI), which can visualize soft tissue, will confirm the diagnosis but is not usually necessary. Once the pain subsides, stretching and range-of-motion exercises facilitate rehabilitation and allow the patient to gradually resume normal activity.

Popliteal (Baker's) cysts are smooth-walled and most often result from accumulation of joint fluid in the gastrocnemiosemimembranosus bursa. This bursa frequently communicates with the knee joint as an extension of the posteromedial capsule be-

tween the medial head of the gastrocnemius muscle and the semimembranosus muscle (Figure). The natural history of popliteal cysts depends on their cause. Autopsy studies document popliteal cysts (usually small and asymptomatic) in up to 50% of the general population. If caused by trauma or an acute knee injury with effusion, symptomatic cysts may resolve without intervention after the knee effusion resolves or is removed by arthrocentesis. An untreated chronic effusion of any cause can lead to gradual development of a symptomatic popliteal cyst. The cyst may then enlarge and extend between the gastrocnemius and soleus muscles of the calf.

Occasionally, a cyst may dissect distally or rupture into the calf muscles; patients with this condition may present with the pseudothrombophlebitis syndrome. A small-to-moderate amount of hemorrhage may accompany cyst rupture; this blood may track down fascial planes until it settles superficially below a malleolus, resulting in the visible ecchymotic "crescent sign." Acute knee effusions may lead to rapid distention of a preexisting bursa with associated popliteal fullness and pain or difficulty on flexing the knee.

One danger (though uncommon) of treating a presumed DVT with anticoagulants in the absence of documented disease is that inappropriate anticoagulation of a dissecting or enlarging popliteal cyst may result in hemorrhage, rupture, and the compartmental syndrome.

2 What are the next diagnostic studies to perform in this patient?

- ☐ Repeat venography
- ☐ Ultrasonography of the popliteal fossa
- ☐ Knee arthrography
- ☐ Knee or cyst aspiration

There is little need to repeat the venogram, as the clinical presentation is consistent with a popliteal cyst and there is little reason to suspect a new DVT has developed since the previous study. Venography may demonstrate splaying of veins around a dissecting cyst, but cysts are better demonstrated by other, noninvasive studies.

Duplex ultrasonography can document a DVT above the knee with a sensitivity and specificity of greater than 90%, image the popliteal fossa, and demonstrate the presence of a popliteal cyst. The

TABLE 2
CAUSES OF POSTERIOR FOSSA "MASS"

Popliteal cyst
Distinct from knee joint
Anatomic connection with knee joint
Deep venous thrombosis
Popliteal artery aneurysm
Tumor
Necrotizing fasciitis
Muscle rupture
Hematoma
Excess fat

sensitivity of ultrasonography is approximately 70% for cysts 1 to 2 cm in size. Because several investigators have documented the coexistence of DVT and popliteal cysts in up to one third of patients, the ultrasonographic study should focus on identifying patent veins in addition to the presence or absence of a popliteal cyst.

Both arthrography and MRI are more sensitive for identifying popliteal cysts than ultrasonography is and may document small or ruptured cysts that ultrasonography misses. Arthrography of the knee, especially with knee movement after injection, will illustrate the inner aspect of the cyst, demonstrate any rupture, and document any intra-articular structural damage, but it is rarely necessary. Computed tomography or MRI may *occasionally* be needed to assess fully other potential causes of popliteal swelling or masses and should be considered if internal derangement or a severe meniscal injury is the suspected cause of the knee effusion (Table 2).

This patient underwent duplex ultrasonography, which demonstrated patent veins in the calf and upper leg and the presence of a partially dissected popliteal cyst.

Once a popliteal cyst is demonstrated, the question remains as to its etiology. Because the fluid distending the cyst usually comes from the knee joint, the differential diagnosis of an isolated acute popliteal cyst is the same as for an acute monarticular (knee) synovitis. Likewise, chronic popliteal cysts may result from the same processes that cause chronic knee effusions. The evaluation of acute monarticular arthritis requires appropriate analysis of the synovial fluid, focusing on the white cell count, presence or absence of crystals, and appropriate tests for infection.

TABLE 3
DIFFERENTIAL DIAGNOSIS
OF PERSISTENT KNEE EFFUSIONS

<i>Inflammatory causes</i>
Rheumatoid arthritis
Reactive arthritis
Crystal disease
Psoriatic arthritis
Ankylosing spondylitis
Enteropathic arthritis
Surgery or arthrography
Infectious arthritis
Bacterial
Fungal
Spirochetal (Lyme disease)
<i>Noninflammatory causes</i>
Meniscal tears
Osteoarthritis
Avascular necrosis
Hemarthrosis
Pigmented villonodular synovitis

3 Aspiration of this patient's cyst revealed cloudy synovial fluid with 18 500 white blood cells per mm³ (85% neutrophils), but no crystals. Routine synovial fluid cultures were negative. Possible causes of the popliteal cyst include which of the following?

- ☐ Rheumatoid arthritis
- ☐ Osteoarthritis
- ☐ Osteonecrosis
- ☐ Meniscal tear
- ☐ Infectious arthritis

The axiom "common problems occur commonly" holds true with popliteal cysts. Rheumatoid arthritis, osteoarthritis, and meniscal tears account for approximately 95% of all popliteal cysts. A one-way or ball-valve communication with a knee effusion is one proposed mechanism of popliteal cyst formation and enlargement. Cysts often coexist with conditions characterized by recurrent or persistent knee effusions. Therefore, all of the possibilities listed above, and more, must be considered as potential causes of popliteal cysts. In the present case, a meniscal tear, osteonecrosis, and osteoarthritis can be excluded on the basis of the inflammatory synovial fluid (more than 7500 white blood cells per mm³ with > 80% neutrophils). Rheumatoid arthritis is distinctly uncommon as a monarticular disease. Table 3 lists various other reported causes of knee effusions and subsequent popliteal cyst formation.

TREATMENT

Because of the history of an unexplained inflammatory knee effusion, and the potential exposure to *Borrelia* infection (Lyme disease) in the patient's home area of New Jersey, *Borrelia burgdorferi* serum titers were obtained. These were strikingly positive on enzyme-linked immunoadsorbent assay (ELISA) screening and confirmed by Western blot analysis (multiple bands). This is strong evidence for exposure to the *Borrelia* organism. Given the otherwise unexplained clinical finding of monoarticular, inflammatory knee arthritis, which is compatible with Lyme disease, antibiotic therapy was initiated. The patient completed a 3-month course of therapy with doxycycline (she was allergic to penicillin), and her symptoms resolved. It is possible that the nondescript "flu" she experienced the previous summer was the initial infection. She did not, in retrospect, recall any skin lesions suggestive of erythema chronicum migrans.

The importance of searching for the underlying cause of a popliteal cyst cannot be overemphasized. Infectious arthritis can present as a popliteal cyst or, as in this case, a ruptured popliteal cyst with erythema, pain, and swelling of the lower extremity. Most often, gonococcal, staphylococcal, and streptococcal species are the etiologic culprits in acutely infected native joints. There have been case reports of more indolent processes such as Lyme arthritis and fungal arthritis resulting in the formation of popliteal cysts. Determining the cause of the popliteal cyst is therefore of paramount importance in planning therapy. Intra-articular corticosteroid therapy should be avoided until the cause is determined, or at least until infection is excluded if the fluid is inflammatory.

Treatment should be tailored for each case and may include drainage and systemic antibiotics for cysts due to an infectious cause. For inflammatory but noninfected cysts, limitation of activity is indicated, in addition to either nonsteroidal anti-inflammatory medications, intra-articular steroid injections, or both. Mechanical intra-articular causes such as cartilage loose bodies or meniscal flaps may require arthroscopic correction. Surgically excising a popliteal cyst without investigating the underlying condition is often inadequate and may well

result in cyst recurrence. On the other hand, treating an underlying condition may permit resorption of the cyst and prevent further cyst enlargement or dissection.

SUMMARY

This case illustrates the importance of expanding the differential diagnosis beyond ruling out a DVT in a patient presenting with calf swelling. A good history and examination and a compulsive search for an etiology are necessary in the pursuit of the correct diagnosis. In this patient, only after identifying the popliteal cyst and recognizing that it represented an inflammatory synovitis could the cause be determined and the proper treatment instituted.

ROCHELLE ROSIAN, MD, AND
BRIAN F. MANDELL, MD, PhD
Department of Rheumatic and
Immunologic Diseases
The Cleveland Clinic Foundation

SUGGESTED READING

- Blumberg S, Kranrowitz FG. The pseudothrombophlebitis syndrome: a reappraisal. *Semin Arth Rheum* 1978; 10:278-280.
- Chadhuri R, Salari R. Baker's cyst simulating deep vein thrombosis. *Clin Rad* 1990; 41:400-404.
- Gorden GV, Edell S, Brogadir SP, et al. Baker's cysts and true thrombophlebitis: report of two cases and review of the literature. *Arch Intern Med* 1979; 139:40-42.
- Hench PK, Reid RT, Reames PM. Dissecting popliteal cysts simulating thrombophlebitis. *Ann Intern Med* 1966; 64:1259-1264.
- Katz RS, Zizic TM, Arnold WP, et al. The pseudothrombophlebitis syndrome. *Medicine* 1977; 56:151-164.
- Prescott SM, Pearl JE, Tikoff G. "Pseudo-pseudothrombophlebitis": ruptured popliteal cyst with deep venous thrombosis. *N Engl J Med* 1978; 299:1192-1193.
- Schmidt MC, Workman JB, Barth WF. Dissection or rupture of a popliteal cyst: a syndrome mimicking thrombophlebitis in rheumatic diseases. *Arch Intern Med* 1974; 134:694-698.
- Simpson FG, Robinson PJ, Bark M, et al. Prospective study of the thrombophlebitis and "pseudothrombophlebitis." *Lancet* 1980; 1:331-333.
- Soriano ER, Catoggio LJ. Baker's cyst, pseudothrombophlebitis, pseudo-pseudothrombophlebitis: where do we stand? *Clin Exp Rheum* 1990; 8:107-112.
- Vela P, Pascual E, Ronan J, et al. Cutaneous manifestation of ruptured popliteal cyst. *Clin Rheum* 1991; 10:340-341.
- Wigley RD. Popliteal cysts: variations on a theme of Baker. *Semin Arth Rheum* 1982; 12:1-10.