

**ALAIN A. EID, MD**

Dr. Eid is a fellow in pulmonary and critical care medicine at the University of Oklahoma Medical Center.

**MOTAZ AGABANI, MD**

Dr. Agabani is an endocrinology fellow at the University of California, Los Angeles.

**KEVIN GRADY, MD**

Dr. Grady is assistant director of the medical-surgical intensive care unit at St. John Hospital in Detroit.

# Negative-pressure pulmonary edema: a cautionary tale

A 45-year-old black woman with a history of asthma was admitted to the hospital because of rib fractures sustained in a motor vehicle accident that day. While in the hospital, she contracted pneumonia and experienced worsening of her asthma.

Because the bronchospasm was severe, the patient had to be intubated and admitted to the intensive care unit. She received standard treatment, which included antibiotics,  $\beta_2$ -agonists, theophylline, and steroids. Her condition improved, and by the ninth day she was ready to be weaned from the ventilator. **FIGURE 1** shows a roentgenogram of the chest taken that morning.

Abruptly, while the respirator was still in place, the patient became extremely short of breath, and her respiratory rate increased to approximately 50 per minute. She was confused and agitated. Up to this time she had been alert and oriented and had been able to respond to questions with gestures, but now she could not indicate what was wrong.

On physical examination, her blood pressure was 160/79 mm Hg, heart rate 130 per minute, and temperature 100.4°F. She was using accessory respiratory muscles and had severe bilateral wheezing, diminished breath sounds, and bilateral rales. There were no asymmetrical findings or other signs suggestive of pneumothorax. The skin was cyanotic. There were no new heart murmurs.

The alarm on the ventilator that indicated high inspiratory pressure was sounding constantly; the ventilator was in assist-control mode, and the fraction of inspired oxygen ( $FI_{O_2}$ ) was set at 40%. The oxygen saturation was 86%. The patient's respiratory rate decreased to 16 per minute after sedation. Before this acute event the patient had been comfortable and required sedation only rarely with intravenous lorazepam and morphine.

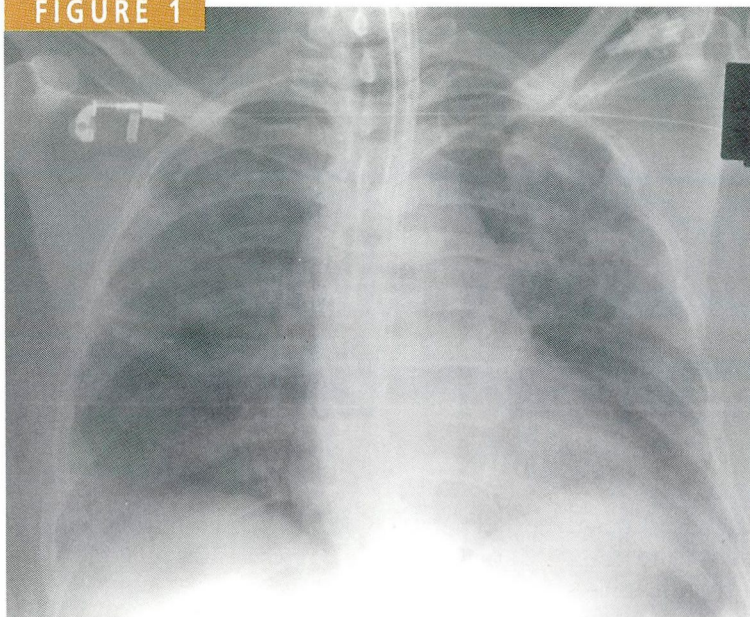
We disconnected the ventilator and inflated the patient's lungs manually, slowly. The respiratory therapist noticed considerable resistance to the entry of air, and could not pass a suction tube through the endotracheal tube easily. In addition, when he pulled the suction catheter out, thick mucus plugs were sticking to the tip.

A chest roentgenogram performed at 2 pm showed a new pattern of bilateral alveolar infiltration and an increase in pre-existing interstitial findings, compatible with pulmonary edema (**FIGURE 2**). The patient had no known heart disease, and the electrocardiogram remained unchanged during the episode.

We performed a bronchoscopy, and found that the endotracheal tube was severely obstructed by dry mucus plugs. We changed the tube immediately, and the patient experienced dramatic relief, followed by diuresis of 300 to 500 cc/hour. A repeat chest roentgenogram taken at 4 pm (**FIGURE 3**) showed that the alveolar infiltrate had decreased. We

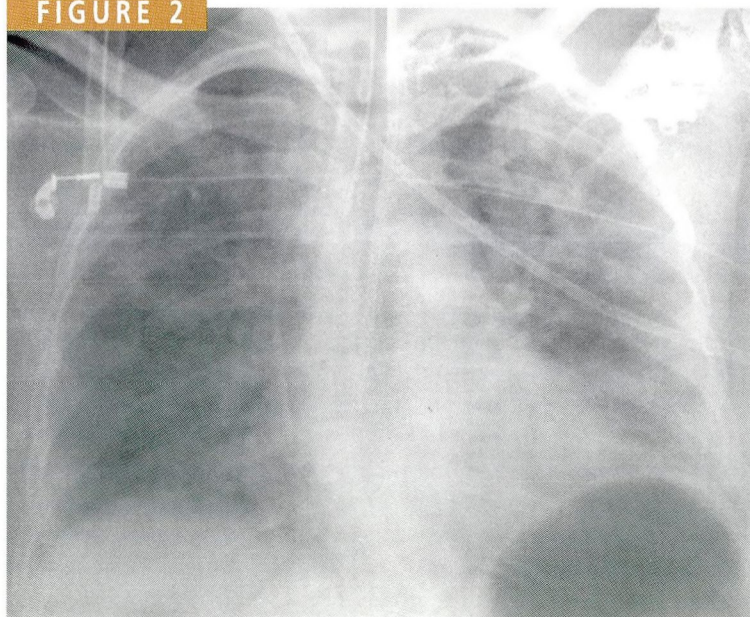


FIGURE 1



8 am. Routine portable chest roentgenogram, anterior-posterior (AP) view. Note the underlying atelectasis. A subclavian central line and an endotracheal tube are visible. No evidence of pulmonary edema is present.

FIGURE 2



2 pm. Note the bilateral pulmonary edema. The patient was extremely short of breath.

removed the tube 3 days later, and the patient did well.

## DISCUSSION

Acute pulmonary edema due to upper airway obstruction is infrequently reported in adults,<sup>1,2</sup> but may be underdiagnosed and therefore underreported.<sup>2</sup> We believe that upper airway obstruction caused by obstructed endotracheal tubes may at times be an unrecognized cause of pulmonary edema in intensive care units. However, to our knowledge, only one other case has been reported; the patient had bitten down on the endotracheal tube, causing it to collapse.<sup>3</sup>

### Causes of airway obstruction

Laryngospasm during intubation or after anesthesia is the most common cause of upper airway obstruction leading to pulmonary edema in adults, accounting for 42% to 50% of cases.<sup>2,4-6</sup> Other causes include strangulation,<sup>1</sup> epiglottitis,<sup>2</sup> croup,<sup>7</sup> thyroid goiter,<sup>5</sup> upper airway tumor,<sup>1</sup> acromegaly,<sup>8</sup> mediastinal tumor,<sup>9</sup> foreign-body aspiration,<sup>2,4</sup> insertion of a peroral prosthesis,<sup>9</sup> child abuse (attempted strangulation),<sup>10</sup> oral or pharyngeal surgery, temporomandibular joint arthroscopy,<sup>11</sup> obstructive sleep apnea,<sup>12</sup> obesity,<sup>9</sup> hypothyroidism,<sup>12</sup> hematoma compressing the airway, difficulty in intubation resulting in tracheal tear, and malpositioning of an endotracheal tube against the tracheal wall.<sup>13</sup>

### How airway obstruction can cause pulmonary edema

Several factors may contribute to this type of pulmonary edema.

*Negative intrathoracic and transpulmonary pressure* generated by trying to inhale against an obstructed upper airway is the main mechanism proposed.<sup>1,4,11</sup> Called "the Müller maneuver" when performed voluntarily against a closed glottis, this effort increases the pulmonary blood volume and decreases the pulmonary capillary perivascular pressure, both of which favor the formation of pulmonary edema.<sup>2,5,6,9,13,14</sup> The transcapillary

gradient can reach 75 cm H<sub>2</sub>O.

An **acquired permeability defect** in the alveolar capillary membranes may also contribute to pulmonary edema. Some investigators describe an intrinsic capillary membrane injury secondary to vigorous inspiration.<sup>9</sup>

**Hypoxia** can injure the pulmonary capillaries,<sup>6,15</sup> allowing proteins to transudate into the pulmonary interstitial space.<sup>16</sup> This process probably accounts for the high protein level in the interstitial fluid.

**Inflammation**, reflected by inflammatory cells (particularly neutrophils) within the alveoli and their septa, may contribute to a permeability defect.<sup>2,8,9,13,14,16</sup>

**Reflex vasoconstriction**, induced by hypoxia, may increase pulmonary arterial and capillary pressures.<sup>2,13</sup> Simultaneously, right ventricular preload increases, leading to increases in right ventricular stroke volume<sup>4,6,17</sup> and left atrial pressure and, therefore, to pulmonary edema.

Left ventricular pumping function is decreased by the high negative transmural pressure around the pumping chamber,<sup>13</sup> by the increase in afterload caused by reflex catecholamine release,<sup>4,11</sup> and by the global myocardial ischemia that results from prolonged hypoxia.<sup>2,6</sup> The left ventricular end-diastolic pressure increases because of paradoxical septal bulging due to an increase in right ventricular volume.<sup>2</sup> The reflex sympathetic activation also leads to peripheral vasoconstriction and shunting of more blood to the central circulation.<sup>4,11</sup>

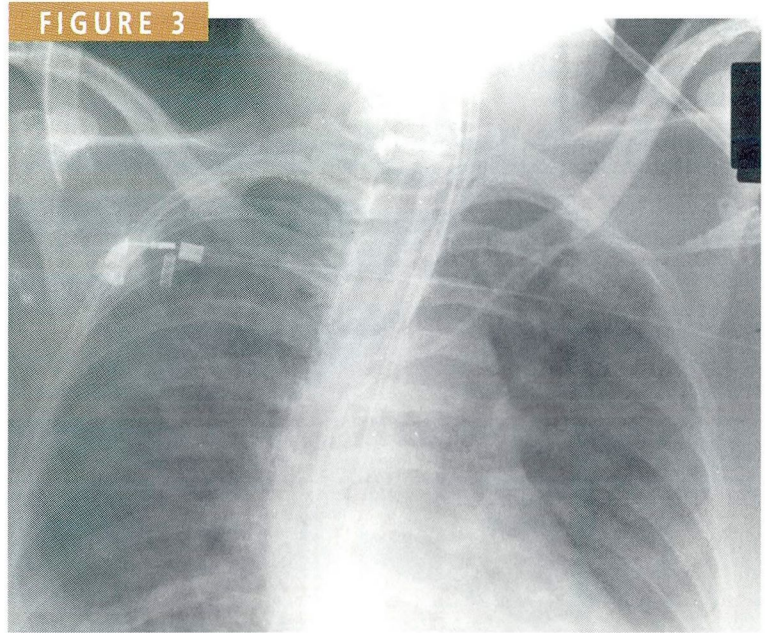
### Preventing this problem

Risk factors for endotracheal tube obstruction are prolonged or frequent mucus production (eg, in acute or chronic bronchitis, pneumonia, asthma), prolonged endotracheal intubation, bronchopulmonary bleeding with clot formation (eg, in pulmonary hemorrhage, pulmonary contusions), unusually tenacious secretions (commonly found in dehydrated patients), and small endotracheal tube size.

The problem could be averted by periodically changing the endotracheal tube, or at least checking its patency, in patients with risk factors for obstruction.

### Clinical picture

The pulmonary edema resulting from acute airway obstruction usually develops immediately, producing respiratory distress, tachypnea, and pink frothy sputum. Auscultation reveals rales and rhonchi, and the chest roentgenogram shows diffuse interstitial and alveolar infiltra-



4 pm. Note the rapid resolution of the edema. The patient had improved.

tion, mostly distributed centrally.

Airway obstruction should be suspected if unexplained pulmonary edema develops in an intubated patient. Difficulty in passing a suction catheter provides a clue to the diagnosis. Increases in the peak inspiratory pressure and in the peak-to-plateau pressure gradient offer another clue.


### Treatment

The initial treatment is to relieve the obstruction. Fluid restriction, diuretics, and possibly steroids are supplemental interventions.<sup>6</sup> Note that such patients may be dehydrated, and cardiovascular instability can follow relief of the obstruction.<sup>17</sup> ■

### REFERENCES

1. DeDio RM, Hendrix RA. Postobstructive pulmonary edema. *Otolaryngol Head Neck Surg* 1989; 101:698-700.
2. Lang SA, Duncan PG, Shephard DA, Ha HC. Pulmonary edema associated with airway obstruction. *Can J Anaesth* 1990; 37:210-218.
3. Dicipinigitis PV, Mehta DC. Postobstructive pulmonary edema induced by endotracheal tube occlusion. *Intensive Care Med* 1995; 21:1048-1050.
4. Zulueta JJ, Gerblach AA. Upper airway obstruction due to inhalation of a tracheal T-tube resulting in pulmonary edema. *Chest* 1992; 102:644-645.
5. Meyer KD, Chaudhry MR. Flash pulmonary edema secondary to upper airway obstruction. *Am Heart J* 1991; 122:576-577.
6. Herrick IA, Mahendran B, Penny FJ. Postobstructive pulmonary edema following anesthesia. *J Clin Anesth* 1990; 2:116-120.
7. Boykett M. Pulmonary edema after acute asphyxia in a child. *BMJ* 1989; 298:928.
8. Timby J, Reed C, Zeilander S, Glauser F. "Mechanical" causes of pulmonary edema. *Chest* 1990; 98:973-979.

# CLEVELAND CLINIC JOURNAL OF MEDICINE



## Let us hear from you

Let us hear your opinions about the *Cleveland Clinic Journal of Medicine*. Do you like current articles and sections? What topics would you like to see covered and how can we make the *Journal* more useful to you?

E-mail: [ccjm@cesmtp.ccf.org](mailto:ccjm@cesmtp.ccf.org)

WWW: <http://www.ccf.org/ed/ccjhome.htm>

Cleveland Clinic Journal of Medicine  
The Cleveland Clinic Foundation, EE37  
9500 Euclid Avenue  
Cleveland, Ohio 44195

Phone: 216.444.2661 Fax: 216.444.9385

9. Kollef MH, Pluss J. Noncardiogenic pulmonary edema following upper airway obstruction: 7 cases and a review of the literature. *Medicine* 1991; 70:91-98.
10. Marcovitch H. Inexplicable pulmonary edema [letter]. *Br Med J* 1989; 298:1383.
11. Hendler BH, Levin LM. Postobstructive pulmonary edema as a sequela of temporomandibular joint arthroscopy: a case report. *J Oral Maxillofac Surg* 1993; 51:315-317.
12. Lopez A, Lorente JA, Jerez V, Julia JA. Sleep apnea, hypothyroidism and pulmonary edema [letter]. *Chest* 1990; 97:763-764.
13. Cascade PN, Alexander GD, Mackie DS. Negative-pressure pulmonary edema after endotracheal intubation. *Radiology* 1993; 186:671-675.
14. Dohi S, Okubo N, Kondo Y. Pulmonary edema after airway obstruction due to bilateral vocal cord paralysis. *Can J Anaesth* 1991; 38(4 Part 1):492-495.
15. John PJ, Mahashur AA. Pulmonary edema associated with airway obstruction [letter]. *Can J Anaesth* 1991; 38:139-140.
16. Izbrand DJ, Aguilar EA 3rd, Fuentes F. Airway obstruction and pulmonary edema [letter]. *Ear Nose Throat J* 1990; 69:595-596.
17. Younker D, Meadors C, Coveler L. Postobstructive pulmonary edema. *Chest* 1989; 95:687-689.

ADDRESS REPRINT REQUESTS to Alain A. Eid, MD, Oklahoma University Health Sciences Center, 920 Stanton L. Young Blvd, Room 35P-400, Oklahoma City, OK 73104.