

GARY S. HOFFMAN, MD

Dr. Hoffman is chairman of the Department of Rheumatic and Immunologic Diseases at the Cleveland Clinic.

The perils of nontreatment of hyperuricemia

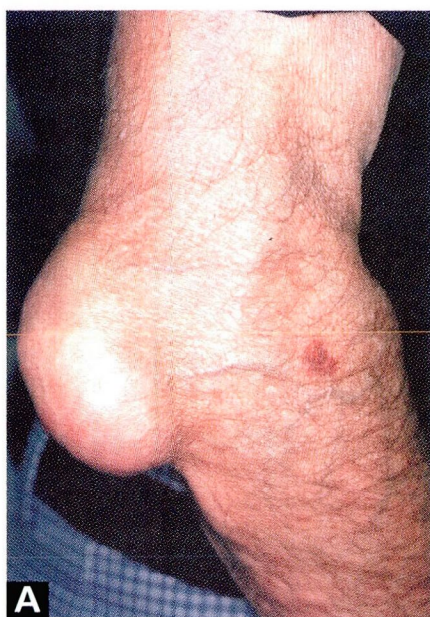PRESENTATION

A 68-year-old man had gout for many years. Unfortunately, although his attacks of gout were successfully treated with nonsteroidal anti-inflammatory drugs, his hyperuricemia was not corrected (10 to 12 mg/dL). After 15 years of recurrent attacks, the patient developed multifocal tophaceous deposits, including one on the elbow (A) and on the second distal interphalangeal joint (B, black arrow). Although the proximal interphalangeal joints (B, white arrows) have the appearance of Bouchard's nodes, commonly seen in patients with osteoarthritis, they were the site of sodium urate deposits.

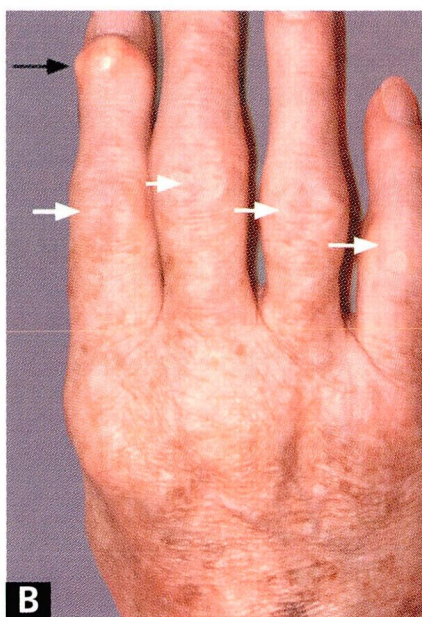
TREATMENT

Patients who experience more than one attack of gout and have sustained hyperuricemia should usually be treated for the remainder of their lives with drugs (eg, allopurinol, probenecid, sulfinpyrazone) to achieve normal uric acid levels.

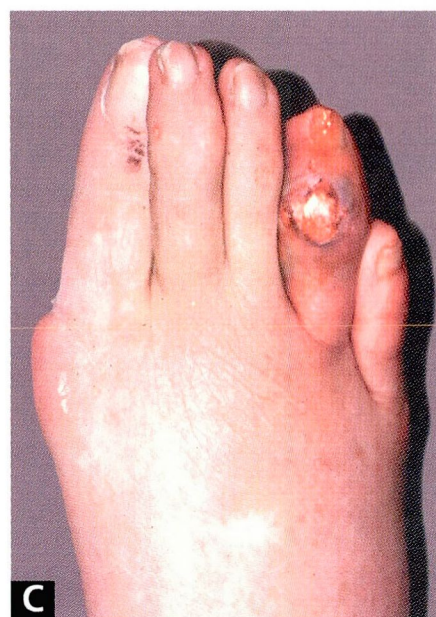
After uric acid levels return to normal, the tophi usually resolve over time. The perils of nontreatment are illustrated in another patient, whose gouty tophus eroded through the skin, resulting in secondary infection with *staphylococcus aureus* (C).



A Tophus on the elbow.



B Tophus in the second distal interphalangeal joint (black arrow), with enlargement of the proximal interphalangeal joints (white arrows).



C *Staphylococcus aureus* infection resulting from erosion of a tophus through the skin.