**BRIAN G. DONLEY, MD**

Orthopaedic surgeon,  
Department of Orthopaedics,  
Cleveland Clinic, specializing in  
foot and ankle disorders.

**CHRISTOPHER L. TISDEL, MD**

Orthopaedic surgeon,  
Department of Orthopaedics,  
Cleveland Clinic.

**JAMES J. SFERRA, MD**

Orthopaedic surgeon,  
Department of Orthopaedics,  
Cleveland Clinic.

**JAMES O. HALL, DPM**

Staff podiatrist,  
Department of Orthopaedics,  
Cleveland Clinic.

# Diagnosing and treating hallux valgus: A conservative approach for a common problem

**A**S LONG AS WEARING “SENSIBLE SHOES” is viewed by many as a fashion failure, and as long as vanity (in both men and women) influences shoe-buying, physicians will see patients with sore feet.

Often the source of the pain is a bunion caused by hallux valgus, a deformity most commonly caused by shoes, although other causes exist, such as heredity.

Although more than 100 surgical procedures have been developed to treat hallux valgus, conservative treatment with more sensible shoes (wider and flatter) is still the first treatment option.

This article reviews the cause and treatment of this common problem, and gives some suggestions on how to persuade patients to break their addiction to fashion.

## SHOES ARE THE MOST COMMON CULPRIT

The term “bunion” (from the Latin word *bunio*, “turnip”) refers to any enlargement of the first metatarsophalangeal joint caused by any of a range of disorders such as osteoarthritis, an enlarged bursa, or a ganglion cyst.

*Hallux valgus* (also Latin: *hallux*—great toe, *valgus*—bent outward) is more specific. Introduced by Hueter in 1870, the term refers to a subluxation of the first metatarsophalangeal joint with lateral deviation of the proximal phalanx and medial deviation of the first metatarsal.<sup>1</sup>

## ABSTRACT

For most patients with hallux valgus, the problem is caused by wearing shoes that are too tight, and conservative measures can help. We review how primary care physicians can evaluate and treat this problem, and when to refer to an orthopaedic surgeon.

## KEY POINTS

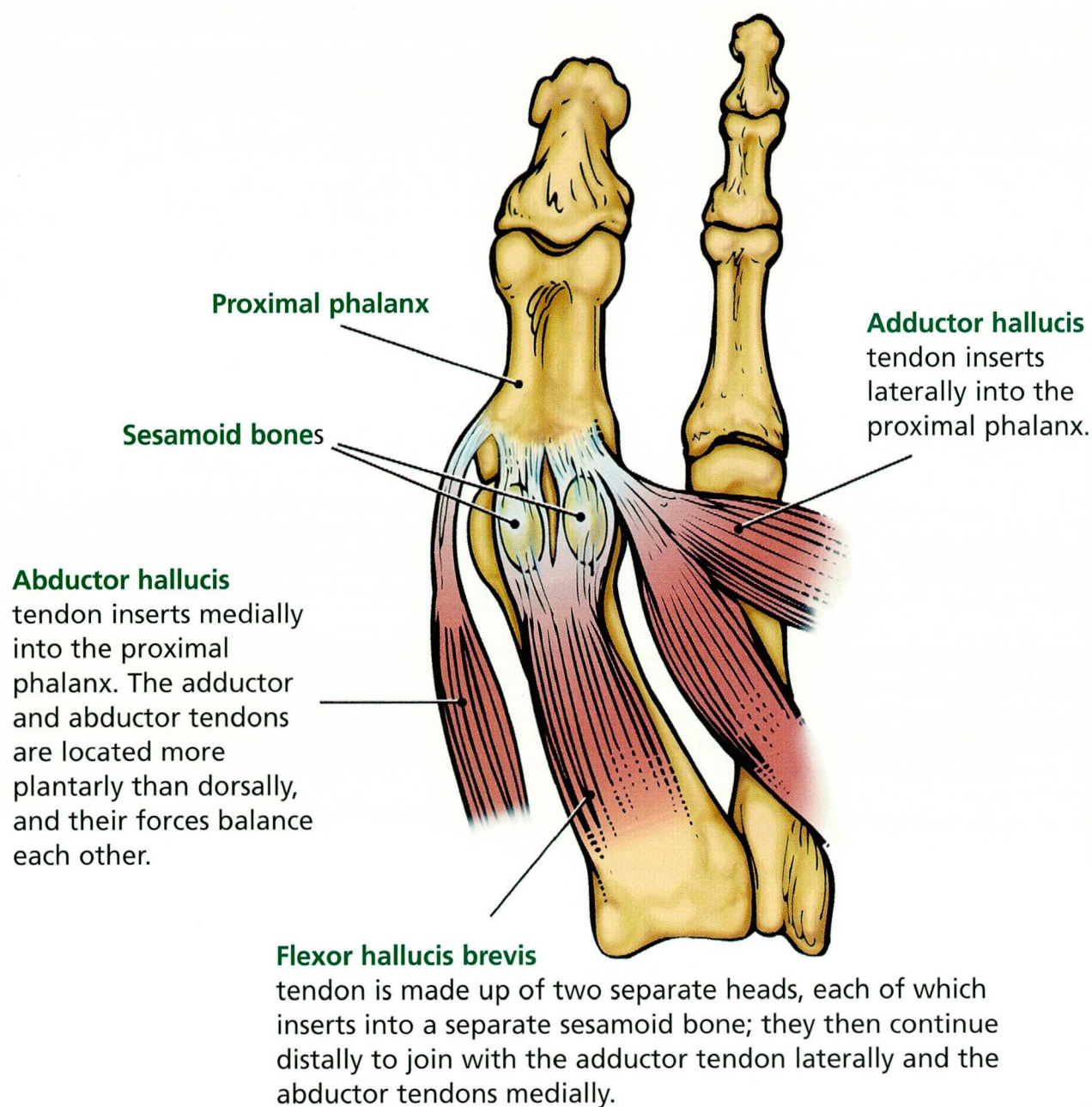
Examine the feet with the patient sitting, and then standing; note the magnitude of the lateral deformity, and also the rotational deformity of the great toe.

Radiographs are used to help in surgical decision-making and should always be obtained with the patient in a standing position.

Many patients benefit from a conservative approach based on better-fitting shoes. When these measures fail, referral to a foot-and-ankle surgeon can be beneficial.

FIGURE 1

## PLANTAR TENDONS OF THE METATARSOPHALANGEAL JOINT







Although many causes of hallux valgus exist, shoes are the most common cause. Lam Sim-Fook and Hodgson<sup>2</sup> reported in 1958 that 33% of Chinese people who wore shoes had hallux valgus, compared with only 2% of those who did not wear shoes. Further evidence implicating shoes is the increasing prevalence of hallux valgus in Japan after World War II, when the traditional clog shoe was replaced by the narrow-toed Western-style shoe.<sup>3</sup>

The deforming forces of shoes that cause hallux valgus are similar to the deforming forces created by the ancient process of foot-binding in China, in which the feet of young girls were tightly wrapped to stunt the growth of the feet in length and width and thus make them more attractive to men. The same process occurs with the fashionable shoes of the Western world, although to a lesser degree and at a slower rate. High heels put the feet in a more vertical position; narrow-toed shoes decrease the width of the foot. Although these features make the foot appear smaller and narrower (and therefore more “attractive”), they put tremendous deforming forces on the forefoot, forces that over time lead not only to hallux valgus but also to other forefoot deformities. Because such “fashionable” shoes are more common in women, the incidence of hallux valgus is two to 15 times greater in women than in men.<sup>4</sup>

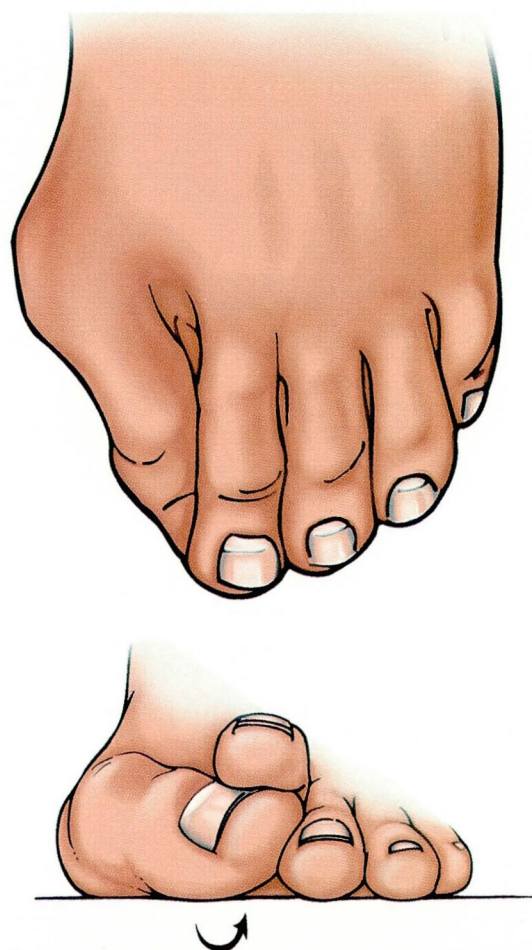
#### ■ OTHER CAUSES

Not all people who wear fashionable shoes develop hallux valgus, however, and other causes do exist.

**Heredity.** A family history of hallux valgus is a factor in up to 68% of patients.<sup>5</sup> Heredity plays a more prominent role in hallux valgus that develops in juveniles than in adults.

**Pes planus (flat feet)** can lead to hallux valgus by altering the gait. Persons with flat feet put more pressure along the medial border of the great toe than do persons with normal feet, both while standing and while stepping off from the toes, putting a constant, repetitive lateral force on the proximal phalanx with every step.

**Amputation of the second toe** removes the buttress effect that this toe provides,



**FIGURE 2** Top, hallux valgus, with a prominent medial eminence. Bottom, pronation rotatory deformity associated with hallux valgus.

allowing the great toe to progressively deviate into valgus.

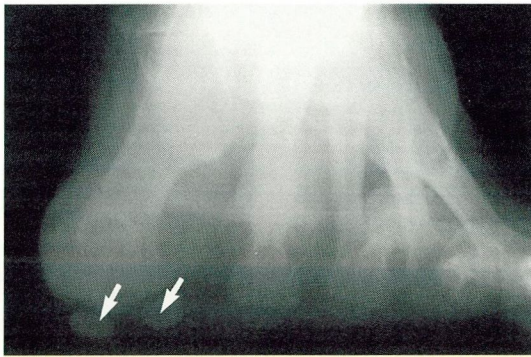
**Generalized hyperelasticity**, such as in the Ehlers-Danlos syndrome, is also associated with the development of hallux valgus.

#### ■ HALLUX VALGUS IS A PROGRESSIVE DEFORMITY

Since no muscles insert on the first metatarsal head (**FIGURE 1**), its position is influenced by the position of the proximal phalanx—as the proximal phalanx moves laterally, it progressively pushes the metatarsal head medially, increasing the space between the first and second metatarsals. As this process progresses,

**Fashionable shoes put tremendous deforming forces on the forefoot**





**FIGURE 3** Radiograph, sesamoid view. Note the lateral subluxation of the sesamoid bones (arrows).

the medial joint capsule attenuates while the lateral joint capsule progressively contracts. The sesamoid mechanism remains in place as the first metatarsal deviates medially, and the sesamoids eventually become lateral to the first metatarsal head.

As the deformity progresses, the muscles displace laterally and further enhance the deformity by exerting their pull lateral to the longitudinal axis of the first metatarsophalangeal joint. Further, as the medially located abductor hallucis tendon slides under the first metatarsal head, it creates a rotational deformity of the proximal phalanx, leading to progressive pronation of the great toe when viewed from the end of the foot (**FIGURE 2**). Thus, hallux valgus is not only a progressive lateral deformity in the axial plane, but also a rotational deformity in the coronal plane.

## EVALUATION

### History and chief complaint

**Pain over the medial eminence (bunion)** is the most common complaint. This pain is caused by shoes putting pressure over the prominent medial eminence, leading to bursal inflammation, irritation of the skin, and, rarely, even skin breakdown.

**Pain under the second metatarsal head**, sometimes leading to an intractable plantar keratosis (callus), is the second most common chief complaint. As the first metatarsophalangeal joint progressively deforms, the first

metatarsal can no longer perform its function of supporting 50% of the forefoot forces with weight bearing and thus transfers its responsibility to the adjacent second ray. The increased forces imposed upon the second ray lead to pain and callus formation under the second metatarsal head. Occasionally, patients may present with a stress fracture of the second metatarsal.

In taking the history, it is also important to learn the patient's level of activity, occupation, recreational demands on the foot, and footwear preferences. A thorough medical history should also be obtained.

### Physical examination

With the patient both sitting and standing, the physician should:

- Examine the feet thoroughly, looking at motion of the hindfoot and midfoot and evaluating for pes planus or a tight Achilles tendon.
- Note the magnitude of the lateral and rotational deformity of the great toe. This should be done with the patient standing, since the deformity will be worse in this position.
- Check the active and passive range of motion of the first metatarsophalangeal joint. Pain or crepitus with range of motion increases the suspicion of degenerative arthritis.
- Look for calluses on the plantar aspect of the foot, and palpate the foot to determine the location of pain.
- Examine the rest of the forefoot for other factors that could contribute to forefoot pain such as a hammer toe, mallet toe, neuromas, or soft corns.
- Perform a thorough neurologic and vascular examination.

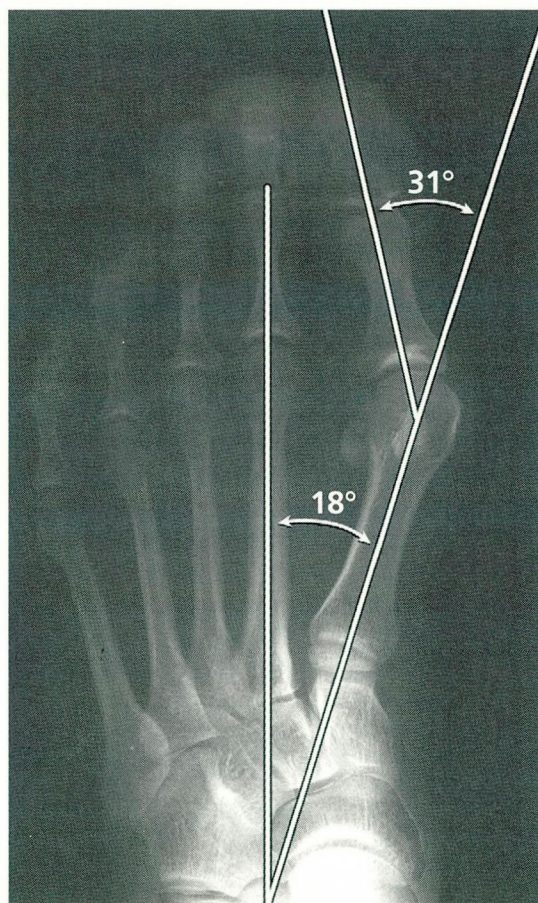
### Radiographs

The radiographic examination should consist of an anterior-posterior, a lateral, an oblique, and a sesamoid view (**FIGURE 3**), all with the foot bearing weight. The magnitude of the deformity is defined by two radiographic measurements:

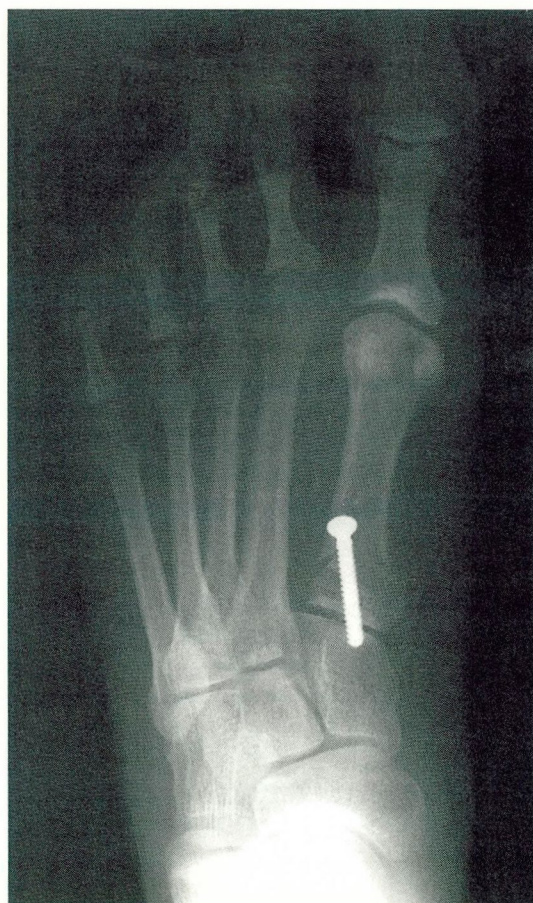**The hallux valgus angle**—the amount by which the proximal phalanx deviates laterally from forming a straight line with the first metatarsal. Normal is 15° or less (**FIGURE 4**).

**The deformity is worse in the standing position**





**FIGURE 4** The radiographic angles that define the severity of hallux valgus. The hallux valgus angle in this patient is  $31^\circ$  (normal is  $\leq 15^\circ$ ), and the intermetatarsal angle is  $18^\circ$  (normal is  $< 9^\circ$ ).



**FIGURE 5** Postoperative radiograph in the same patient as in *FIGURE 4*. Note correction of the hallux valgus and intermetatarsal angles with a proximal metatarsal osteotomy.

The **intermetatarsal angle**—the angle between the first and second metatarsals. Normal is less than  $9^\circ$ .

It is also critical to evaluate the first metatarsophalangeal joint during the physical examination and radiographically, searching for arthritic changes, since these changes limit the surgical choices for treatment.

## TREATMENT

### Try conservative measures first

All patients with hallux valgus deformities should initially be treated conservatively with footwear modifications.

**Wider shoes.** The most important first step is to educate the patient to wear shoes with toe boxes wide enough to accommodate the prominent medial eminence. Since the chief complaint of 70% of patients with hallux valgus is the pain of the shoe rubbing against the medial bunion, wider shoes relieve the discomfort for most patients. We suggest that patients wear sports shoes the same width as their feet and dress shoes no more than one fourth inch narrower than their feet.

**Flat heels.** Further, the patient should be cautioned to wear heels as little as possible. High heels place downward pressure on the forefoot, pushing the painful medial eminence

**The hallux valgus angle and the intermetatarsal angle are measures of the severity of the deformity**





**Pain relief is  
the primary  
indication for  
surgery**

into the constricting, narrow toe box.

**Patient education.** To help the patient understand the relationship between inappropriate shoes and painful hallux valgus, trace the outline of the patient's foot while he or she stands on a piece of paper. Then, on top of this tracing, draw the outline of the patient's shoe. This will visually display the wide forefoot that the patient is forcing into a narrow-toed shoe.

**Other conservative measures.** Stretching the areas of the shoe that cause increased pressure can provide great pain relief. Occasionally, custom-made shoes for patients with severe hallux valgus can be useful. Bunion pads, night splints, and toe spacers are also recommended as an adjunct initially along with these footwear modifications. Orthotic devices can help patients who have pain under the second metatarsal head. Patients with a tight Achilles tendon may need physical therapy to stretch this tendon.

### Surgery

If these conservative measures fail, surgery should be considered. The goal of surgery is to correct the different pathologic components of the hallux valgus deformity, yet maintain a biomechanically functional forefoot.

It is most important for the patient to have realistic expectations about surgery. Often, after surgery there is some residual stiffness of the joint, minor pain, or minor residual deformity at the joint. For these reasons, patients should not undergo surgery for cosmetic purposes; rather, relief of pain should be the primary reason. Also, if a patient's only desire is to get into more fashionable shoes, he or she must realize that one-third of patients still cannot wear the fashionable shoes they desire, even after bunion surgery.

### Choice of surgical procedure

Since more than 100 procedures have been described to correct hallux valgus, no one procedure can be used to treat all deformities. No matter which procedure is performed, all the elements of the deformity need to be corrected to have a successful outcome and prevent recurrence: the increased hallux valgus angle, the increased intermetatarsal angle, the pronation (rotation) of the great toe, the enlarged medial eminence, and the subluxation of the sesamoids. The choice of procedure is dictated by the severity of the deformity.

**Mild deformities** (hallux valgus angle < 30°, intermetatarsal angle < 15°) can generally be treated with a distal soft-tissue procedure or an osteotomy of the distal first metatarsal. The distal soft-tissue procedure releases the contracted lateral structures of the metatarsophalangeal joint, tightens the loose medial metatarsophalangeal capsule, and removes the prominent medial eminence. The "chevron" procedure is a popular distal metatarsal osteotomy that narrows the forefoot by laterally translating the first metatarsal head.

**More severe deformities** (hallux valgus angle < 40°, intermetatarsal angle > 15°) are treated with a distal soft-tissue procedure and an osteotomy of the proximal metatarsal or a fusion of the proximal metatarsocuneiform joint (FIGURE 5).

Osteoarthritis of the first metatarsophalangeal joint is often best treated by fusing the metatarsal to the proximal phalanx, or with a resection arthroplasty, depending on the patient's age and activity level.

**ACKNOWLEDGMENTS:** The authors wish to thank Joe Kanasz for his assistance with preparation of the figures and Judith Eassa for her assistance with preparation of the manuscript.

### REFERENCES

1. Hueter C. Klinik der Gelenkrankheiten mit Einschluss der Orthopädie. Leipzig: FCW Vogel, 1870.
2. Lam Sim-Fook, Hodgson AR. A comparison of foot forms among the non-shoe and shoe-wearing Chinese population. *J Bone Joint Surg (Am)* 1958; 40:1058.
3. Mann RA, Coughlin MJ. Adult hallux valgus. In: Mann RA, Coughlin MG, editors. *Surgery of the Foot and Ankle*, 6th edition. St. Louis: Mosby-Year Book, 1993:167-296.
4. Coughlin MJ, Thompson FM. The high price of high-fashion footwear. In: *Instructional Course Lectures*, volume 44. Rosemont, Ill: American Academy of Orthopaedic Surgeons, 1995:371-377.
5. Glynn MK, Dunlop JB, Fitzpatrick D. The Mitchell distal metatarsal osteotomy for hallux valgus. *J Bone Joint Surg* 1980; 62-B(2):188-191.

**ADDRESS:** Brian G. Donley, MD, The Cleveland Clinic Foundation, A41, 9500 Euclid Avenue, Cleveland, OH 44195.