

**AMIR JAFFER, MD**Department of General Internal Medicine,
Cleveland Clinic**LEONARD CALABRESE, DO**Department of Rheumatology and
Immunology, Cleveland Clinic

Severe back and abdominal pain in a 44-year-old woman

A 44-YEAR-OLD WOMAN seeks medical attention after enduring 3 months of escalating pain in the abdomen and back. The pain, which is sharp and intermittent, starts in the middle of her back and radiates into her abdomen and pelvis. It is not affected by position and has slowly become more constant and unbearable. She feels some nausea along with the pain. The patient denies having had any injury to her back. She has tried multiple over-the-counter pain medications, but they did not help much.

Past medical history. The patient had migraines for approximately 20 years, but these resolved approximately 5 years ago and required no further therapy. She used to take propranolol as prophylaxis and an aspirin-butalbital-caffeine combination (Fiorinal) to treat the migraine attacks, but she no longer takes any medications.

Physical examination. The patient is writhing in pain. Her blood pressure is 146/97 mm Hg. Her heart and lungs are normal on examination. No abdominal masses, hepatosplenomegaly, or lymphadenopathy are appreciated. She does not show any peritoneal signs or guarding of her abdomen. On neurological examination, she has normal motor strength and no sensory deficits. Her deep tendon reflexes are 2+ bilaterally in the upper and lower extremities. The straight leg-raise test is negative bilaterally.

Laboratory studies. The patient's blood chemistry levels and complete blood count are within normal limits. However, her erythrocyte sedimentation rate is 100 mm/hour (normal: 0–20).

Further workup. Because the pain seems to be out of proportion to the physical findings, a computed tomographic (CT) scan of

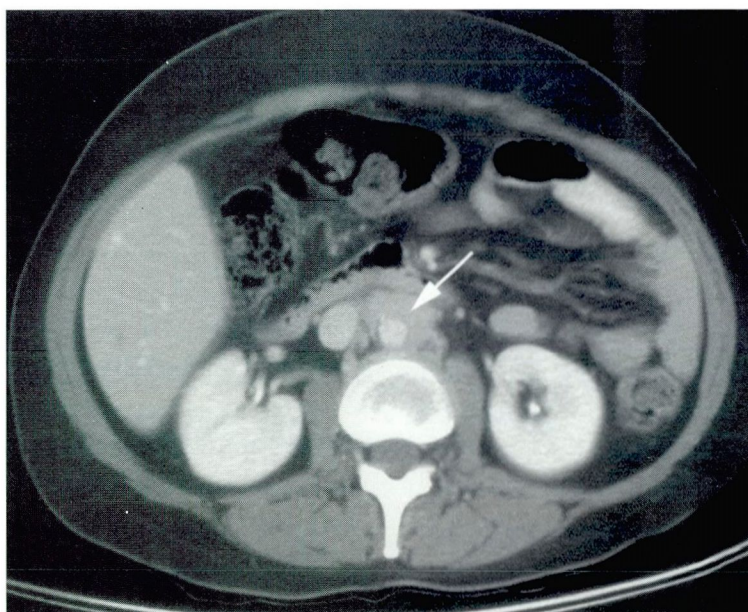


FIGURE 1. Computed tomographic scan. The arrow shows fibrous tissue surrounding the aorta, suggestive of retroperitoneal fibrosis.

the abdomen is done. This reveals periaortic deposition of fibrous material at the level of the celiac vessels (**FIGURE 1**).

The patient is referred to a surgeon for biopsy, and an abdominal laparotomy is performed to obtain a biopsy specimen of this fibrotic tissue. Pathologic analysis of this specimen confirms the diagnosis of retroperitoneal fibrosis.

Therapy is started with tamoxifen. However, the patient does not improve within 4 weeks, and so her treatment is switched to prednisone. This produces a dramatic response: within 2 weeks the pain in the back and abdomen resolves, and the erythrocyte sedimentation rate drops to 30 mm/hour. The

patient continues to take prednisone at the time of her last visit.

■ DIAGNOSING RETROPERITONEAL FIBROSIS

Signs and symptoms

- 1 What are the most common presenting signs and symptoms of retroperitoneal fibrosis?
 - Pain in the back, flank, and abdomen
 - Weight loss and weakness
 - Oliguria
 - Claudication and leg swelling
 - Renal colic

Retroperitoneal fibrosis, sometimes called Ormond disease, is a true connective tissue disease, as it involves inflammation and deposition of collagen around the aorta. It occurs in fewer than 1 in 10,000 persons, most often between the ages of 40 to 60 years, as in our patient.¹

Diagnosing retroperitoneal fibrosis is difficult, because the presenting symptoms are usually nonspecific, and physical findings are lacking. For this reason, patients often face a considerable delay between the onset of symptoms and diagnosis.

Although all of the signs and symptoms listed above may be observed, the most common is pain in the back, flank, and abdomen.¹ Many patients describe the pain as aching and dull. It has no specific pattern of radiation and is usually not exacerbated by movement or palpation. Weight loss, weakness, claudication, and lower extremity swelling are less common. Renal colic is rare.¹

Laboratory tests

- 2 What laboratory tests support the diagnosis of retroperitoneal fibrosis?
 - An elevated erythrocyte sedimentation rate
 - Elevated blood urea nitrogen and creatinine levels
 - Positive antinuclear antibodies (ANA)
 - Microscopic hematuria and proteinuria

- Positive antineutrophil cytoplasmic antibodies (ANCA)

No one blood test is diagnostic of this condition, but an elevated erythrocyte sedimentation rate suggests that an inflammatory process is going on.² More than half the patients have azotemia at presentation. Although a positive ANA and ANCA may be seen, they do not confirm the diagnosis.¹

Imaging studies

A classic radiologic finding, seen in approximately two thirds of patients, is bilateral ureteral obstruction leading to hydronephrosis,³ primarily at the level of the bifurcation of the iliac arteries, due to inflammatory fibrous tissue extending laterally and encircling the ureters. As the fibrotic mass grows, it draws the ureters medially. The pathogenesis of this medial deviation of the ureters is unclear.⁴

CT scanning and **magnetic resonance imaging (MRI)** are sensitive for documenting the infiltrating process in the retroperitoneum and are usually the first imaging studies performed, but they lack specificity in confirming this diagnosis in most cases.¹ Therefore, a CT scan, although desirable, is not essential for diagnosis.

Intravenous pyelography can demonstrate medial deviation of one or both ureters at the L3–L4 level.⁵

Retrograde pyelography can be revealing to an experienced urologist or radiologist when peristalsis is absent and the ureters are nondistensible.^{6,7} This test is often used in patients with impaired renal function in whom intravenous contrast is contraindicated.

Biopsy

Although all of the above studies are useful, only a biopsy definitively establishes the diagnosis—and rules out malignancy. A small retrospective study² underscored the importance of this point. Of 30 patients with idiopathic retroperitoneal fibrosis, 16 (53%) did not undergo biopsy initially but were treated empirically. Of these, 4 (25%) were subsequently found to have a malignant disease.

Most patients have bilateral ureteral obstruction and hydronephrosis

Pathologic study shows collagen bundles interspersed with inflammatory cells such as macrophages, lymphocytes, and plasma cells. The presence of inflammatory cells within this mass of tissue suggests an immune-mediated pathogenesis for this disease.

Because this disease is rare and has no animal model, the pathogenesis of retroperitoneal fibrosis remains unclear.^{1,5} Most cases are idiopathic.⁴ However, it is known to occur with use of certain medications and with some diseases, as discussed below.

Medications

3 What medications are known to be associated with retroperitoneal fibrosis?

- Methysergide
- Propranolol
- Ergotamines
- Hydralazine
- All of the above

All of the above medications have been reported to be associated with retroperitoneal fibrosis. However, the association is most strong with methysergide. Approximately 1% of patients taking this medication develop retroperitoneal fibrosis.⁸ In one series of patients with methysergide-associated retroperitoneal fibrosis,³ the average dosage had been high (6 to 8 mg/day), and patients had taken the drug long-term (9 to 59 months). Experts believe that the fibrotic process can resolve spontaneously if the etiologic agent is recognized and stopped early.

Our patient never took methyserside for her migraines, but had taken propranolol.

Other associated conditions

Retroperitoneal fibrosis has also been reported in association with:

- Other connective tissue diseases such as scleroderma, lupus, polyarteritis nodosa, and Wegener granulomatosis
- Certain malignant diseases, including sarcomas, lymphomas, lung cancer, and breast cancer, which can present with retroperitoneal fibrosis¹
- Certain fibrosing conditions such as Riedel struma (invasive fibrous thyroiditis)

and sclerosing cholangitis

- Retroperitoneal injury from radiation, hemorrhage, trauma, or infection.

■ TREATING RETROPERITONEAL FIBROSIS

4 What are the treatment options for patients with retroperitoneal fibrosis?

- Prednisone
- Tamoxifen
- Surgery
- All of the above

At present, standard therapy consists of corticosteroids. However, the medical management of retroperitoneal fibrosis is controversial because no randomized controlled studies have evaluated the efficacy of corticosteroids or immunosuppressive therapy.⁹

Prednisone. Owing to the inflammatory nature of this disease and the presence of vasculitis in some of the lesions, experts recommend a regimen of prednisone similar to that used in temporal arteritis. The initial dosage is 40 to 60 mg/day in split doses until systemic symptoms resolve, usually within 1 to 2 weeks. The dose is then consolidated to a single daily dose and then tapered over the next 2 to 3 months to 10 mg/day. Depending on symptoms and laboratory findings, the dose can be further tapered over the next few months. Treatment usually continues for approximately 1 year.¹

A number of patients experience a relapse after discontinuing prednisone and may require treatment for longer periods. In others, the disease may not respond to prednisone and may require immunosuppressive therapy with agents such as azathioprine and cyclophosphamide. A repeat CT scan or MRI is usually recommended after 6 to 8 weeks of prednisone therapy to assess the response.

Surgery. Some patients who have a larger burden of disease and involvement of the ureters need surgery to remove tissue from the retroperitoneum, in addition to immunosuppressive therapy.

In a retrospective analysis of 430 cases of retroperitoneal fibrosis,⁹ 70% of patients required surgery such as ureterolysis and lateral ureteral displacement. In patients present-

Patients take prednisone up to a year, and many need surgery



THE CLEVELAND CLINIC FOUNDATION

11th Annual

INTENSIVE REVIEW OF INTERNAL MEDICINE

Featuring:

Board simulation sessions

Interactive computer system
for lectures and simulation sessions

June 6-11, 1999

Renaissance Cleveland Hotel
Cleveland, Ohio

For further information please write or call:

The Cleveland Clinic Educational Foundation
Continuing Education Department
9500 Euclid Avenue, TT-31
Cleveland, OH 44195

216-444-5695

800-762-8173

216-445-9406 (FAX)

JAFFER AND CALABRESE



ing with moderate upper urinary dilatation, corticosteroid therapy alone was successful in 93%. When patients received corticosteroid therapy after undergoing surgery, the long-term recurrence rate was only 10%. In contrast, surgery without corticosteroid therapy resulted in ureteral restenosis 5 times more often.

Tamoxifen was effective in treating retroperitoneal fibrosis in a number of case reports,⁶ but no large controlled trials have been conducted. Therefore, we do not recommend using tamoxifen as first-line therapy.

■ SUMMARY

Retroperitoneal fibrosis is an uncommon collagen vascular disease. Back pain with no specific radiation pattern is a common finding. Evaluation usually begins with an abdominal CT scan or MRI. The finding of fibrous periaortic tissue in conjunction with an elevated erythrocyte sedimentation rate supports the diagnosis. A biopsy is necessary to confirm the diagnosis and exclude malignancy. Sometimes retroperitoneal fibrosis can progress to the point of causing bilateral ureteral obstruction leading to acute renal failure. Corticosteroids, in conjunction with surgery when needed, are the mainstay of therapy. ■

■ REFERENCES

1. **Gilkeson GS, Allen NB.** Retroperitoneal fibrosis: A true connective tissue disease. *Rheum Dis Clin North Am* 1996; 22(1):23-38.
2. **Cotsamire D, Ibrahim G, Robertson C, Gilkeson G.** Clinical parameters and therapeutic outcome in patients with idiopathic retroperitoneal fibrosis (abstract). *Arthritis Rheum* 1991; 34:R34.
3. **Koep L, Zviderma GD.** The clinical significance of retroperitoneal fibrosis. *Surgery* 1977, 81:250-257.
4. **Lepor H, Walsh PC.** Idiopathic retroperitoneal fibrosis. *J Urol* 1979; 122:1-126.
5. **Mitchinson MJ.** Retroperitoneal fibrosis revisited. *Arch Pathol Lab Med* 1986; 110:784-786.
6. **Clark CP, Vanderpool D, Preskitt JT, et al.** The response of retroperitoneal fibrosis to tamoxifen. *Surgery* 1991; 109:502-506.
7. **Kottra JJ, Dunnick NR.** Retroperitoneal fibrosis. *Radiol Clin North Am* 1996; 34(6):1259-1275.
8. **Elkind AH, Friedman AP, Bachman A, Siegelman SS, Sacks DW.** Silent retroperitoneal fibrosis associated with methysergide therapy. *JAMA* 1968; 206:1041-1044.
9. **Wagenknecht LV, Hardy JC.** Value of various treatments for retroperitoneal fibrosis. *Eur Urol* 1981; 7:193-200.

ADDRESS: Amir Jaffer, MD, Access Center, E13, The Cleveland Clinic Foundation, 9500 Euclid Avenue, Cleveland, OH 44195.