



CRAIG NIELSEN, MD

Department of General Internal
Medicine, Cleveland Clinic

PETER MAZZONE, MD

Department of Pulmonary and
Critical Care, Cleveland Clinic

A 47-year-old man with headache and ptosis

A 47-YEAR-OLD man presents to the emergency department because of a headache that began 8 hours ago, and difficulty opening his right eye beginning 4 hours ago. He describes the headache as a constant "frontal pressure" which started while he was driving to work. Associated symptoms include a sensation of warmth and diaphoresis. He reports no precipitating or relieving factors and has not had any serious headaches previously. He had not been concerned about the headache until he noticed that his right eyelid was "drooping." A review of systems reveals that he has been experiencing fatigue, polyuria, and polydipsia for the past 1 to 2 months.

Nothing in the patient's medical or surgical history is remarkable. He is married with two children and works as an auto mechanic. He does not smoke or drink alcohol. He takes no medications and has no known drug allergies.

Physical examination

The patient is not in distress. His temperature is 37.5°C, heart rate 68, respiratory rate 18, and blood pressure 103/70 mm Hg.

The patient's right eye is deviated downward and laterally, and he cannot move it upward, downward, or inward. Ptosis is present, and the pupil is dilated (6 mm) and non-reactive. Funduscopic examination reveals no papilledema. The remainder of the neurologic examination is normal.

The patient's neck is not stiff or tender. Examination of his heart, chest, and abdomen reveals nothing remarkable. His laboratory values on admission are shown in

OCULOMOTOR (THIRD CRANIAL NERVE) PALSY

1 What is the most appropriate next step in the management of this patient?

- ☐ A cerebral arteriogram
- ☐ Lumbar puncture
- ☐ Reassurance that the palsy will resolve without further intervention
- ☐ A computed tomographic (CT) scan or magnetic resonance imaging (MRI) of the brain
- ☐ Reassurance that the palsy will resolve with treatment of the elevated glucose

TABLE 1

The patient's laboratory values on admission

TEST	VALUE	UNITS	NORMAL RANGE*
White blood cell count	12.1	$\times 10^9/L$	4.0–11.0
Hemoglobin	15.9	g/dL	13.5–17.5
Platelets	258	$\times 10^9/L$	150–400
Albumin	4.7	g/dL	3.5–5.0
Calcium	9.5	mg/dL	8.5–10.5
Phosphorus	5.0	mg/dL	2.5–4.5
Bilirubin	1.2	mg/dL	0–1.5
Lactate dehydrogenase	148	U/L	100–200
Aspartate aminotransferase	16	U/L	7–40
Blood urea nitrogen	9	mg/dL	10–25
Creatinine	0.7	mg/dL	0.7–1.4
Serum glucose, fasting	309	mg/dL	65–110
Sodium	143	mmol/L	135–146
Potassium	4.2	mmol/L	3.5–5.0
Chloride	109	mmol/L	98–110
Bicarbonate	27	mmol/L	21–28

*Normal values listed are for men

TABLE 1.

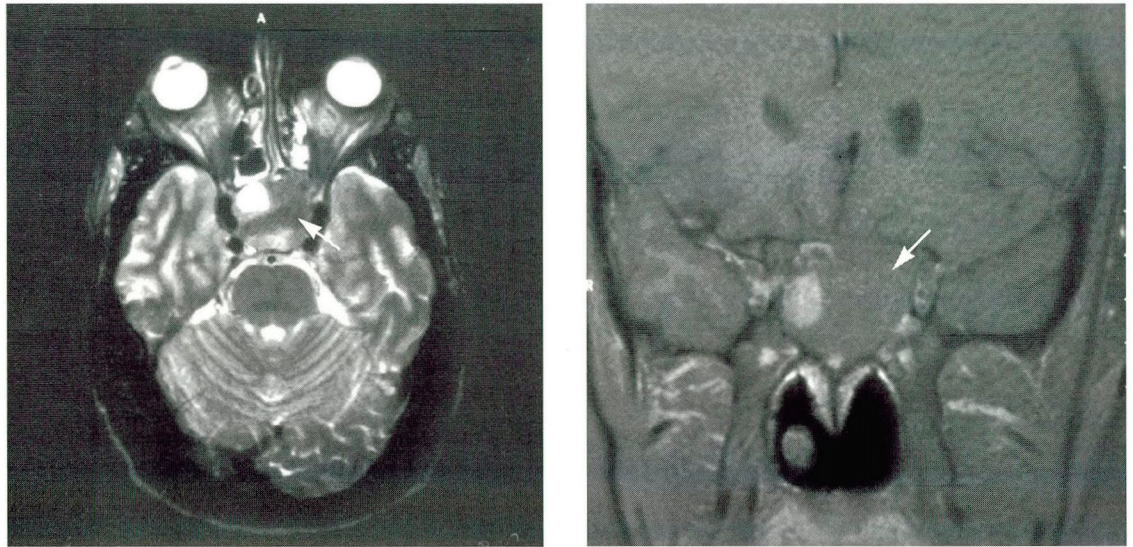


FIGURE 1. MRI examination of the brain. Left, axial section. Right, frontal section. Arrows point to a pituitary adenoma measuring approximately 4 cm.

The oculomotor (or third cranial) nerve has several functions. Its parasympathetic fibers innervate the iris sphincter. Its motor neurons supply the levator palpebrae superioris muscle and several extraocular muscles: the medial, inferior, and superior recti, and the inferior oblique.

The typical physical findings of complete oculomotor palsy are as described in the above examination:

- Inability to move the eye upward, downward, or inward
- Deviation of the eye downward and laterally ("down and out")
- Ptosis
- A dilated, nonreactive pupil.

There are many possible causes of oculomotor nerve palsy. After the oculomotor nerve leaves the midbrain it enters the subarachnoid space, where it is vulnerable to meningeal processes or compression or both, such as in meningitis, tumors, uncal herniation, hemorrhage, and aneurysms (usually in the posterior communicating artery of the Circle of Willis). It then enters the cavernous sinus, where it is susceptible to tumors, carotid aneurysms, infections, and cavernous sinus thrombosis.

A common presentation of oculomotor nerve palsy, especially in outpatients with diabetes, is microinfarction of the nerve. The

key physical finding that identifies this subset of patients is that pupillary sphincter function is completely spared. Imaging studies in such patients are generally unrewarding. Such patients need no specific therapy and can be followed with watchful waiting, as the palsy usually resolves spontaneously within months. Our patient's pupil was dilated, and therefore reassurance is not appropriate at this time.

Pupillary involvement requires further evaluation. A CT scan or MRI of the brain would be the first step to look for evidence of a compressive lesion. If the imaging study is negative, an arteriogram should then be performed to look for evidence of an aneurysm.¹ If there is concern about meningitis, a lumbar puncture could precede the arteriogram.

Case continued

A CT scan of the brain revealed a 4-cm mass within the pituitary fossa. The mass, which was felt to be consistent with a pituitary macroadenoma, was compressing the optic chiasm; it possibly extended into both the suprasellar cistern and right cavernous sinus, and showed evidence of hemorrhage in its interior. **FIGURE 1** shows representative cuts from a subsequent MRI examination.

In oculomotor nerve palsy, pupillary involvement calls for further evaluation

■ PITUITARY APOPLEXY

2 Which one of the following is *not* a sign or symptom of pituitary apoplexy?

- ☐ Fever
- ☐ Meningismus
- ☐ Nausea and vomiting
- ☐ Seizures
- ☐ Altered mentation

Pituitary apoplexy is a syndrome consisting of headache, altered mental status, visual field defects, and ophthalmoplegia secondary to a pituitary hemorrhage. A pituitary tumor is the usual cause. Its presentation ranges from “silent” (no signs or symptoms), to mildly symptomatic, to acute and life-threatening. The presenting signs and symptoms, in order of decreasing frequency, are headache, visual disturbances, ocular palsies, nausea, vomiting, altered mentation, meningismus, hemiparesis, and fever.² Seizures are not seen.

The differential diagnosis of pituitary apoplexy depends on its presentation. In our patient, other common disorders that must be considered are subarachnoid hemorrhage and bacterial meningitis. An imaging study, such as a CT scan of the brain, can usually distinguish between pituitary apoplexy and hemorrhage or meningitis. Lumbar puncture is thought to be less reliable because pleocytosis, elevated protein, increased red cell counts, and xanthochromia may be seen in the cerebrospinal fluid in pituitary apoplexy.³

A number of endocrinopathies can result from pituitary apoplexy. The most life-threatening is acute adrenal insufficiency due to loss of adrenocorticotrophic hormone. Therefore, all patients with apoplexy should receive corticosteroid supplementation until adrenal insufficiency is ruled out. Other common resulting endocrinopathies include hypothyroidism and hypogonadism.

Case continued

The patient underwent a cosyntropin stimulation test, which ruled out adrenal insufficiency. He began insulin therapy to manage his elevated blood glucose. A neurosurgical consult was obtained. A further review of systems revealed a decreased libido, increased inter-

dental spaces, and enlargement of his hands and feet (his shoe size had increased 3.5 sizes since age 21). Acromegaly was suspected, and further laboratory investigations were done.

■ ACROMEGALY

3 Which one of the following laboratory results would *not* be expected in acromegaly?

- ☐ Elevated growth hormone
- ☐ Elevated serum phosphorus
- ☐ Normal prolactin level
- ☐ Low insulin-like growth factor-1
- ☐ Elevated urine calcium

Acromegaly is the result of an excess of growth hormone (GH), leading to elevated levels of insulin-like growth factor-1 (IGF-1). It has an annual incidence of three to four cases per million and is associated with a twofold to threefold increase in mortality.⁴ It affects women and men equally. The elevated IGF-1 levels lead to characteristic overgrowth of bones and soft tissue. Other common clinical manifestations are listed in **TABLE 2**.⁵

Laboratory manifestations of acromegaly include elevated levels of GH and IGF-1—a low IGF-1 level should not be seen. Other laboratory abnormalities include an elevated serum phosphorus level (due to increased renal tubular reabsorption), an elevated serum glucose level (due to the anti-insulin effect of GH), and an elevated urine calcium level (due to increased levels of 1,25-dihydroxyvitamin D). Hypercalcemia is not a characteristic and should suggest that the diagnosis of acromegaly is part of a larger syndrome, ie, multiple endocrine neoplasia, type 1 (MEN-1). Hyperprolactinemia, due to pituitary stalk compression and loss of the inhibitory influence of dopamine, can also be seen.

Acromegaly often goes undiagnosed for a long time because it is insidious in its onset and progression. The diagnosis is often made by a consulting physician who, unlike the patient's primary physician, has not followed the patient long-term and is more likely to notice the classic physical signs of acromegaly.

All patients with pituitary apoplexy should receive corticosteroids at presentation

TABLE 2

Common clinical manifestations of acromegaly

General

Fatigue
Heat intolerance
Weight gain

Skin

Acral growth (hands and feet)
Doughy and oily skin
Skin tags
Hypertrichosis
Hyperhidrosis
Coarsening of facial features

Head and neck

Headaches
Frontal bossing
Parotid enlargement
Goiter

Eyes

Visual field defects

Nose and throat

Increased tongue size
Widely spaced teeth
Voice change
Sinus congestion

Cardiorespiratory

Cardiomegaly
Congestive heart failure
Hypertension

Gastrointestinal

Hepatosplenomegaly
Cholelithiasis
Colonic polyps

Endocrinologic

Decreased libido
Infertility
Oligomenorrhea
Glucose intolerance, diabetes
Hyperlipidemia

Neurologic

Paresthesia
Carpal tunnel syndrome

Musculoskeletal

Proximal myopathy
Arthralgia
Osteoarthritis

A consensus panel recommends surgery for most patients with acromegaly

Once the diagnosis is suspected, confirmation is straightforward. An elevated level of IGF-1 almost always confirms the diagnosis of acromegaly.⁵ GH levels are not as reliable, because GH is secreted in pulses several hours apart.

Case continued

Further laboratory investigations revealed an elevated GH level of 19.6 ng/mL (normal 0–3.0 ng/mL) and an elevated IGF-1 level of 1,030 ng/mL (normal for men 402–839 ng/mL).

Other lab results were:

- Thyroid-stimulating hormone 0.62 μ U/mL (normal 0.5–4.5 μ U/mL)
- Free thyroxine (T₄) 0.8 ng/dL (normal 0.9–2.4 ng/dL)
- Follicle-stimulating hormone 2.0 mU/mL (normal for men 3–15 mU/mL)
- Luteinizing hormone 0.9 mU/mL (normal for men 3–15 mU/mL)
- Prolactin 3.8 ng/mL (normal for men < 15 ng/mL)
- Serum testosterone 22 ng/dL (normal 220–1,000 ng/dL).

Diagnosis. Acromegaly presenting as pituitary apoplexy.

TREATMENT OF ACROMEGALY

4 The goals of treatment include which of the following?

- ☐ Return of GH and IGF-1 levels to normal
- ☐ A decrease or stabilization in tumor size
- ☐ Maintenance of normal pituitary function
- ☐ All of the above

All of the above are reasonable treatment goals.⁶ The treatment options include surgery (transsphenoidal adenoma resection), radiotherapy, and medical therapy.

Transsphenoidal resection results in a “cure” (typically defined as clinical improvement and GH levels below 5 ng/mL) in approximately 60% of patients.⁵ Iatrogenic hypopituitarism develops in 5% to 17% of patients.⁷

Radiotherapy is generally reserved for adjunctive treatment if surgery fails to normalize GH and IGF-1 levels or control symptoms. Its primary drawback is the length of time required to see a significant response. Standard external-beam irradiation (4,500 to 5,000 rad given over 5 to 6 weeks) produces a 50% reduction in GH levels at 2 years.⁸ Gamma knife radiosurgery is undergoing investigation.

Medical therapy includes dopamine agonists (eg, bromocriptine and pergolide) and

octreotide, a somatostatin analogue. Somatostatin, among its many actions, regulates the release of GH. Octreotide therapy is effective in decreasing tumor size and in normalizing GH and IGF-1 levels.⁹ It decreases GH levels to below 5 ng/mL in more than 50% of patients and begins lowering GH levels within hours of its administration. In contrast, dopamine agonists achieve such GH levels in only 12% of patients.⁴

Recommendations. For macroadenomas (> 10 mm), the 1994 Acromegaly Therapy Consensus Development Panel⁴ recommended transsphenoidal surgery as the best therapeutic option in patients deemed good surgical candidates. Octreotide or radiotherapy is used as an additive treatment if surgical therapy does not normalize GH and IGF-1 levels or control symptoms. Octreotide is a first-line treatment for patients who are not good surgical candidates.

Case resolution

The patient underwent a transsphenoidal adenoma resection. His GH, IGF-1, and glucose levels normalized afterward. To date, he has had partial resolution of his third nerve palsy.

REFERENCES

1. Horton JC. Disorders of the eye. In Fauci A, Braunwald E, Isselbacher KJ, Wilson J, editors. *Harrison's principles of internal medicine*. 14th edition. New York: McGraw-Hill, 1998;159-172.
2. Rolih CA, Ober KP. Pituitary apoplexy. *Endocrinol Metab Clin North Am* 1993; 22:291-301.
3. Conomy JP, Ferguson JH, Brodkey JS, Mitsumoto H. Spontaneous infarction in pituitary tumors: Neurologic and therapeutic aspects. *Neurology* 1975; 25:580-587.
4. Acromegaly Therapy Consensus Developmental Panel. Consensus statement: Benefits versus risks of medical therapy for acromegaly. *Am J Med* 1994; 97:468-473.
5. Maugans TA, Coates ML. Diagnosis and treatment of acromegaly. *Am Fam Physician* 1995; 52:207-213.
6. Biller BMK, Daniels GH. Neuroendocrine regulation and diseases of the anterior pituitary and hypothalamus. In Fauci A, Braunwald E, Isselbacher KJ, Wilson J, editors. *Harrison's principles of internal medicine*. 14th edition. New York: McGraw-Hill, 1998;1972-1999.
7. Ross DA, Wilson CB. Results of transsphenoidal micro-surgery for growth hormone-secreting pituitary adenoma in a series of 214 patients. *J Neurosurg* 1988; 68:854-867.
8. Eastman RC, Gordon P, Roth J. Radiation therapy of acromegaly. *Endocrinol Metab Clin North Am* 1992; 21:693-712.
9. Lamberts SWJ, Van Der Lely AJ, De Herder W, Hofland LJ. Octreotide. *N Engl J Med* 1996; 334:246-253.

ADDRESS: Craig Nielsen, MD, Department of Internal Medicine, P39, The Cleveland Clinic Foundation, 9500 Euclid Avenue, Cleveland, OH 44195.



THE CLEVELAND CLINIC FOUNDATION

11th Annual

INTENSIVE REVIEW OF INTERNAL MEDICINE

Featuring:

Board simulation sessions
Interactive computer system
for lectures and simulation sessions

June 6-11, 1999

Renaissance Cleveland Hotel
Cleveland, Ohio

For further information, write or call:

The Cleveland Clinic Educational Foundation
Continuing Education Department
9500 Euclid Avenue, TT-31
Cleveland, OH 44195

216-444-5695 800-762-8173 216-445-9406 (Fax)

CORRECTION

The answers to the CME quiz on page 17 of the January 1999 issue contained an error. The answer to question 1, "Which structure in the brain is not a target for chronic electrical stimulation?" should have been D, "Substantia nigra pars compacta," not C as listed.

We apologize for this error, and thank Drs. William McNally of Aiken, SC, Rita Kralik of Gates Mills, OH, G.M. Clark of Dallas, TX, and Maurice Rotbart of Ft. Bragg, CA, for pointing it out.