

**RONALDO S. CARNEIRO, MD**Department of Plastic Surgery, Cleveland Clinic Florida;  
specializing in hand surgery and microsurgery

# Carpal tunnel syndrome: The cause dictates the treatment

## ■ ABSTRACT

Mild carpal tunnel syndrome should be conservatively treated and severe carpal tunnel syndrome usually requires surgery; however, management of moderate carpal tunnel syndrome is more complex. Usually, the treatment is dictated by the cause, which may be occupational injury, acute trauma, systemic diseases such as diabetes, hypothyroidism, or rheumatoid arthritis, or other causes.

## ■ KEY POINTS

Physical signs (sensory deficit, atrophy of the hand muscles, positive Phalen test, Tinel sign) can be used to categorize carpal tunnel syndrome as mild, moderate, or severe.

Conservative measures (splinting at night, use of nonsteroidal anti-inflammatory drugs) should be the first treatment and usually suffice in mild cases, but patients with severe cases should be referred for surgery.

In moderate cases, choice of treatment depends on the cause of the carpal tunnel syndrome. Elderly patients may have a stronger indication for surgery. Patients with hypothyroidism or diabetes usually improve with good control of the underlying disease.

**T**HE POPULAR NOTION that repetitive trauma is the only cause of carpal tunnel syndrome is untrue—it has a number of causes. Not all patients require surgery. Mild cases can usually be treated conservatively, and in moderate carpal tunnel syndrome, treatment depends on the cause.

This article describes how to determine the severity of carpal tunnel syndrome and choose treatment options, and when to refer the patient to a surgeon.

## ■ CAUSES

Carpal tunnel syndrome can be caused by a variety of conditions that put pressure on the median nerve where it goes through the confines of the tunnel formed by the wrist bones dorsally and a retinacular ligament volarly (FIGURE 1).

The older population has a high incidence of “senile carpal tunnel syndrome” due to shifting of the carpal bones, which causes a decrease in the diameter of the tunnel through which the median nerve passes.

Other causes of carpal tunnel syndrome include synovitis, pregnancy, diabetes, thyroid imbalance, acute trauma, and post-trauma deformity. Other systemic diseases such as amyloidosis, alcoholism, acromegaly, gout, and obesity have also been implicated.<sup>1,2</sup>

## ■ DIAGNOSIS

### History

Patients describe tingling and decreased sensation in the fingertips, and report difficulty handling small objects, driving, holding a book while reading, handwriting, using a com-

TABLE 1

### Carpal tunnel syndrome: Classification and treatment according to physical signs

CLASSIFICATION	SENSORY DEFICIT	TINEL SIGN	PHALEN SIGN	ATROPHY	TREATMENT
Mild	Mild	Absent	> 30 seconds	Absent	Splinting plus anti-inflammatory drugs
Moderate	Moderate	Faint	≈ 30 seconds	Incipient	See TABLE 2
Severe	Severe	Strong	< 30 seconds	Advanced	Surgery

\*This classification scheme is intended as a rough estimate of severity. Electromyographic and nerve conduction studies are instrumental in determining a final classification (see text).

puter keyboard, or other activities that are repetitive, delicate, or require using the hand with the wrist in a fixed position.

A characteristic symptom is waking at night with paresthesias or "cramps" in the hand. Patients often report that they must shake the hand to return sensation to the fingertips. They often ascribe this phenomenon to lack of circulation, and compare it to the sensation one gets when sitting in the same position for a long time and the "foot goes to sleep."

Decreased sensation is confined to the areas supplied by the median nerve (unless the patient also has ulnar nerve compression, in which case decreased sensation affects the entire hand). Patients complain of decreased sensation in the thumb and middle finger, but if the disease is severe or if the patient is especially observant, he or she notes that the thumb, index finger, middle finger, and half the ring finger are affected, but the small finger is not.

#### Physical examination

**Sensory testing.** Although different physicians use different methods of testing for decreased sensation, I favor the two-point discrimination test or the nylon cord test, because results of these tests are quantifiable and reproducible. Either test is acceptable (TABLE 1).

- *Two-point discrimination test.* The patient is asked to distinguish whether the physician is touching the volar aspect of the

finger with one or with two blunt points, which are separated by increasing distances (DeMayo 2-Point Discrimination Device; Padgett Instruments, Kansas City, MO). Normally, persons can distinguish two points approximately 0.4 mm apart at the fingertips. A two-point discrimination of 0.6 cm represents a very mild sensory deficit; 0.8 cm, a moderate deficit.

- *Nylon cord test.* The physician touches the patient's finger with a succession of thin nylon monofilaments of increasing stiffness (Hand Filament Set; Sensory Testing Systems, Baton Rouge, LA) until the patient can feel it. A person with normal sensation can perceive monofilaments with 0.05 to 0.2 g of resistance at the fingertips. A person with severely affected hands might only be able to feel filaments of 2 g resistance or more.

- *Decreased vibratory sensation,* although subtle, is very often the first detectable physical sign.

**The Tinel sign** is a tingling sensation in the area of the median nerve distribution, provoked by delicate finger percussion at the site of the compression. This is a frequent finding, especially when there is a "pseudoneuroma," ie, swelling of the nerve just proximal to the compression.

**The Phalen test,** devised by hand surgeon George S. Phalen during his tenure at the Cleveland Clinic Foundation, involves hyperflexing the wrist and keeping it flexed for up to 60 seconds, while the examiner times the interval until the patient feels the characteris-

**Start with  
NSAIDs and  
splinting at  
night**



tic tingling and numbness of carpal tunnel syndrome.<sup>3</sup> The more quickly the tingling and numbness appear, the more severe the carpal tunnel syndrome. The physiologic basis of the test is that the diameter of the carpal tunnel decreases during wrist flexion, increasing compression of the nerve.

**Atrophy of the thenar muscles or the abductor pollicis brevis muscle.** Atrophy of the thenar muscles is characterized by weak opposition of the thumb against resistance by the examiner—a useful test for decreased strength. Atrophy of the thenar muscles is usually present in long-standing cases. Weak grip and occasionally weak pinch strength may also be present. An atrophic abductor pollicis brevis is readily noticeable by flattening of the radial aspect of the thenar eminence.

**Decreased sweating** in the median nerve distribution is present in severe cases.

**Electromyography and nerve conduction studies.** The most accurate ancillary test is electromyography with a nerve conduction study.<sup>4</sup> Electromyographic findings can be used to classify cases of carpal tunnel syndrome as mild, moderate, or severe, although the criteria vary somewhat at different laboratories. The generally accepted electrodiagnostic criteria for a severe case are: absent median sensory response with prolonged median motor latencies, decreased median motor amplitudes, and fibrillation potentials in median innervated muscles. Electromyographic findings do not determine the need for surgery, but do help validate the indications. Electromyography is also useful in distinguishing true carpal tunnel syndrome from other conditions such as cervical spine compression, pronator syndrome, diabetic neuropathy, or other forms of neuropathy.

## ■ TREATMENT

For most patients with carpal tunnel syndrome, initial treatment should be conservative: nonsteroidal anti-inflammatory drugs (if the patient has no contraindications to them) and use of a splint at night. Further treatment depends on the severity of the disease, the cause, and the success of initial treatment. A rough classification scheme, based on a pre-

ponderance of signs, symptoms, and test results, is presented below.

### **Mild cases: Conservative treatment indicated**

In general, carpal tunnel syndrome is considered mild if the patient has most of the following:

- No atrophy of the thenar muscles
- A positive Phalen test after more than 30 seconds
- An absent or very faint Tinel sign
- A very mild sensory deficit as shown by a two-point discrimination of 0.6 cm.
- *Intermittent* symptoms of numbness and tingling, usually in specific circumstances such as during sleep or driving. (Conversely, the patient has no symptoms during most of his or her day.)

In mild cases, night splinting and anti-inflammatory drugs generally suffice.

### **Moderate cases: Treatment depends on cause**

In general, carpal tunnel syndrome is considered moderate if the patient has most of the following:

- Incipient atrophy of the thenar muscles
- A positive Phalen test in approximately 30 seconds
- A very faint Tinel sign
- A moderate sensory deficit as shown by a two-point discrimination of 0.8 cm.

In this situation, further treatment depends on the cause (TABLE 2).

**In occupational carpal tunnel syndrome,** try splinting, anti-inflammatory drugs, and a change in the work station. An occupational therapist can help by visiting the patient's work site and suggesting ergonomic changes. For example, if the patient uses a computer, one could try changing the physical set-up by raising or lowering the chair, computer monitor, or keyboard to bring the patient into proper alignment. If he or she uses the phone handset extensively while entering data, switching to a headset may be more comfortable. If these measures are not successful, surgical release of the carpal tunnel may be indicated.

**In "senile" carpal tunnel syndrome,** even a small amount of atrophy constitutes a strong indication for a surgical release procedure. Surgery should be considered sooner in elderly patients than in other groups because

**Ergonomic changes may relieve symptoms**



TABLE 2

### Treatment of moderate carpal tunnel syndrome after failure of splinting

UNDERLYING CONDITION	FIRST STEP	SECOND STEP
Occupational	Work station changes	Surgical release
Senile	Surgical release	
Synovitis	Corticosteroid injection	Surgical release plus synovectomy
Pregnancy	Edema control	Surgical release; local anesthesia
Metabolic conditions	Diabetes or thyroid control	Surgical release
Acute trauma	Surgical release	
Post-trauma deformity	Deformity correction	Surgical release

they have less capacity to recover once atrophy becomes established.

If the patient has synovitis due to rheumatoid arthritis or another inflammatory disease, one can give one cortisone injection into the carpal tunnel. This injection has to be very carefully performed to avoid injuring the nerve with the needle.<sup>5</sup> If this procedure fails to relieve the problem or if the relief is brief and the symptoms recur, the patient should be referred for surgical release of the carpal tunnel plus a synovectomy of the flexor tendons. Synovectomy should be performed by the open technique.

If the patient is pregnant, it is advisable to wait as long as possible before resorting to surgery, since symptoms usually abate after parturition.<sup>6</sup> We recommend splinting, but no anti-inflammatory drugs. Edema control is a salient part of the treatment, and this is left to the obstetrician. However, if symptoms are causing the patient extreme discomfort (eg, if she is losing sleep or having difficulty with work or is upset because of the constant presence of the symptoms), a surgical release procedure under local anesthesia is indicated.

If the patient has diabetes, good glycemic control and splinting are a priority. Of note, if diabetes has been uncontrolled for a long time, diabetic neuropathy may be contributing to symptoms. An electromyogram can usually differentiate patients with diabetic neuropathy plus carpal tunnel syndrome from those with neuropathy only. Whether surgery will relieve symptoms depends on the severity of nerve degeneration.

In hypothyroid patients, correcting the levels of thyroid hormones may decrease mild symptoms. Splinting is indicated, especially at night.

**Acute trauma.** As a general rule, if carpal tunnel syndrome develops after a traumatic injury to the distal forearm or wrist (ie, fractures of the distal radius), consider immediate surgical release. The compression of the nerve is probably due to bleeding inside the carpal tunnel, which can lead to other complications such as adhesions between tendons, and nerve and intraneural hematomas leading to necrosis or scarring of the nerve.

**Post-trauma deformities** that cause carpal tunnel syndrome are usually a consequence of a fracture of the distal radius resulting in a malunion. The abnormal shape of the radius decreases the space inside the carpal tunnel and applies pressure to the nerve from a dorsal-to-volar direction. If the deformity is severe, consider surgery to correct the deformity and release the carpal tunnel during the same operation. If the deformity is not severe and function is good, simple release of the carpal tunnel is indicated.

#### Severe cases: Surgery probably is indicated

In general, carpal tunnel syndrome is considered severe if the patient has most of the following:

- Atrophy of the thenar muscles
- A positive Phalen test in less than 30 seconds
- A positive Tinel sign
- An extreme sensory deficit

**For pregnant patients, we try splinting and edema control—but no NSAIDs**





## ■ Anatomy, signs, and symptoms of carpal tunnel syndrome

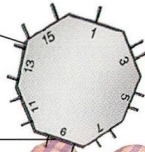
### COMPRESSION OF THE MEDIAN NERVE

where it passes through the carpal tunnel leads to the signs and symptoms of carpal tunnel syndrome, as shown below

### SENSORY DEFICIT

as shown by a two-point discrimination of 0.6 cm or more

DeMayo 2-point discrimination device



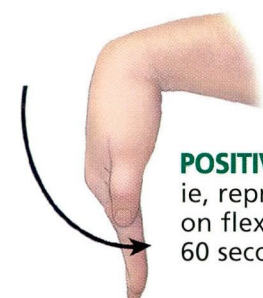
### NUMBNESS AND TINGLING

in the area of distribution of the median nerve (shaded area)

### ATROPHY

of the thenar muscles

**TINEL SIGN**, ie, reproduction of the symptoms on percussion in the wrist



**POSITIVE PHALEN TEST**, ie, reproduction of the symptoms on flexion of the wrist for up to 60 seconds

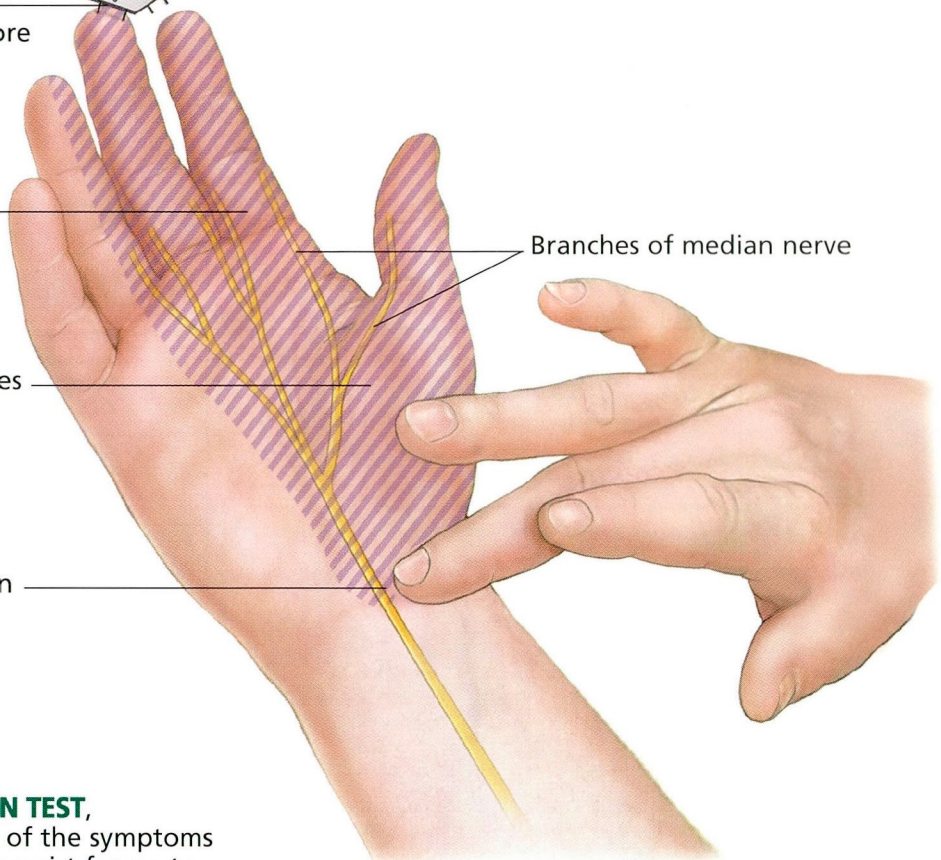
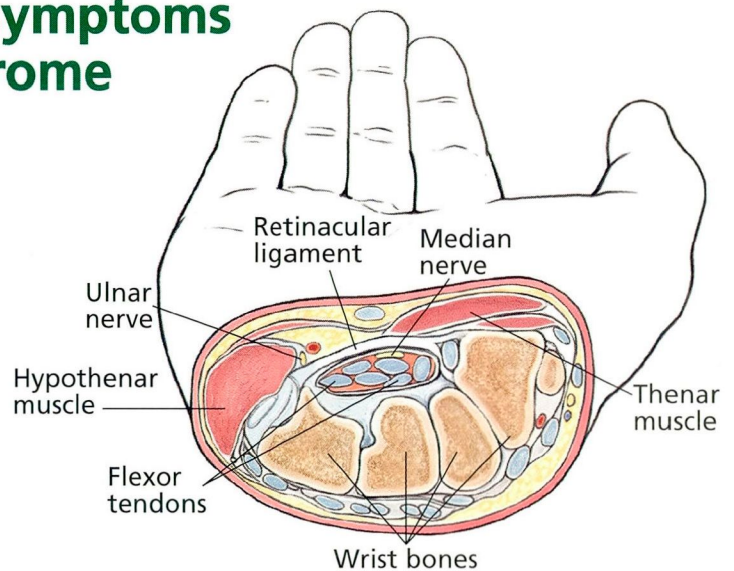


FIGURE 1





- Electromyographic criteria for severe disease.

Such patients should be referred to a hand surgeon, as they have a strong indication for surgical release of the carpal tunnel.

## ■ SURGICAL RELEASE TECHNIQUES

The choice of technique for surgical release has been a subject of much controversy lately.

**The traditional technique** requires a large incision that starts in the palm of the hand and zigzags into the wrist. This approach affords a good view of the nerve, which at all costs we wish to avoid damaging. However, the technique also has disadvantages. The incision crosses the area in the palm of the hand that has the most innervation, and therefore it can produce secondary problems such as hypersensitive and hypertrophic scars in the wrist and heel of the hand. To avoid these consequences, other methods have been developed.

**The endoscopic technique** is performed through one or two small incisions,<sup>7</sup> using an endoscope to visualize and release the ligament. This is a good technique, but has resulted in multiple severe complications due to damage to

the nerve, which is not well visualized.

**The minimally invasive technique** was designed as a compromise between the other methods. A very small incision is made in the palm of the hand and the ligament is incised utilizing a specific instrument (the retinaculotome; Ruggles Corporation, Atlanta, GA) with the median nerve under direct visualization.<sup>8</sup> In the last 4 years, I have performed about 500 carpal tunnel releases employing this technique, with no severe complications or hypertrophic or hypersensitive scars resulting. It is now my method of choice. The surgery is performed on an outpatient basis. Anesthesia consists of a nerve block or local anesthesia with sedation, which minimizes risk. The recovery period is about 10 days. The patient usually returns for follow-up 3 days after surgery and wears a splint for 7 days to allow full motion of the digits yet limit wrist motion. Usually, no further therapy is needed.

An analysis of 123 consecutive patients surveyed by written questionnaire showed a decrease in discomfort of 5.5 to 10 points on a visual scale of 10, even though 74.7% of patients had had severe disease. There were no recurrences or repeat operations in 3 to 5 years of follow-up.<sup>8</sup>

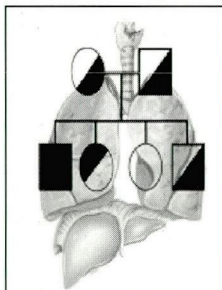


## ANNOUNCING

### The Alpha One Foundation Research Registry for individuals diagnosed with **Alpha<sub>1</sub>-Antitrypsin Deficiency**

*Enroll your patients in the Alpha One Research Registry, the only one of its type in the United States.*

*Patients and their physician will have an opportunity to participate in clinical trials and research protocols to develop new therapies.*



*All data is confidential and managed by the University of Miami School of Medicine Department of Epidemiology and Public Health*

**For Patient Enrollment  
Call 1-888-825-7421 Ext.6**

*Visit The Alpha One Foundation on the Web at  
[www.alphaone.org](http://www.alphaone.org) or E-mail us at [registry@alphaone.org](mailto:registry@alphaone.org)*

## ■ REFERENCES

1. Grokoe AW, Deruartei FE. Systemic disease and the carpal tunnel syndrome. *JAMA* 1954; 155:635.
2. Stallings S, Kasdan M, Soergel T, Corwin H. A case-control study of obesity as a risk factor for carpal tunnel syndrome in a population of 600 patients presenting for independent medical examination. *J Hand Surg* 1997; 22A:211-215.
3. Phalen GS, Kendrick JL. Compression neuropathy of the median nerve in the carpal tunnel. *JAMA* 1957; 164:524-530.
4. Buchtal F, Rosenflack A, Trojaborg W. Electrophysiological findings in entrapment of the median nerve at the wrist and elbow. *J Neurol Neurosurg Psychiatry* 1974; 37:340-360.
5. Green DP. Diagnostic and therapeutic value of carpal tunnel injection. *J Hand Surg* 1987; 9A:850-854.
6. Gould JS, Wissinger HA. Carpal tunnel syndrome in pregnancy. *South Med J* 1978; 71:144-145.
7. Agee JM, McCarrol HR, Tortosier RD, Berry DA, Szabo RM, Peimer CA. Endoscopic release of the carpal tunnel: A randomized prospective multicenter study. *J Hand Surg* 1992; 17A:987-995.
8. Carneiro RS, James KW. Release of carpal tunnel syndrome with the retinaculotome. *Annals of the 6th Congress of the International Federation of Surgery of the Hand*. Monduzzi Editore, 1995.

**ADDRESS:** Ronaldo S. Carneiro, MD, Cleveland Clinic Florida, 6101 Pine Ridge Road, Naples, FL 34119.