

**STEVEN D. MAWHORTER, MD**

Department of Infectious Disease, Cleveland Clinic;
research interests in clinical infectious disease, travel
medicine, and the immunology of infections

Nonhealing cellulitis in a 54-year-old man with diabetes mellitus

A 54-YEAR-OLD MAN with type 1 (insulin-dependent) diabetes mellitus presents to the emergency department with a 1-week history of fever with temperatures as high as 103°F (39.4°C) and progressive erythema, warmth, swelling, and tenderness of his left medial thigh. He says he has not had any trauma to this area. He is admitted to the hospital and receives clindamycin 900 mg intravenously every 8 hours. Though his white blood cell count declines from 22.0 to 12.0 × 10⁹/L, he continues to have significant pain and cutaneous signs consistent with cellulitis.

Initial evaluation

Blood cultures are negative. A duplex ultrasound scan is negative for deep vein thrombosis. Plain radiographs of the left thigh show no gas, foreign body, or evidence of osteomyelitis. Magnetic resonance imaging (MRI) reveals diffuse changes in soft tissue and muscle without the fascial enhancement that is consistent with diffuse infiltrative edema or inflammatory disease (FIGURE 1). No discrete abscess is noted.

The patient is transferred to a tertiary care center for further management.

Physical examination. On admission, the patient's temperature is 99.9°F (37.7°C), and his blood pressure is 142/84 mm Hg. His left thigh is slightly red and warm, with extremely tender "woody" induration. The balance of his examination is normal, with no evidence of cutaneous anesthesia, nerve entrapment, or neuropathy. Computed tomography (CT) performed 24 hours after his MRI scan now shows ring-enhancing lesions in the deep muscles of the medial left thigh (FIGURE 1). Aspiration and culture of the lesions is performed.

WHAT IS THE DIAGNOSIS?

1 What is the most likely diagnosis in this case?

- ☐ Improper antibiotic therapy of cellulitis
- ☐ Diabetic myonecrosis
- ☐ Pyomyositis
- ☐ Traumatic hematoma

Improper antibiotic therapy of cellulitis needs to be considered but is unlikely in this patient. The specific bacterial etiology of cellulitis is often not known. A leading edge culture (not done in this case) is instructive only 30% of the time at best. (A leading edge culture is performed by inserting a needle in the subcutaneous tissue and aspirating the inflamed interface between normal and cellulitic tissue.) Published data indicate that clindamycin usually covers the most likely organisms found in typical cellulitis—staphylococci, streptococci, and rare anaerobes.

Aside from diabetes mellitus, this patient has no obvious immunocompromising conditions that might limit antibiotic effectiveness. However, in a diabetic patient, a wider range of organisms may be responsible for unresponsive cellulitis. For example, if the cellulitis is severe, we need to consider synergistic necrotizing cellulitis, also called synergistic non-clostridial myonecrosis, in which Gram-negative organisms often contribute as part of a mixed aerobic and anaerobic infection. A combination of a beta-lactam and a beta-lactamase inhibitor, such as piperacillin-tazobactam or ticarcillin-clavulanate or a carbapenem, provides appropriate broader coverage.

Necrotizing fasciitis, which is very similar to the synergistic cellulitis-myonecrosis

If cellulitis does not respond to antibiotics in a diabetic patient, look for another diagnosis

Pyomyositis has a subacute presentation

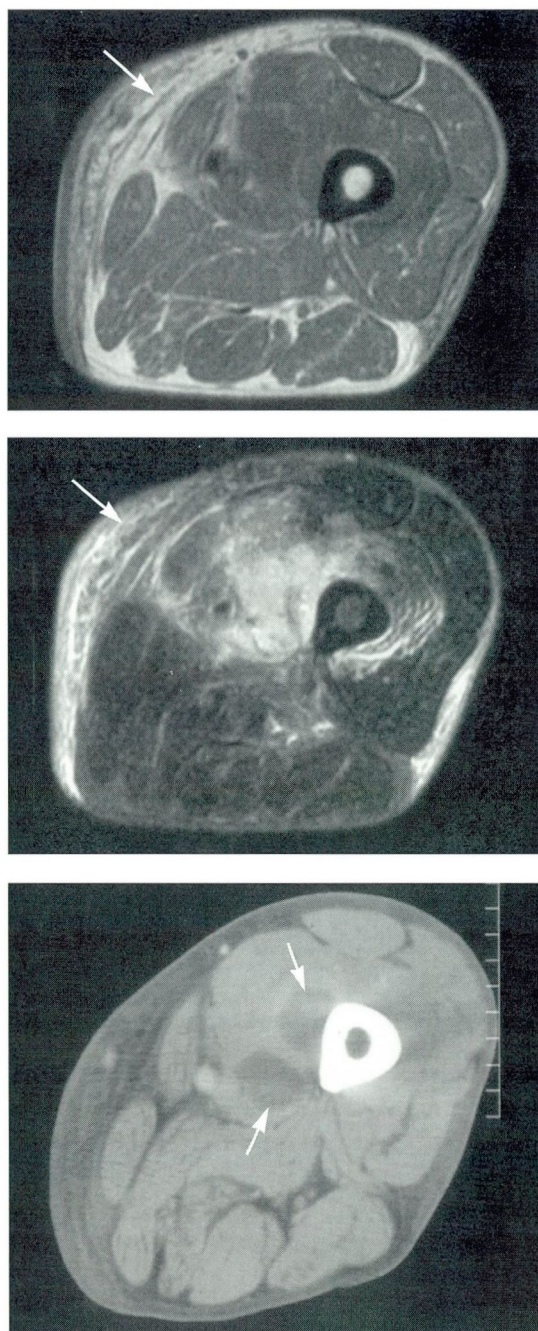


FIGURE 1. Magnetic resonance imaging (MRI) and computed tomographic (CT) studies of the patient's thigh, demonstrating the clinical progression of pyomyositis. T1-weighted MRI (**top**) and T2-weighted MRI (**middle**) demonstrate diffuse inflammation (bright, increased signal on T2) without focal abscess. **Bottom**, CT scan the next day shows a hypodense abscess (pyomyositis) medial to the femur.

syndromes mentioned above, is another possibility. It can be caused by group A *Streptococcus pyogenes*, *Clostridium* species, or mixed aerobic and anaerobic bacteria. It typically proceeds rapidly through extreme pain to cutaneous anesthesia with bullae formation, not seen in this case.¹ It should be emphasized, however, that surgical consultation with full-thickness biopsy or exploration is appropriate when patients have signs and symptoms of toxemia or the diagnosis is uncertain. Gas production in tissues is too unreliable a sign to use in ruling in or ruling out severe myocutaneous infection.

Diabetic myonecrosis, an uncommon complication of diabetes mellitus, was first described in 1965² and is believed to result from atherosclerotic and diabetic microangiopathic vascular infarction of skeletal muscle. It typically involves the thigh muscles and presents with severe pain over days to weeks, evolving into a well-defined mass-like lesion. Cultures are negative and treatment is supportive, usually without antibiotics.³ Unfortunately, lesions recur or new ones arise in 42% of cases.⁴

This patient had no other diabetic microangiopathic organ involvement and had positive aspirate cultures, making diabetic myonecrosis less likely.

Traumatic hematomas can be difficult to differentiate from abscesses. Hematomas appear nearly identical to abscesses on CT, and become visible early on both CT and MRI. In addition, hematomas can become secondarily infected. Since the immune system mounts an acute inflammatory reaction that assists in resolving even sterile hematomas, one may even observe fever and local signs similar to those of infection.

This patient did not use anticoagulants or have a history of trauma, making this possibility unlikely.

Pyomyositis—a pyogenic infection of the skeletal muscle—is due to *Staphylococcus aureus* in more than 90% of cases.^{5,6} It may arise by deeper extension from cellulitis, or by direct hematogenous seeding of the muscle. This condition typically has a subacute presentation with fever, persistent severe pain, tenderness, swelling, and “woody” induration. In contrast, myositis with rhabdomyolysis has

a more acute onset and muscle swelling with “bogginess.” The most commonly infected muscles are those of the thigh. Pyomyositis is uncommon but has an increased incidence in diabetic patients.⁵

Though classically described in patients from tropical climates who are otherwise normal, pyomyositis has been noted in immunocompromised patients in temperate climates. Various theories attempt to explain a geographic distribution of this disease, though limited access to timely medical care, more common in tropical locations, is plausible.

This case fulfills all the classic features of pyomyositis in a diabetic patient in a temperate climate.

■ WHAT IS THE EVALUATION?

2 Evaluation of nonhealing cellulitis in a patient with diabetes should include all except which one of the following?

- ☐ Blood cultures
- ☐ Muscle enzyme determinations
- ☐ Ultrasonography, CT, MRI, or all three
- ☐ Aspiration and culture
- ☐ Electromyographic testing

Blood cultures are positive in 5% to 29% of diabetic patients with pyomyositis, though it is often unclear whether positive results represent an original bacteremia or seeding from the infected muscle.⁵ Conversely, autopsy studies found spontaneous muscle abscesses in fewer than 1% of patients who died of staphylococcal septicemia.⁵

Muscle enzyme determinations (ie, serum concentrations of creatine phosphokinase, aspartate, aminotransferase, lactate dehydrogenase, and aldolase) are usually normal in pyomyositis,⁶ in spite of extensive associated myonecrosis. The primary utility of these tests may lie in helping to exclude rhabdomyolysis and necrotizing fasciitis, in which they are more commonly elevated. Given the severity of these conditions, it is reasonable to check these enzymes.

Radiographic imaging has several roles in evaluating unresponsive cellulitis. For example, ultrasonography can help document deep venous thrombosis, which can occasionally

mimic cellulitis and does not respond to antibiotics. Ultrasonography can also demonstrate local fluid collections. However, CT and MRI provide much more detail and give important information about the extent of disease and the involvement of adjacent structures, such as possible bony involvement in a case of pyomyositis due to contiguous osteomyelitis.³ In addition, an imaging test can pinpoint the abscess, which would facilitate the drainage procedure.

A word of caution: Since severe group A streptococcal fasciitis does not produce gas, lack of gas on radiographic studies should not delay an aggressive evaluation in cases in which necrotizing fasciitis is suspected.¹

As in any abscess-associated infection, definitive treatment involves antibiotics and adequate drainage of the abscess. In our case, **aspiration and culture** also confirmed the presence of oxacillin-sensitive *S aureus* in the involved muscle, providing useful data to guide antibiotic therapy. This culture result was obtained even though antibiotic therapy had already been started, demonstrating the benefit of draining abscesses therapeutically and diagnostically, even in patients on active therapy.

Electromyographic testing can be very helpful in diagnosing some forms of inflammatory myositis but does not have a role in this patient.

■ WHAT CAUSES PYOMYOSITIS?

3 Pyomyositis may develop as a result of all except which one of the following?

- ☐ Immunocompromised state
- ☐ Hematogenous spread during transient bacteremia
- ☐ Local spread from a contiguous bone or soft-tissue infection
- ☐ Prior muscle-infection by parasites in tropical pyomyositis

The etiology of pyomyositis is likely multifactorial.

Immunocompromise. In its nontropical form, pyomyositis tends to occur in immunocompromised hosts. Pyomyositis can be seen

Gas is an unreliable sign of severe myocutaneous infection



in the profound immunocompromised setting of AIDS, or the limited immune changes of diabetes.

Hematogenous spread. Patients with diabetes mellitus have an increased prevalence of nasal and cutaneous colonization with *S aureus*. They also have an increased incidence of *S aureus* infections, including internal seeding with bacteremia.⁷

However, as mentioned above, most patients with pyomyositis do not have positive blood cultures: most studies have found a rate of only approximately 5%, though this may vary. Hence, if bacteremic muscle seeding occurs, it likely happens during episodes of transient bacteremia not detected on blood cultures. An autopsy series of patients who died of *S aureus* bacteremia noted only 1% had muscle abscesses, emphasizing the rarity of occult pyomyositis.⁵ In experiments in rabbits with *S aureus* bacteremia, pyomyositis developed only after antecedent muscle trauma.

Local spread. In some cases, muscle abscess may develop from contiguous osteomyelitis or other soft-tissue infections. Occasionally, deep pyomyositis results from lymphatic spread of overlying cellulitis. CT and MRI studies may help establish or rule out these conditions.

Parasitic infection. In tropical pyomyositis, some experts have suggested that vigorous physical activity or prior muscle involvement from more prevalent parasites or viral diseases explains the increased rate of disease in otherwise-normal hosts. However, a case-control study⁸ found no increased rate of infection associated with malnutrition, myositis, or antecedent infection (bacterial, parasitic, or viral). Tropical pyomyositis may develop because of limited access to antibiotics, allowing minor *S*

aureus infections to progress to deeper muscle involvement. Of the possibilities given, this is the least likely in our patient.

SUMMARY: PURSUING ALTERNATIVE DIAGNOSES WHEN TREATMENT FAILS


Our case demonstrates the importance of continuing to pursue an alternative diagnosis vigorously when cellulitis does not respond to appropriate empiric antibiotic therapy in a patient with diabetes mellitus. It also points out the need for repetitive imaging studies to identify pyomyositis as it moves from the initial invasive stage to the purulent stage when the diagnosis is more easily made.

Definitive treatment, including drainage, is necessary to avoid the development of the late or septic stage. Woody induration with persistent pain in an ill patient without toxemia may be a particularly useful clue and should alert the clinician to the possibility of pyomyositis.

REFERENCES

1. File TM, Tan JS, Dispersio JR. Diagnosing and treating the "flesh-eating bacteria syndrome." *Cleve Clin J Med* 1998; 65:241-249.
2. Angervall L, Stener R. Tumoriform focal muscular degeneration in two diabetic patients. *Diabetologia* 1965; 1:39-42.
3. Scully RE, Mark EJ, McNeely WF, Ebeling SH, Phillips LD (editors). Weekly clinicopathological exercises. Case 29-1997. *N Engl J Med* 1997; 337:839-845.
4. Bodner RA, Younger DS, Rosokljia G. Diabetic muscle infarction. *Muscle Nerve* 1994; 17:949-950.
5. Walling DM, Kaeling WG Jr. Pyomyositis in patients with diabetes mellitus. *Rev Infect Dis* 1991; 13:797-802.
6. Dunkerley GR, Older J, Onwochei B, Pazienza J. Pyomyositis. *Am Fam Phys* 1996; 54:565-569.
7. Breen JD, Karchmer AW. *Staphylococcus aureus* infections in diabetic patients. *Infect Dis Clin North Am* 1995; 9:11-24.
8. Eason R, Osbourne J, Ansford T, Stallman N, Forsyth JRL. Tropical pyomyositis in the Solomon Islands: clinical and aetiological features. *Trans R Soc Trop Med Hyg* 1989; 83:275-278.

**Abscesses
require
antibiotics and
drainage**



**CME
CREDIT
TEST**

Category I CME Credit.
Test your knowledge
of clinical topics.

**IN THIS ISSUE
PAGE 71**

BRIEF SUMMARY — ARTHROTEC® (diclofenac sodium and misoprostol)

Before prescribing, please consult complete prescribing information.



CONTRAINDICATIONS AND WARNINGS

ARTHROTEC®, because of the abortifacient property of the misoprostol component, is contraindicated in women who are pregnant. (See **PRECAUTIONS**.) Reports, primarily from Brazil, of congenital anomalies and reports of fetal death subsequent to misuse of misoprostol alone, as an abortifacient, have been received. Patients must be advised of the abortifacient property and warned not to give the drug to others. ARTHROTEC should not be used in women of childbearing potential unless the patient requires nonsteroidal anti-inflammatory drug (NSAID) therapy and is at high risk of developing gastric or duodenal ulceration or for developing complications from gastric or duodenal ulcers associated with the use of the NSAID. (See **WARNINGS**.) In such patients, ARTHROTEC may be prescribed if the patient:

- has had a negative serum pregnancy test within two weeks prior to beginning therapy.
- is capable of complying with effective contraceptive measures.
- has received both oral and written warnings of the hazards of misoprostol, the risk of possible contraception failure, and the danger to other women of childbearing potential should the drug be taken by mistake.
- will begin ARTHROTEC only on the second or third day of the next normal menstrual period.

INDICATIONS AND USAGE

ARTHROTEC® is indicated for treatment of the signs and symptoms of osteoarthritis (OA) or rheumatoid arthritis (RA) in patients at high risk of developing NSAID-induced gastric and duodenal ulcers and their complications. See **WARNINGS—Gastrointestinal effects** for a list of factors that may increase the risk of NSAID-induced gastric and duodenal ulcers and their complications.

CONTRAINDICATIONS

See boxed **CONTRAINDICATIONS AND WARNINGS** related to misoprostol. ARTHROTEC is contraindicated in patients with hypersensitivity or allergic reaction to diclofenac, misoprostol, other prostaglandins, or aspirin/NSAIDs. Severe, rarely fatal, anaphylactoid reactions to diclofenac have been reported.

WARNINGS

Regarding diclofenac:

Gastrointestinal (GI) effects—risk of GI ulceration, bleeding and perforation: Serious GI toxicity, such as inflammation, bleeding, ulceration and perforation of the stomach, small intestine or large intestine, can occur at any time, with or without warning symptoms, in patients treated with NSAIDs. Remain alert for ulceration and bleeding, even in the absence of previous GI tract symptoms. Inform patients about the signs and/or symptoms and the steps to take if they occur. Only 1/5 patients who develop a serious upper GI adverse event on NSAID therapy is symptomatic. It has been demonstrated that upper GI ulcers, gross bleeding, or perforation, caused by NSAIDs, appears to occur in approximately 1% of patients treated for 3–6 months, and in 2–4% of patients treated for one year, with an increasing likelihood of developing a serious GI event during chronic therapy. However, even short-term therapy has risk. Prescribe NSAIDs with extreme caution in those with a prior history of ulcer disease or GI bleeding. Most spontaneous reports of fatal events are in elderly or debilitated patients and therefore special care should be taken in treating this population. To minimize the potential risk for an adverse event, the lowest effective dose should be used for the shortest possible duration. For very high-risk patients, alternate therapies that do not involve NSAIDs should be considered. Studies have shown that patients with a history of peptic ulcer disease and/or GI bleeding, and who use NSAIDs, have a greater than 10-fold risk for developing a GI bleed than patients with neither of these risk factors. In addition to a past history of ulcer disease, pharmacoeconomic studies have identified several other conditions or co-therapies that may increase the risk for GI bleeding, such as: treatment with oral corticosteroids, treatment with anticoagulants, longer duration of NSAID therapy, older age, smoking, alcoholism, poor general health and *H. pylori* positive status.

Hepatic effects: Elevations of liver tests may occur. Borderline elevations ($<3\times$ upper limit of normal, or ULN) or greater elevations of transaminases occurred in about 15% of diclofenac-treated patients. In clinical trials, meaningful elevations ($>3\times$ ULN) of AST (SGOT) occurred in about 2% of patients. Meaningful elevations of ALT and/or AST occurred in about 4%, and marked elevations ($>8\times$ ULN) in about 1% of patients treated 2–6 months. In an open-label trial, elevated ALT or AST was observed more often in patients receiving diclofenac than other NSAIDs. Postmarketing, rare cases of severe hepatic reactions, including liver necrosis, jaundice, and fulminant fatal hepatitis with and without jaundice have been reported; some underwent liver transplantation. Severe hepatic reactions can occur at any time without a prodrome of distinguishing symptoms. Transaminases should therefore be periodically measured beginning within 4 to 8 weeks after initiating treatment. The misoprostol component does not appear to exacerbate these diclofenac effects. If abnormal liver tests persist or worsen, if clinical signs and/or symptoms consistent with liver disease develop, or if systemic manifestations occur, discontinue ARTHROTEC treatment immediately. Inform patients of the warning signs and symptoms of hepatotoxicity (eg, nausea, fatigue, lethargy, pruritus, jaundice, right upper quadrant tenderness, and “flu-like” symptoms), and the appropriate action patients should take if these signs and symptoms appear.

Anaphylactoid reactions: Anaphylactoid reactions may occur in patients without known prior exposure to ARTHROTEC or its components. ARTHROTEC should not be given to patients with the aspirin triad. The triad typically occurs in asthmatic patients who experience rhinitis with or without nasal polyps, or who exhibit severe, potentially fatal bronchospasm after taking aspirin or other NSAIDs. Emergency help should be sought in cases where an anaphylactoid reaction occurs.

Advanced renal disease: In patients with advanced kidney disease, treatment with ARTHROTEC is not recommended.

PRECAUTIONS

General: ARTHROTEC cannot be used to substitute for corticosteroids or to treat for corticosteroid insufficiency. ARTHROTEC's anti-inflammatory activity may diminish the utility of this diagnostic sign.

Renal effects: Use caution when initiating ARTHROTEC in dehydrated patients. Rehydrate patients first. Also use caution in patients with kidney disease (see **WARNINGS—Advanced renal disease**). Long-term administration of diclofenac has resulted in renal papillary necrosis and other renal medullary changes. Patients with impaired renal function, heart failure, or liver dysfunction, those taking diuretics and ACE inhibitors, and the elderly are at greatest risk of renal decompensation. Discontinuation of NSAID therapy is usually followed by recovery to the pretreatment state. Diclofenac metabolites are eliminated primarily by the kidneys and patients with significantly impaired renal function should be more closely monitored. **Hematologic effects:** Anemia may occur; it may be due to fluid retention, GI blood loss, or an incompletely described effect upon erythropoiesis. Patients should have their hemoglobin or hematocrit checked if they exhibit signs or symptoms of anemia. ARTHROTEC may interfere to some extent with platelet function and vascular responses to bleeding. Patients with coagulation disorders or receiving anticoagulants should be carefully monitored. **Septic meningitis:** Septic meningitis with fever and coma has been observed on rare occasions in patients on diclofenac. **Fluid retention and edema:** Fluid retention and edema may occur. Use with caution in patients with a history of cardiac decompensation, hypertension, or other conditions predisposing to fluid retention. **Preexisting asthma:** Do not use in patients with aspirin-sensitive asthma because of the risk of severe fatal bronchospasm. Use with caution in patients with preexisting asthma. **Porphyria:** Use in patients with hepatic porphyria should be avoided.

Laboratory tests: Patients should have their CBC and a chemistry profile checked periodically. If clinical signs and symptoms consistent with liver or renal disease develop, systemic manifestations occur (eg, eosinophilia, rash, etc) or if abnormal liver tests persist or worsen, discontinue ARTHROTEC. **Drug interactions:** ARTHROTEC may increase the serum levels of digoxin, methotrexate, lithium and phenobarbital; patients should be monitored for toxicity. ARTHROTEC may increase cyclosporine nephrotoxicity, exacerbate GI bleeding in patients on warfarin, and inhibit the activity of antihypertensives and diuretics. Use caution in administering ARTHROTEC with any of these agents, particularly if renal function is impaired. Aspirin may diminish the therapeutic effect of diclofenac and coadministration is not recommended. Diclofenac Na may alter a diabetic patient's response to insulin or oral hypoglycemic agents. Antacids containing magnesium may exacerbate diarrhea and should not be coadministered with ARTHROTEC.

Animal toxicology: A reversible increase in the number of normal surface gastric epithelial cells occurred in the dog, rat, and mouse during long-term toxicology studies with misoprostol. An apparent response of the female mouse to misoprostol in long-term studies at 100–1000 \times the human dose was hyperostosis, mainly of the medulla of sternbrae. These effects have not been seen in human studies.

Carcinogenesis, mutagenesis, impairment of fertility: Animal studies to evaluate the potential for carcinogenesis and effects on fertility have been performed with each component of ARTHROTEC given alone. ARTHROTEC itself was not genotoxic in the Ames test, the Chinese hamster ovary cell (CHO/HGPRT) forward mutation test, the rat lymphocyte chromosome aberration test or the mouse micronucleus test. In a 24-mo rat carcinogenicity study, oral misoprostol at doses up to 24 \times the recommended maximum human dose of 0.6 mg/m²/day was not tumorigenic. In a 21-mo mouse carcinogenicity study, oral misoprostol at doses up to 80 \times the recommended maximum human dose was not tumorigenic. Misoprostol, when administered to male and female breeding rats in an oral dose-range of 1–100 \times the recommended maximum human dose produced dose-related pre- and

post-implantation losses and a significant decrease in the number of live pups born at the highest dose. These findings suggest the possibility of a general adverse effect on fertility in males and females. In a 24-mo rat carcinogenicity study, oral diclofenac Na was not tumorigenic at 0.08 \times the recommended maximum human dose of 148 mg/m²/day. In a 24-mo mouse carcinogenicity study, oral diclofenac Na at doses up to 0.006 \times the recommended maximum human dose in males and 0.02 \times the recommended maximum human dose in females was not tumorigenic. Diclofenac Na at oral doses up to 0.16 \times the recommended maximum human dose was found to have no effect on fertility and reproductive performance of male and female rats.

Pregnancy: Pregnancy category X: See boxed **CONTRAINDICATIONS AND WARNINGS** regarding misoprostol. ARTHROTEC is contraindicated in pregnancy.

Non-teratogenic effects: Misoprostol may endanger pregnancy (may cause miscarriage) and thereby cause harm to the fetus when administered to a pregnant woman. Misoprostol produces uterine contractions, uterine bleeding, and expulsion of the products of conception. Miscarriages caused by misoprostol may be incomplete. In studies in women undergoing elective termination of pregnancy during the first trimester, misoprostol caused partial or complete expulsion of the products of conception in 11% of the subjects and increased uterine bleeding in 41%. Reports, primarily from Brazil, of congenital anomalies and reports of fetal death subsequent to misuse of misoprostol alone, as an abortifacient, have been received (see **CONTRAINDICATIONS AND WARNINGS**). If a woman is or becomes pregnant while taking this drug, the drug should be discontinued and the patient apprised of the potential hazard to the fetus. The diclofenac Na component of ARTHROTEC, like other NSAIDs which are prostaglandin-inhibiting drugs, may affect the fetal cardiovascular system causing premature closure of the ductus arteriosus. NSAIDs may also inhibit uterine contractions.

Teratogenic effects: Animal tests have revealed no evidence of teratogenic potential for ARTHROTEC, misoprostol, or diclofenac.

Nursing mothers: Because of the potential for serious adverse reactions in nursing infants, ARTHROTEC is not recommended for use by nursing mothers.

Pediatric use: Safety and efficacy have not been established.

Geriatric use: In clinical trial patients >65 years of age, no overall differences were observed between efficacy, adverse events or PK profiles of older and younger patients. However, the elderly are likely to tolerate adverse events less well than younger patients.

ADVERSE REACTIONS

Adverse reactions associated with ARTHROTEC

Gastrointestinal: In clinical trials, the most frequently reported adverse events were GI disorders: abdominal pain (21%), diarrhea (19%), dyspepsia (14%), nausea (11%), and flatulence (9%). ARTHROTEC can cause more GI symptoms than diclofenac alone. These events led to discontinuation of therapy in 9% of patients. Diarrhea and abdominal pain developed early in the course of therapy, and were usually self-limited (resolved after 2 to 7 days). Rare instances of profound diarrhea leading to severe dehydration have been reported in patients receiving misoprostol. Patients with an underlying condition such as inflammatory bowel disease, or those in whom dehydration, were it to occur, would be dangerous, should be monitored carefully. The incidence of diarrhea can be minimized by administering ARTHROTEC with food and by avoiding coadministration with magnesium-containing antacids.

Gynecological: Postmenopausal vaginal bleeding may occur (see below) and should be evaluated to rule out gynecologic pathology.

Other: Adverse experiences reported occasionally or rarely with ARTHROTEC, diclofenac or other NSAIDs, or misoprostol are: **Body as a whole:** Asthenia, death, fatigue, fever, infection, malaise, sepsis. **Cardiovascular system:** Arrhythmia, atrial fibrillation, CHF, hypertension, hypotension, increased CPK and/or LDH, MI, palpitations, pleuritis, PVCs, syncope, tachycardia, vasculitis. **Central and peripheral nervous system:** Coma, convulsions, diplopia, drowsiness, hyperesthesia, hyperreflexia, hypoaesthesia, meningitis, migraine, neuralgia, paresthesia, tremor, vertigo. **Digestive:** Anorexia, dry mouth, dysphagia, enteritis, esophageal ulceration, gastroesophageal reflux, GI bleeding, GI neoplasm benign, glossitis, hematemesis, hemorrhoids, intestinal perforation, peptic ulcer, stomatitis and ulcerative stomatitis, tenesmus. **Female reproductive disorders:** Breast pain, dysmenorrhea, intermenstrual bleeding, leukorrhea, menstrual disorder, menorrhagia, vaginal hemorrhage. **Hemic and lymphatic system:** Agranulocytosis, aplastic anemia, coagulation time increased, ecchymosis, eosinophilia, epistaxis, hemolytic anemia, leukocytosis, leukopenia, lymphadenopathy, melena, pulmonary embolism, purpura, pancytopenia, rectal bleeding, thrombocytopenia, thrombocytopenia. **Hypersensitivity:** Angioedema, laryngopharyngeal edema, urticaria. **Liver and biliary system:** Abnormal hepatic function, hepatitis, jaundice, liver failure, pancreatitis. **Male reproductive disorders:** Impotence, perineal pain. **Metabolic and nutritional:** Alkaline phosphatase increased, dehydration, hyponatremia, hyperglycemia, hypoglycemia, BUN increased, hyperuricemia, periorbital edema, porphyria, gout, hypercholesterolemia, weight changes. **Musculoskeletal system:** Arthralgia, myalgia. **Psychiatric:** Anxiety, asthenia, concentration impaired, confusion, depression, disorientation, dream abnormalities, hallucinations, irritability, malaise, nervousness, paranoia, psychotic reaction, somnolence. **Respiratory system:** Asthma, coughing, dyspnea, hyperventilation, pneumonia, respiratory depression. **Skin and appendages:** Acne, alopecia, erythema multiforme, eczema, exfoliative dermatitis, pemphigoid reaction, photosensitivity, pruritus ani, skin ulceration, Stevens-Johnson syndrome, sweating increased, toxic epidermal necrolysis. **Special senses:** Hearing impairment, taste loss, taste perversion. **Urinary system:** Cystitis, dysuria, hematuria, interstitial nephritis, micturition frequency, nocturia, nephrotic syndrome, oliguria/polyuria, papillary necrosis, proteinuria, renal failure, urinary tract infection. **Vision:** Amblyopia, blurred vision, conjunctivitis, glaucoma, iritis, lacrimation abnormal, night blindness, vision abnormal.

OVERDOSAGE

The toxic dose of ARTHROTEC has not been determined. However, signs of overdosage from the components of the product may include: diclofenac—GI complaints, confusion, drowsiness or general hypotonia; misoprostol—sedation, tremor, convulsions, dyspnea, abdominal pain, diarrhea, fever, palpitations, hypotension, or bradycardia. Overdosage symptoms should be treated with supportive therapy. In case of acute overdosage, gastric lavage is recommended. Induced diuresis may be beneficial. The use of oral activated charcoal may help to reduce absorption.

DOSEAGE AND ADMINISTRATION

ARTHROTEC is administered as ARTHROTEC 50 (50 mg diclofenac Na/200 mcg misoprostol) or as ARTHROTEC 75 (75 mg diclofenac Na/200 mcg misoprostol). **OA:** The recommended dosage for maximal GI mucosal protection is ARTHROTEC 50 bid. **RA:** The recommended dosage is ARTHROTEC 50 tid or qid. For OA and RA patients who experience intolerance, ARTHROTEC 75 bid or ARTHROTEC 50 bid can be used, but are less effective in preventing ulcers. ARTHROTEC fixed dose combination is not appropriate for patients who would not receive the appropriate dose of both ingredients. Doses of the components delivered with these regimens are as follows:

	RA regimen	OA regimen	Diclofenac Na (mg/day)	Misoprostol (mcg/day)
ARTHROTEC 50	qid	—	200	800
	tid	tid	150	600
	bid	bid	100	400
ARTHROTEC 75	bid	bid	150	400

SPECIAL DOSING CONSIDERATIONS: ARTHROTEC contains misoprostol, which provides protection against gastric and duodenal ulcers. For gastric ulcer prevention, the 200 mcg qid and tid regimens are severally equivalent, but more protective than the bid regimen. For duodenal ulcer prevention, the qid regimen is more protective than the tid or bid regimens. However, the qid regimen is less well tolerated than the tid regimen because of usually self-limited diarrhea related to the misoprostol dose (see **ADVERSE REACTIONS—Gastrointestinal**), and the bid regimen may be better tolerated than tid in some patients. Dosages may be individualized using the separate products (misoprostol and diclofenac), after which the patient may be changed to the appropriate ARTHROTEC dose. If clinically indicated, misoprostol co-therapy with ARTHROTEC, or use of the individual components to optimize the misoprostol dose and/or frequency of administration, may be appropriate. The total dose of misoprostol should not exceed 800 mcg/day, and no more than 200 mcg of misoprostol should be administered at any one time. Doses of diclofenac higher than 150 mg/day in OA or higher than 225 mg/day in RA are not recommended.

12/30/97 ~ P97AR13195V

Packaged by G.D. Searle & Co.
Mfd. by Searle, Morphot, England
For G.D. Searle Inter-American Co.
Chicago IL 60680 USA

Address medical inquiries to:
G.D. Searle & Co.
Healthcare Information Services
5200 Old Orchard Road
Skokie IL 60077

SEARLE

© 1999 Searle, Box 5110, Chicago, IL 60680-5110
December 1999 • AR18564T • Printed in USA

Printed in USA