REVIEW

ALEJANDRO C. ARROLIGA, MD
Director, Medical Intensive Care Unit, Department of Pulmonary and Critical Care Medicine, Cleveland Clinic

RAED A. DWEIK, MD
Department of Pulmonary and Critical Care Medicine, Cleveland Clinic

F. J. TAKAO KANEKO, MD
Department of Critical Care Medicine, Central Military Hospital, Mexico City, Mexico

SERPIL C. ERZURUM, MD
Department of Pulmonary and Critical Care Medicine, Cleveland Clinic

Primary pulmonary hypertension: Update on pathogenesis and novel therapies

ABSTRACT

Primary pulmonary hypertension is a progressive and fatal disease that chiefly affects young adults. Although its etiology is a mystery, recent research has uncovered several biochemical derangements in this disorder, and new therapies are prolonging survival.

KEY POINTS

Because the initial symptoms (dyspnea, fatigue, and chest pain) are nonspecific, patients usually face a delay in diagnosis.

All patients with primary pulmonary hypertension should undergo a trial of a calcium channel blocker with hemodynamic monitoring. If this produces a response, the drug can be continued long-term.

If a calcium channel blocker fails, then epoprostenol is the second-line therapy. Lung transplantation is the treatment of last resort.

THE MEDICAL AND SURGICAL THERAPIES for primary pulmonary hypertension (PPH) have advanced greatly in the last decade. Calcium channel blockers have improved patients' chances of survival, and epoprostenol, a potent vasodilator, is an alternative should calcium channel blocker therapy fail.

In addition, recent advances in our understanding of PPH's pathogenesis are providing clues to possible new treatments.

Still, for all of our expanding knowledge about PPH, the condition is often misdiagnosed in its early stages as asthma, hyperventilation, or depression. This paper reviews the diagnosis of PPH, and outlines recent findings in pathogenesis and treatment.

EPIDEMIOLOGY

PPH, also known as unexplained or idiopathic pulmonary hypertension, is a disease or group of diseases characterized by pulmonary hypertension in the absence of a known cause.[1] (Pulmonary hypertension is defined by a mean pulmonary arterial pressure greater than 25 mm Hg at rest and 30 mm Hg during exercise and by elevated pulmonary vascular resistance.[1,2])

PPH is rare, with an estimated incidence of 1 to 2 cases per million people in the general population. However, the disease can cluster in families. Six percent of the patients in a national PPH registry had family members with PPH. Further, Elliott et al[3] found two patients out of a cohort of 13 who, although unknown to one another, actually shared com-

Downloaded from www.ccjm.org on June 5, 2025. For personal use only. All other uses require permission.

Progress in unraveling the pathogenesis of primary pulmonary hypertension

THE PATHOGENESIS of PPH is unclear, but at least three processes contribute to narrowing the vascular lumen and obliterating small and medium-sized vessels in the lungs: vasoconstriction, vascular wall remodeling (medial hypertrophy), and thrombosis in situ. It is unclear if these abnormalities are causes or results of the disease. However, in the future, we hope to improve the prognosis of PPH by targeting these abnormalities.

VASOCONSTRICTION

Circumstantial evidence suggests that an imbalance between vasoconstrictors and vasodilators plays a role in the pathogenesis of PPH. The following abnormalities have been identified:

High levels of plasma endothelin-1 (a powerful vasoconstrictor likely produced by the lungs)[37,38]

Increased release of thromboxane A_2 (a vasoconstrictor)

Impaired release of prostacyclin (a vasodilator)[39]

Decreased levels of nitric oxide (NO) in the lung. NO is a powerful vasodilator, but has a number of other effects.[40–43] In particular, it inhibits proliferation of vascular smooth muscle by altering gene expression of several growth factors such as vascular endothelial growth factor[44] and platelet-derived growth factor. Therefore, a deficiency of NO may not only favor vasoconstriction but also facilitate proliferation of vascular cells and remodeling of the pulmonary arteries.

Recently, we performed fiberoptic bronchoscopy in patients with PPH to measure intrabronchial levels of NO and its reaction products,[45] and found that these levels are lower in patients with PPH than in healthy persons. Interestingly, the lower the level of NO products, the higher the pulmonary arterial pressure (FIGURE 1).

VASCULAR REMODELING

Vascular remodeling also plays an important role in the pathogenesis of PPH (FIGURE 2).[46] Smooth muscle proliferation can be mediated by the same mediators that influence vascular tone such as endothelin-1, angiotensin-converting enzyme,[47] serotonin,[48] and, as mentioned above, NO.[45]

THROMBOSIS IN SITU

Thrombosis in situ is common in pulmonary hypertension of different etiologies and may play a role in the narrowing of the pulmonary arteries of patients with PPH.[30,49] Thrombosis may result from abnormalities of fibrinolysis, abnormal platelet function, and increased procoagulant activity.[49] Low levels of thrombomodulin, found in some patients with PPH, may help trigger or worsen the thrombosis.[50]

CONSEQUENCES OF PULMONARY HYPERTENSION

Narrowing of the small arteries increases the pulmonary vascular resistance. The right ventricle, a thin-walled, distendible chamber, is not well prepared to handle high pressures, and with time it dilates in response to the overload. Eventually, it becomes ischemic because of decreased blood flow due to high end-systolic and end-diastolic pressures. Cardiac output is decreased only during exercise early in the disease, but eventually drops even at rest. Subsequently, right ventricular failure ensues.

In general, the pulmonary artery occlusion ("wedge") pressures are normal, except late in the disease when left ventricular diastolic dysfunction occurs. Diastolic dysfunction of the left ventricle is probably caused by alteration in the geometry of the left ventricle, due to displacement of the interventricular septum.

The most common cause of death in patients with PPH is progressive right ventricular failure followed by sudden death.

mon ancestors, suggesting that familial PPH may be more common than previously recognized. The familial disease is inherited as an autosomal dominant disorder with reduced penetrance, ie, a person needs to inherit only one abnormal allele to acquire the disease, but not everyone with an abnormal allele actually develops PPH. Initial evidence suggests that the gene is located on the long arm of chromosome 2. In some familial cases the disease

Downloaded from www.ccjm.org on June 5, 2025. For personal use only. All other uses require permission.

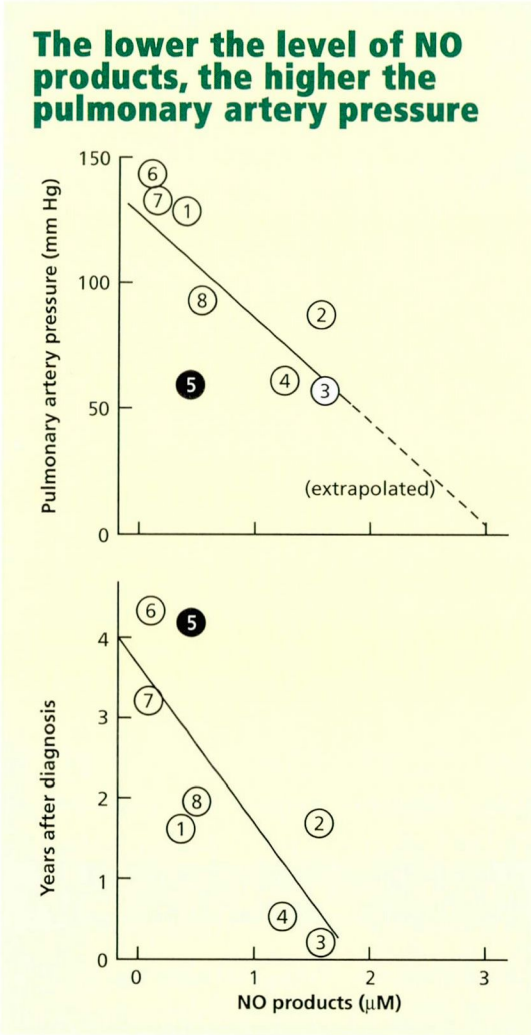

FIGURE 1. Relationship of reaction products of nitric oxide (NO) in bronchoalveolar lavage fluid to pulmonary artery pressures **(top)** and years after diagnosis of PPH **(bottom)**. The circles represent individual patients. The filled circle represents a patient with familial PPH who died during the study.

FROM KANEKO ET AL, REFERENCE 45

increases in severity and the mean age at death decreases in successive generations, a phenomenon known as genetic anticipation.[4,5]

PPH predominantly afflicts young adults, but it can occur at any age. The mean age of patients in the national PPH registry in the early 1980s was 36 ± 15 years. It is 1.7 times more common in women than in men, although in African-Americans the female-to-male predominance is as high as 4.3:1.[2]

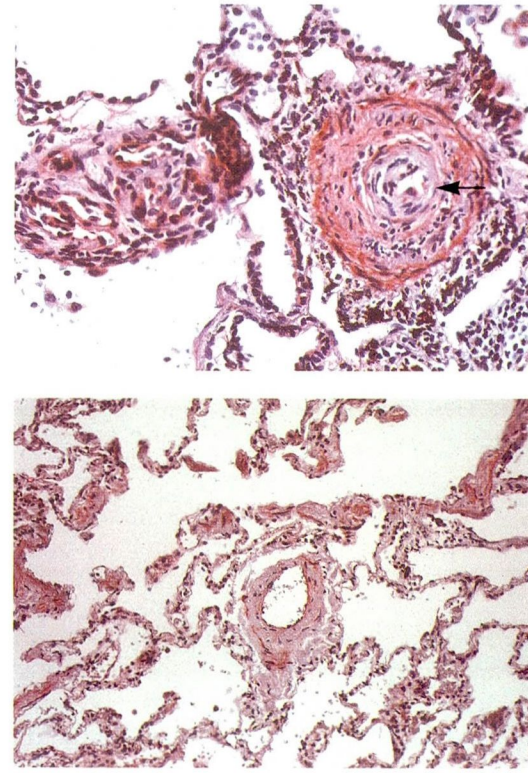

FIGURE 2. Top, histopathologic photograph of the lung of a patient with PPH. The lung parenchyma is normal. Note obliteration of the vascular lumen (black arrow) and significant medial hypertrophy (white arrow). **Bottom**, normal lung tissue.

PHOTOS COURTESY OF CAROL F. FARVER, MD

Without treatment, the median survival is 2.8 years

PROGNOSIS

PPH progresses and is often fatal if it is not diagnosed and treated.[2,6] The median survival time without adequate treatment is 2.8 years after diagnosis, and the 5-year survival rate is 34%.[6]

The factors that correlate best with mortality are an elevated pulmonary artery pressure, an elevated right atrial pressure, and a decreased cardiac index. D'Alonzo et al[6] developed a regression equation that uses these three variables to estimate a patient's chances of survival (TABLE 1). By this equation, these researchers estimated that a patient with a mean pulmonary artery pressure of 40 mm Hg, a mean right atrial pressure of 3.5 mm Hg, and a cardiac index of 3.3 L/minute/m^2—moderately abnormal values—would have an 85% chance of surviving 1 year, a 78% chance of surviving 2 years, and a 72% chance of surviv-

Downloaded from www.ccjm.org on June 5, 2025. For personal use only. All other uses require permission.

TABLE 1

Predicting survival in patients with primary pulmonary hypertension

$$P(t) = [H(t)]^{A(x,y,z)}$$

Where:

$P(t)$ = the patient's chance of survival at time (t) = 1, 2, or 3 years after diagnosis

$H(t) = 0.88 - 0.14t + 0.01t^2$

$A(x,y,z) = e^{(0.007325x + 0.05264y - 0.3275z)}$

X = mean pulmonary artery pressure, in mm Hg

Y = mean right atrial pressure, in mm Hg

Z = cardiac index, in L/minute/m^2

FROM D'ALONZO GE, BARST RJ, AYRES SM, ET AL. SURVIVAL IN PATIENTS WITH PRIMARY PULMONARY HYPERTENSION. RESULTS FROM A NATIONAL PROSPECTIVE STUDY ANN INTERN MED 1991; 115:343–349.

ing 3 years. Others have confirmed the validity of this formula,[7] and it can estimate survival in candidates for lung transplantation.

Other clinical factors that influence survival include age, functional class, and response to therapy. The very young (< 14 years) and the old (> 65 years) tend to do poorly. The survival of patients in New York Heart Association System Class III is 32 months, and in Class IV is only 6 months.[4]

Physical findings in PPH are similar to those for pulmonary hypertension from other causes

CLINICAL PRESENTATION

Symptoms

The initial symptoms are nonspecific, and therefore there is usually a significant delay between the onset of symptoms and the diagnosis of PPH: the mean interval is 2 years.[1] Often, patients are misdiagnosed as having hyperventilation, depression, or asthma.

Dyspnea, the most common initial symptom, is present in 60% of patients at presentation and in 100% at the time of diagnosis.

Chest pain, probably due to underperfusion of the right ventricle or stretching of the large pulmonary arteries, is present in almost half of patients.

Fatigue is the initial symptom in approximately 19% of patients and is present at the time of diagnosis in 75%.

Syncope or near-syncope is present in almost 40% of patients; it is associated with a poor prognosis.

Raynaud phenomenon is present in 10% of patients, almost all of them women; it also carries a poor prognosis.[2]

Other symptoms include cough, hemoptysis, and hoarseness. Hoarseness is due to compression of the recurrent laryngeal nerve by the enlarged pulmonary artery.

Physical findings

The physical findings in patients with PPH are similar to those in patients with other causes of pulmonary hypertension.

Abnormal heart sounds. A loud second heart sound is present in 93% of patients, a right-sided third heart sound in 23%, and a right-sided fourth heart sound in 38%. Other signs include systolic murmurs indicative of tricuspid regurgitation and diastolic murmurs caused by pulmonary valve insufficiency. A right-sided third heart sound, tricuspid regurgitation, and pulmonic insufficiency are associated with significant pulmonary hypertension and a low cardiac output.[2]

Peripheral edema is present in a third of patients.

Cyanosis, a late sign, is present in 20%.

Bibasilar rales may be present in patients with pulmonary veno-occlusive disease, but the lung exam is usually unremarkable.

Findings *not* associated with PPH

Two physical findings suggest a diagnosis other than PPH:

Clubbing suggests a cardiac abnormality.[8]

Pulmonary bruits are generally associated with chronic thromboembolic disease and occasionally with pulmonary arteriovenous malformation.[9]

DIAGNOSTIC STRATEGY

Because the early symptoms of PPH are nonspecific, the diagnosis is often difficult. The diagnostic evaluation consists of three parts:

- First, pulmonary hypertension needs to be suspected and confirmed. Pulmonary hypertension should be suspected in patients with dyspnea, near-syncope, or a loud second heart sound. If the clinical history and physical exam do not suggest a specific etiology, the patient should undergo a workup that includes the diagnostic tests listed below.

Downloaded from www.ccjm.org on June 5, 2025. For personal use only. All other uses require permission.

TABLE 2

Possible causes of pulmonary hypertension

Cardiac
- Left heart valvular diseases
- Cardiomyopathy
- Ischemic disease

Pulmonary
- Obstructive
- Restrictive
  - Interstitial disease
  - Extrapulmonary diseases
- Parasitic
  - Schistosomiasis
- Vascular
  - Vasculitis
  - Stenosis
  - Chronic thromboembolic disease
  - Sickle cell disease
  - Myeloproliferative disorders

Sleep disorders
- Obstructive
- Central

Other
- Gaucher disease
- Connective tissue diseases

- Next, the severity must be assessed.
- Finally, other causes of pulmonary hypertension must be excluded (TABLE 2).

DIAGNOSTIC TESTS

The chest radiograph is frequently abnormal, although it is normal in 6% of patients with PPH. Abnormal findings include enlargement of the main pulmonary arteries with "pruning" of the peripheral vessels (FIGURE 3). Pleural effusions do not occur in right-sided heart failure. In patients with veno-occlusive disease, Kerley B-lines are present, and radiographic evidence of pulmonary edema may appear when such patients are treated with a vasodilator.

Computed tomography (CT), especially using the high-resolution technique, can be helpful in selected cases in which interstitial lung diseases are suspected.

The electrocardiogram is frequently abnormal. Right axis deviation, ventricular hypertrophy, and strain are present in 75% to almost 90% of patients. Cardiac arrhythmias are infrequent, but when present, carry a poor prognosis.[2]

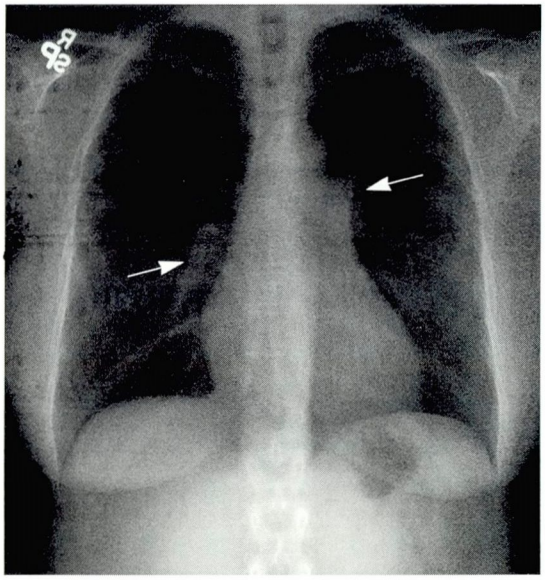

FIGURE 3. A 45-year-old woman with PPH. Note the normal lung parenchyma, cardiomegaly, and enlargement of pulmonary arteries (arrows).

Transthoracic echocardiography is helpful in patients with severe pulmonary hypertension. It confirms the diagnosis of pulmonary hypertension and—of importance—it is helpful in ruling out congenital, valvular, and myocardial disease.[1] In patients with PPH the echocardiogram frequently shows a dilated and hypertrophic right ventricle. Examination of the tricuspid valve usually reveals regurgitation.

Doppler echocardiography can be used to calculate the right ventricular peak systolic pressure. Values obtained by echocardiography correlate with values obtained by catheterization, but echocardiography tends to underestimate the pulmonary artery pressure in up to 31% of patients.[10]

Other echocardiographic abnormalities, seen in severe pulmonary hypertension, include paradoxical septal motion (59% of patients), partial systolic closure of the pulmonary valve (60% of patients), and pericardial effusion, probably caused by the decreased lymphatic drainage due to the high pressures of the right atrium.

Main pulmonary arteries are enlarged and peripheral vessels appear "pruned"

Downloaded from www.ccjm.org on June 5, 2025. For personal use only. All other uses require permission.

On occasion, transesophageal echocardiography may be used to reveal additional information (proximal pulmonary artery thrombi, atrial septal defect, and anomalous drainage of pulmonary veins) in patients being considered for lung transplantation.[11]

Pulmonary function tests are useful to exclude significant obstructive or restrictive thoracic diseases. The forced vital capacity is usually normal (the mean value in the national registry was 82% of predicted). The diffusing capacity for carbon monoxide is moderately reduced. However, a low diffusion capacity for carbon monoxide in a patient with normal lung mechanics should suggest a pulmonary vascular disease as a cause of the symptoms. Hypoxemia and hypocapnia are common. Our

Segmental perfusion defects suggest chronic thrombo-embolism

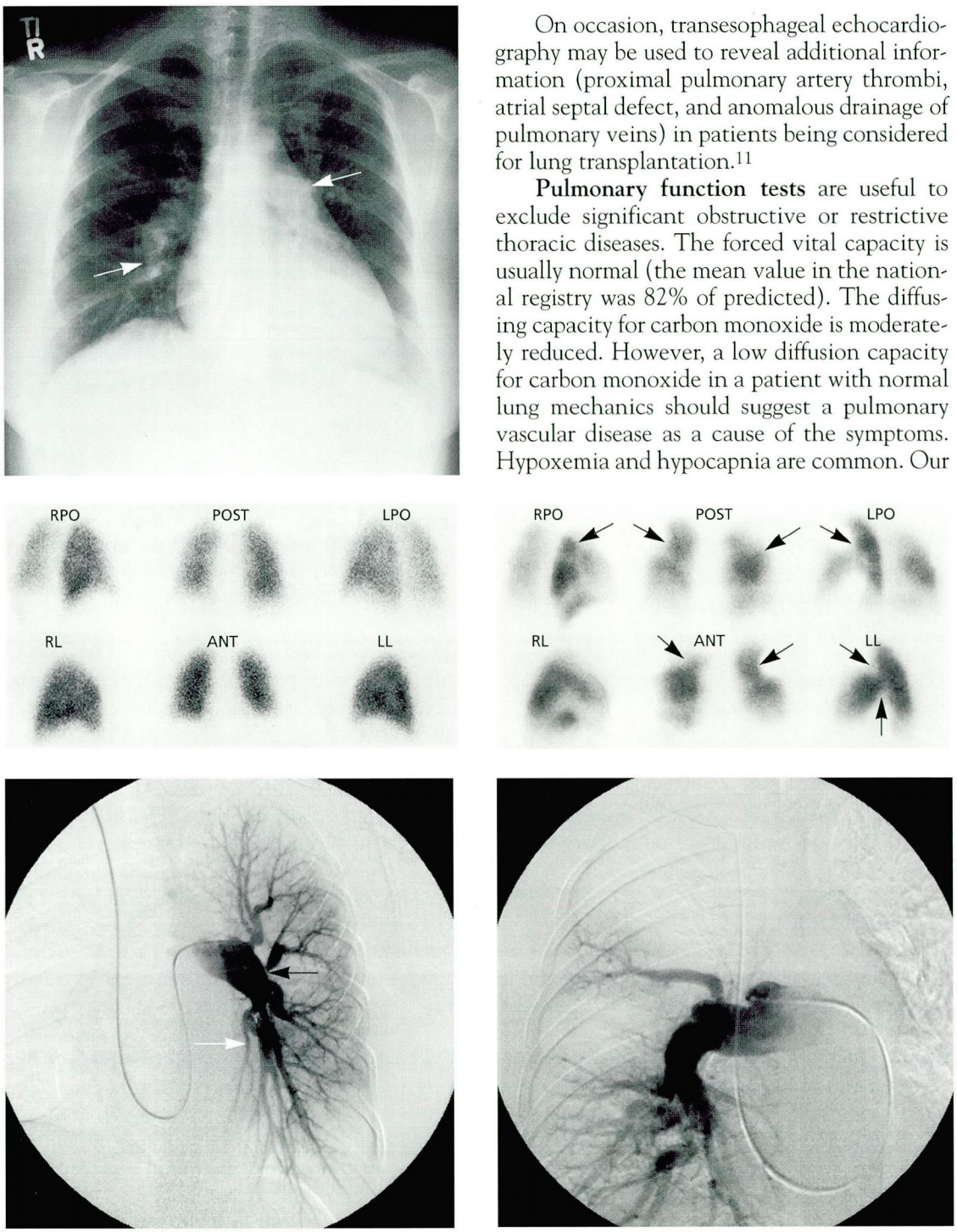

FIGURE 4. Radiographic studies of a patient with pulmonary hypertension due to chronic thromboembolic disease. **Top,** frontal chest radiograph shows enlargement of the pulmonary arteries (arrows) and cardiomegaly. **Middle,** the ventilation/perfusion scan shows segmental perfusion defects (arrows) and normal ventilation. **Bottom,** a pulmonary angiogram shows evidence of chronic thromboembolism with intimal irregularities (white arrow) and vascular narrowing (black arrow).

Downloaded from www.ccjm.org on June 5, 2025. For personal use only. All other uses require permission.

TABLE 3

Some vasodilators used in primary pulmonary hypertension

Past
Hydralazine
Prazosin
Nitroglycerin
Currently in use
Calcium channel blockers
Epoprostenol (prostacyclin, prostaglandin I_2)
Nitric oxide
Acute responsiveness
Epoprostenol
Adenosine
Nitric oxide
Future
Oral prostacyclin analog
Endothelin 1 blockers
Dipyridamole

group and others have shown that some patients with PPH may have reversible airway obstruction.[12,13]

Lung biopsy is not essential for the diagnosis of PPH

The 6-minute walk test, in which the distance walked and oxygen saturation are measured, is a simple, noninvasive way to assess exercise endurance and quantitate the response to therapy in patients with PPH.[1] In contrast, cardiopulmonary exercise testing is uncommonly done in patients with PPH.

The ventilation/perfusion (V/Q) lung scan is one of the most important noninvasive tests done in patients with PPH because it helps to rule out chronic thromboembolic pulmonary hypertension, which mimics PPH clinically but requires surgery (thromboendarterectomy). In patients with PPH, the V/Q scan is either normal or shows "salt-and-pepper" patchy perfusion defects. Bigger segmental or subsegmental defects suggest chronic thromboembolic disease (FIGURE 4).

Pulmonary angiography is indicated in patients in whom a V/Q scan suggests chronic thromboembolic disease (see above). It is safe in patients with severe pulmonary hypertension[9]; the chances of complication are 3% to 6%.[2,14] Other noninvasive radiologic tests, such as magnetic resonance imaging and spiral computed tomography of the chest, although promising, still do not substitute for a pulmonary angiogram.

Laboratory examinations are useful to rule out diseases that may have pulmonary hypertension as part of their presentation, such as systemic lupus erythematosus, scleroderma, and mixed connective tissue disease. However, serum antinuclear antibodies, frequently present in connective tissue diseases, may be found in 29% to 40% of patients with PPH.[15]

Biopsy of the lung is not essential for the diagnosis of PPH. Because the involvement of the vascular bed is patchy in PPH, the biopsy does not always correlate with the degree of pulmonary hypertension, clinical findings, or the response to medical therapy. In the few cases in which lung biopsies are indicated, the thoracoscopic approach is preferred; bronchoscopic biopsy is not recommended in patients with PPH.

Right heart catheterization is necessary to determine the degree of hemodynamic impairment and the prognosis of patients with PPH.[6] At the same time, it excludes cardiac abnormalities that occasionally go undiagnosed (eg, atrial or ventricular septal defects). Finally, it is useful at the start of vasodilator therapy by revealing whether the pulmonary hypertension will respond to the drug, and at what dose. Right heart catheterization is safe in patients with PPH, although transient hypotension and hemoptysis occur in 4% to 5% of cases.

THERAPY

The treatment of PPH has changed in the last decade: calcium channel blockers and epoprostenol have replaced the older vasodilators (TABLE 3). As a result, for the first time, treatment has started to improve patients' chances of survival. If vasodilator therapy fails, many medical centers offer single or bilateral lung transplantation.[16]

Calcium channel blockers

Of the current oral vasodilators, calcium channel blockers in high doses are preferred.

Starting therapy. A trial of a calcium

Downloaded from www.ccjm.org on June 5, 2025. For personal use only. All other uses require permission.

channel blocker, usually with nifedipine or diltiazem, should be attempted, but only under close supervision by an experienced team with strict hemodynamic monitoring in an intensive care unit.

After a right heart catheter is inserted, doses of the calcium channel blocker (nifedipine 20 mg or diltiazem if the patient is tachycardic) are given every hour until the mean pulmonary artery pressure decreases.[17] A positive response is considered a reduction of the mean pulmonary arterial pressure and pulmonary vascular resistance by at least 20% accompanied by a rise in the cardiac output without a drop in the systemic blood pressure.[17]

Of patients who respond to a calcium channel blocker, 94% can be expected to survive 5 years, compared with 55% of patients who do not respond to the vasodilator, or 34% of historical controls. Unfortunately, only 25% of patients have a positive response to calcium channel blockers.

The current recommendation is to continue giving the medication only to those patients with a positive vasodilatory response. Some patients who initially respond to calcium channel blockers may deteriorate over time, and in those patients epoprostenol should be tried or surgical therapy offered.

Other vasodilators that have been used to assess the vasodilator reserve in patients with PPH include adenosine,[18] nitric oxide, and prostacyclin.[19] Response to inhaled nitric oxide can predict a vasodilator response to nifedipine.[19] Inhaled nitric oxide has been used by the pulse delivery route in a small group of patients with PPH.[20]

Side effects of calcium channel blockers include systemic hypotension, worsening of right ventricular function, hypoxemia, worsening of leg edema, and arrhythmias.

Epoprostenol

In patients who do not respond to calcium channel blockers, epoprostenol (prostacyclin or prostaglandin I_2), a potent endogenous vasodilator and inhibitor of platelet aggregation, is available for continuous infusion.

Prostacyclin, discovered more than 2 decades ago by Moncada et al,[21] is most actively produced by endothelial cells.[22] Prostacyclin relaxes the vascular smooth muscle cells, inhibits platelet aggregation, and disperses aggregates, but inhibits cell migration, proliferation, and production and secretion of endothelin-1.

Epoprostenol first was used to test the vasodilatory capabilities of the pulmonary vasculature in acute settings. It has been in use in Europe since the early 1980s,[23] and is available for continuous infusion in the United States more recently.

When epoprostenol was compared with conventional therapy (oral vasodilators, anticoagulation, diuretics, cardiac glycosides, and supplemental oxygen) in a group of patients with severe PPH over a 12-week period, the group receiving epoprostenol had symptomatic and hemodynamic improvement and a better survival.[24,25] Long-term therapy with epoprostenol improves the functional class and the duration of exercise. A decline in the pulmonary vascular resistance and mean pulmonary arterial pressure and improvement in the cardiac output were noted.[26] Importantly, patients with a marginal response to acute vasodilatory challenges showed significant and sustained improvement of the pulmonary vascular resistance over time. When epoprostenol is started in a patient with PPH, the treatment is long-term, usually until transplantation.

Calcium channel blockers and epoprostenol have replaced older vasodilators

Epoprostenol is given by continuous infusion. The usual initial dosage of epoprostenol is 4 to 7 ng/kg/minute. Tachyphylaxis is common, and the dose is slowly increased over time. Continuous education of the patient about the drug, side effects, and complications is necessary. Significant side effects include diarrhea, jaw pain, headaches, and flushing.[26] Problems with the delivery system were reported initially, but lately in our experience have not been a problem. Local infections are common, and bacteremia and sepsis occur. Other routes have been tried with prostacyclin or analogs, including aerosolized,[27] subcutaneous, and oral.[28,29]

Other medical therapy

Supplemental oxygen is provided to keep oxygen saturation above 90%. It is reasonable to assess oxygen saturation with exercise and at night.

Downloaded from www.ccjm.org on June 5, 2025. For personal use only. All other uses require permission.

Diuretics should be used cautiously to avoid intravascular volume depletion, which can decrease the cardiac output. Electrolytes and renal function are followed closely.

Digoxin can be used cautiously in some patients.

Systemic anticoagulation increases the survival of patients with PPH,[17,30,31] even in patients who do not respond to calcium channel blockers. We recommend anticoagulation with warfarin early after the diagnosis of PPH is made in the absence of contraindications,[17,31] and maintain the international normalized ratio around 2.

Patient education

Patient education should be part of the program. Patients should understand that mild aerobic exercise, ie, walking, is encouraged as tolerated. However, they should avoid exercise that includes performing the Valsalva maneuver (eg, weight-lifting) because it can decrease the cardiac output, with potentially bad consequences. Pregnancy should be avoided because patients with pulmonary hypertension generally have a poor outcome.[32] Because most patients with PPH receive warfarin, they must be educated about drug interactions that can alter the prothrombin time. Finally, the patient should be aware of medications that prolong the QT interval and cause cardiac arrhythmias.

Surgical therapy

Surgical therapy for patients with PPH includes atrial septostomy and lung transplantation.

Atrial septostomy consists of creation of a hole in the atrial septum by means of graded balloon dilatation. A report by Sandoval et al[33] suggests this procedure is a safe and useful palliative treatment for selected patients with PPH. Others have reported similar results.[34] More experience is needed with this technique before further recommendations are made.

Lung transplantation, single or bilateral, is an option for patients with PPH. The time from listing to transplantation varies between 1 and 2 years, according to the center.[35] Before being enrolled in a transplant program, the patient should be evaluated for vasodilator therapy and should have progressive disease with advanced New York Heart Association classification of III or IV despite optimal treatment.[36] The postoperative survival rate is 40% to 45% at 5 years. The mortality rate following lung transplantation for PPH is higher than for other indications.[35] It is unclear whether lung transplantation or long-term epoprostenol is the preferred therapy. Recent data show that up to 70% of patients accepted for lung transplantation who were placed on epoprostenol were removed from the transplant list or had listing deferred because of significant clinical improvement.[35]

Cost of therapy

The cost of therapy is substantial. Epoprostenol costs at least $50,000 to $60,000 per year, and often substantially more for the many patients who need frequent dosage increases.[35] The average cost of lung transplantation is high as well: $164,989 in the short term, with a projected lifetime cost of $424,853. No long-term data are yet available about quality of life in patients receiving epoprostenol, although clinical experience suggests the drug improves quality of life significantly. Lung transplantation improves the quality of life in the vast majority of patients.[35]

Epoprostenol therapy costs $50,000 to $60,000 per year

RECOMMENDATIONS

Currently, we try a calcium channel blocker in every patient with PPH. If this does not produce a response, we start epoprostenol. The patient is followed every 2 months on an outpatient basis with a 6-minute walk and clinical exam. A repeat cardiac catheterization is performed at 6 months, especially in patients who did not improve clinically. If the patient deteriorates clinically or has worsening hemodynamic measurements, we encourage him or her to undergo lung transplantation. However, several patients have chosen to continue epoprostenol treatment.

REFERENCES

1. **Rubin LJ.** Primary pulmonary hypertension. N Engl J Med 1998; 336:111–117.
2. **Rich S, Dantzker DR, Ayres SM, et al.** Primary pulmonary hypertension. A national prospective study. Ann Intern Med 1987; 107:216–223.
3. **Elliott G, Alexander G, Leppert M. Yeates S, Kerber R.** Coancestry in apparently sporadic primary pulmonary hypertension. Chest 1995; 108:973–977.
4. **Nichols WC, Koller DL, Slovis B, et al.** Localization of the gene for familial primary pulmonary hypertension to chromosome 2q31-32.

Downloaded from www.ccjm.org on June 5, 2025. For personal use only. All other uses require permission.

Nature Genetics 1997; 15:277–280.
5. **Morse JH, Jones AC, Barst RJ, Hodge SE, Wilhelmsen KC, Nygaard TG.** Mapping of familial primary pulmonary hypertension locus (PPH1) to chromosome 2q31-q32. Circulation 1997; 2603–2606.
6. **D'Alonzo GE, Barst RJ, Ayres SM, et al.** Survival in patients with primary pulmonary hypertension. Results from a national prospective study. Ann Intern Med 1991; 115:343–349.
7. **Sandoval J, Bauerle O, Gomez A, Palomar A, Martinez Guerra ML, Furuya ME.** Primary pulmonary hypertension in children: Clinical characterization and survival. J Am Coll Cardiol 1995; 25:466–474.
8. **Olivari Maria-Teresa.** Primary pulmonary hypertension. Am J Med Sci 1991; 302:185–198.
9. **Moser KM, Auger WR, Fedullo PF, Jamieson SW.** Chronic thromboembolic pulmonary hypertension. Clinical picture and surgical treatment. Eur Respir J 1992; 5:334–342.
10. **Hinderliter AL, Willis PW, Barst RJ, et al.** Effects of long-term infusion of prostacyclin (Epoprostenol) on echocardiographic measures of right ventricular structure and function in primary pulmonary hypertension. Circulation 1997; 1479–1486.
11. **Gorcsan J III, Edwards TD, Ziady GM, Katz WE, Griffith BP.** Transesophageal echocardiography to evaluate patients with severe pulmonary hypertension for lung transplantation. Ann Thorac Surg 1995; 59:717–722.
12. **Fernandez-Bonetti P, Lupi- Herrera E, Martinez-Guerra ML, Barrios R, Seoane M, Sandoval J.** Peripheral airways obstruction in idiopathic pulmonary artery hypertension (primary). Chest 1983; 83:732–738.
13. **O'Hagan AR, Stillwell PC, Arroliga AC.** Airway responsiveness to inhaled albuterol in patients with pulmonary hypertension. Clin Pediatric 1999; 38:27–33.
14. **Robalino BD, Moodie DS.** Primary pulmonary hypertension, then and now: 28 years of experience. Cleve Clin J Med 1992; 59:411–417.
15. **Isern RA, Yaneva M, Weiner E, et al.** Autoantibodies in patients with primary pulmonary hypertension: Association with anti-Ku. Am J Med 1992; 93:307–312.
16. **Natens M, Freels S, Kaufmann E, Yvy PS, Rich S.** Timing of single lung transplantation for primary pulmonary hypertension. J Heart Lung Transplant 1994; 13:276–281.
17. **Rich S, Kaufman E, Levy PS.** The effect of high doses of calcium-channel blockers on survival in primary pulmonary hypertension. N Engl J Med 1992; 327:76–81.
18. **Schrader BJ, Inbar S, Kaufman L, Vestal RE, Rich S.** Comparison of the effects of adenosine and nifedipine in pulmonary hypertension. J Am Coll Cardiol 1992; 19:1060–1064.
19. **Jolliet P, Bulpa P, Thorens JB, Ritz M, Chevrolet JC.** Nitric oxide and prostacyclin as test agents of vasoreactivity in severe precapillary pulmonary hypertension: Predictive ability and consequences on haemodynamics and gas exchange. Thorax 1997; 52:369–372.
20. **Channick RN, Newhart JW, Johnson FW et al.** Pulse delivery of inhaled nitric oxide to patients with primary pulmonary hypertension. Chest 1996; 109:1545–1549.
21. **Moncada S, Gryglewski R, Bunting S, Vane JR.** An enzyme isolated from arteries transforms prostaglandin endoperoxides to an unstable substance that inhibits platelet aggregation. Nature 1976; 263:663–665.
22. **Magnani B, Galie N.** Prostacyclin in primary pulmonary hypertension. Eur Heart J 1996; 17:18–24.
23. **Higenbottam TW, Wheeldon D, Wells FC, Wallwork J.** Long-term treatment of primary pulmonary hypertension with continuous intravenous epoprostenol (prostacyclin). Lancet 1984; 1:1046–1047.
24. **Barst RJ, Rubin LJ, Long WA, et al.** A comparison of continuous intravenous epoprostenol (prostacyclin) with conventional therapy for primary pulmonary hypertension. N Engl J Med 1996; 334:296–301.
25. **Shapiro SM, Oudiz RJ, Cao T, et al.** Primary pulmonary hypertension: improved long-term effects and survival with continuous intravenous epoprostenol infusion. J Am Coll Cardiol 1997; 30:343–349.
26. **McLaughlin VV, Genthner DE, Panella MM, Rich S.** Reduction in pulmonary vascular resistance with long-term epoprostenol (prostacyclin) therapy in primary pulmonary hypertension. N Engl J Med 1998; 338:273–277.
27. **Olschewski H, Walmrath D, Schermuly R, Ghofrani A, Grimminger F, Seeger W.** Aerosolized prostacyclin and iloprost in severe pulmonary hypertension. Ann Intern Med 1996; 124:820–824.
28. **Saji T, Ozawa Y, Ishikita T, Matsuura H, Matsuo N.** Short-term hemodynamic effect on a new oral PGI2 analogue, beraprost, in primary pulmonary and secondary pulmonary hypertension. Am J Cardiol 1996; 78:244–247.
29. **Okano Y, Yoshioka T, Shimouchi A, Satoh T, Kunieda T.** Orally active prostacyclin analogue in primary pulmonary hypertension [letter]. Lancet 1997; 349:1365.
30. **Fuster V, Steele PM, Edwards WD, Gersh BJ, McGoon MD, Frye RL.** Primary pulmonary hypertension: Natural history and the importance of thrombosis. Circulation 1984; 70:580–587.
31. **Frank H, Mlczoch J, Huber K, Schuster E, Gurtner HP, Kneussl M.** The effect of anticoagulant therapy in primary and anorectic drug-induced pulmonary hypertension. Chest 1997; 112:714–721.
32. **Weiss BM, Zemp L, Seifert B, Hess OM.** Outcome of pulmonary vascular disease in pregnancy: A systematic overview from 1978 through 1996. J Am Coll Cardiol 1998; 31:1650–1657
33. **Sandoval J, Gaspar J, Pulido T, et al.** Graded balloon dilation atrial septostomy in severe pulmonary hypertension. J Am Coll Cardiol 1998; 32:297–304.
34. **Kerstein D, Levy PS, Hsu DT, Hordorf AJ, Gersony WM, Barst RJ.** Blade balloon atrial septostomy in patients with severe primary pulmonary hypertension. Circulation 1995; 91:2028–2035.
35. **Gaine SP, Rubin LJ.** Medical and surgical treatment options for pulmonary hypertension. Am J Med Sci 1998; 315:179–184.
36. **Maurer JR, Frost AE, Glanville AR, Estenne M, Higenbottam T.** International guidelines for the selection of lung transplant candidates. Am J Respir Crit Care Med 1998; 158:335–339.
37. **Stewart DJ, Levy RD, Cernacek P, Langleben D.** Increased plasma endothelin-1 in pulmonary hypertension: Marker or mediator of disease? Ann Intern Med 1991; 114:464–469.
38. **Giaid A, Ynagisawa M, Langleben D et al.** Expression of endothelin-1 in the lungs of patients with pulmonary hypertension. N Engl J Med 1993; 328:1732–1739.
39. **Christman BW, McPherson CD, Newman JH, et al.** An imbalance between the excretion of thromboxane and prostacyclin metabolites in pulmonary hypertension. N Engl J Med 1992; 327:70–75.
40. **Adnor S, Raffestin B.** Pulmonary hypertension: NO therapy? Thorax 1996; 51:762–764.
41. **Loscalzo J.** Nitric oxide and vascular disease [editorial]. N Engl J Med 1995; 333:251–253.
42. **Stamler JS, Loh E, Rody MA, Currie KE, Creager MA.** Nitric oxide regulates basal systemic and pulmonary vascular resistance in healthy humans. Circulation 1994; 89:2035–2040.
43. **Cooper CJ, Landzberg MJ, Anderson TJ, et al.** Role of nitric oxide in the local regulation of pulmonary vascular resistance in humans. Circulation 1996; 93:266–271.
44. **Voelkel NF, Hoeper M, Maloney J, Tuder RM.** Vascular endothelial growth factor in pulmonary hypertension. Ann NY Acad Sci 1996; 796:186–193.
45. **Kaneko FT, Arroliga AC, Dweik RA, et al.** Biochemical reaction products of nitric oxide as quantitative markers of primary pulmonary hypertension. Am J Respir Crit Care Med 1998; 158:917–923.
46. **Stenmark KR, Mecham RP.** Cellular and molecular mechanism of pulmonary vascular remodeling. Annu Rev Physiol 1997; 59:89–144.
47. **Schuster DP, Crouch EC, Parks WC, Johnson T, Botney MD.** Angiotensin converting enzyme expression in primary pulmonary hypertension. Am J Respir Crit Care Med 1996; 154:1087–1091.
48. **Herve P, Launay JM, Scrobohaci ML, et al.** Increased plasma serotonin in primary pulmonary hypertension. Am J Med 1995; 99:249–254.
49. **Chaouat A, Weitzenblum E, Higenbottam T.** The role of thrombosis in severe pulmonary hypertension. Eur Respir J 1996; 9:356–363.
50. **Cacoub P, Karmochkine M, Dorent R, et al.** Plasma levels of thrombomodulin in pulmonary hypertension. Am J Med 1996; 101:160–164.

ADDRESS: *Alejandro C. Arroliga, MD, Medical Intensive Care Unit, G62, The Cleveland Clinic Foundation, 9500 Euclid Avenue, Cleveland OH 44195; e-mail arrolia@ccf.org.*

Downloaded from www.ccjm.org on June 5, 2025. For personal use only. All other uses require permission.