

## **Q: What do you recommend for a patient with a Pap smear indicating atypical cells?**

**ALEXANDER W. KENNEDY, MD**

Head, Section of Gynecologic Oncology,  
Department of Gynecology and Obstetrics, Cleveland Clinic

**A:** IF A PREMENOPAUSAL PATIENT has a finding of atypical squamous cells of undetermined significance (ASCUS) on a Papanicolaou smear, we test for human papillomavirus (HPV) DNA.<sup>1,2</sup> If the specimen for the Pap smear was collected into a liquid medium (as opposed to the traditional method of using a glass slide and aerosol fixative), the HPV test can be performed on the same specimen<sup>3</sup>; if not, the patient must return for cervical sampling.

At least 10 types of HPV affect the female genital tract, some of which are associated with a substantially higher risk of cervical cancer than others. If a patient with ASCUS is found to have one of the high-risk types of HPV, we recommend colposcopy. Patients with ASCUS who have low-risk HPV types or who are HPV-negative are asked to return in 6 months for a follow-up Pap smear.

If a postmenopausal patient is found to have ASCUS, we repeat the Pap smear in 4 weeks. In the interval, we recommend that the patient use vaginal estrogen cream (conjugated equine estrogens [Premarin], one full applicator nightly) for the first 2 weeks and then wait 2 weeks before the visit. The estrogen eliminates atrophy as a cause of atypia.

### ■ OTHER OPTIONS

In the past, many clinicians merely repeated the Pap smear and based management on these results. Given the current medicolegal climate and the known false-negative rate for Pap smears, this approach is not generally recommended.<sup>4</sup>

Colposcopy is another option; however, it is expensive and time-consuming to perform

colposcopy in all patients with minor abnormalities such as ASCUS.

### ■ AGUS IS DIFFERENT

The finding of atypical *glandular* cells (AGUS) is completely different and much more significant than ASCUS.<sup>5</sup> Studies indicate that upwards of 30% of cases of AGUS represent serious underlying conditions, notably adenocarcinoma in situ, adenocarcinoma of the cervix, endometrial adenocarcinoma, and squamous lesions of the cervix. Therefore, a patient with AGUS should be referred immediately for a complete evaluation, including colposcopy, endocervical curettage, and possible endometrial biopsy.

### ■ PUTTING ASCUS IN PERSPECTIVE

Laboratories are reporting more abnormal Pap results than in the past, for several possible reasons.

First is simply that the category of ASCUS exists—it was formally recognized in 1989 with the institution of the Bethesda system, the standardized categorization system for reporting results.<sup>6</sup> Having this borderline category has led to an increase in the number of “abnormal” Pap smears being reported by laboratories.

In addition, owing to medicolegal concerns, laboratories are tending to report minor abnormalities more frequently to avoid false-negative results.

Another change has been the shift toward liquid-based cytology. Collecting and transporting cells in a liquid medium for later filtration and single-layer suspension yields better specimens, and probably a higher rate of detection of neoplasias.

It is important to communicate closely with the laboratory so that the clinician can

**Follow up  
atypical cells  
on a Pap smear  
with testing  
for HPV**



receive abnormal results promptly and understand them clearly. In addition, the laboratory should give the clinician periodic reports to indicate its overall rate of atypical cells and squamous intraepithelial lesions. In general, in a normal-risk population, the rate of finding atypical cells should be less than 5%. Alternatively, the atypical cell rate should be no more than two to three times the rate of dysplasias being reported.

Finally, to properly interpret minimal abnormalities, the clinician should have a general idea of the prevalence of various risk factors for cervical neoplasia (ie, cigarette smoking, multiple sexual partners, young age at first sexual intercourse) in his or her practice population and also whether the individual patient has any of these risk factors.

## REFERENCES

1. Cox JT, Lorinez AT, Schiffman MH, Sherman ME, Cullen A, Kurman RJ. Human papillomavirus testing by hybrid capture appears to be useful in triaging women with a cytologic diagnosis of atypical squamous cells of undetermined significance. *Am J Obstet Gynecol* 1995; 172:946-954.
2. Manor MM, Kinney WK, Hurley LB, et al. Identifying women with cervical neoplasia using human papillomavirus DNA testing for equivocal Papanicolaou results. *JAMA* 1999; 281:1605-1610.
3. Lee KR, Ashfaq R, Birdsong G, Corkill ME, McIntosh KM, Inhorn SL. Comparison of conventional Papanicolaou smears and a fluid based, thin layer system for cervical cancer screening. *Obstet Gynecol* 1997; 90:278-284.
4. Kurman RJ, Henso DE, Herbst AL, Noeller KL, Schiffman MH. Interim guidelines for management of abnormal cervical cytology. The 1992 National Cancer Institute Workshop. *JAMA* 1994; 271:1866-1969.
5. Kennedy AW, Salmieri SS, Wirth SL, Biscotti CV, Tuason LJ, Travarca MJ. Results of the clinical evaluation of atypical glandular cells of undetermined significance (AGCUS) on routine cervical cytology screening. *Gynecol Oncol* 1996; 60:14-18.
6. National Cancer Institute Workshop. The 1998 Bethesda system for reporting cervical/vaginal cytologic diagnosis. *JAMA* 1989; 262:931-934.

**ADDRESS:** Alexander W. Kennedy, MD, Department of Gynecology and Obstetrics, A81, The Cleveland Clinic Foundation, 9500 Euclid Avenue, Cleveland, OH 44195, e-mail [kenneda@ccf.org](mailto:kenneda@ccf.org).

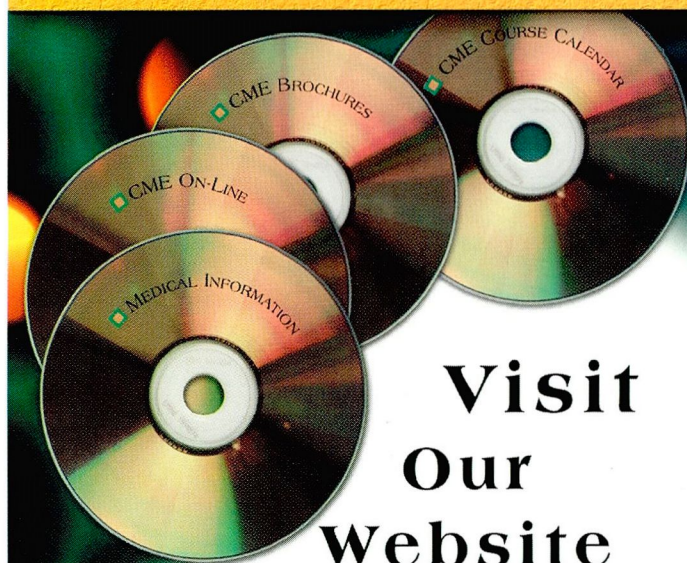
## CME ANSWERS



Answers to the CREDIT TEST on page 687 of this issue

1 B 2 A 3 A 4 B 5 A 6 B 7 B 8 A 9 B 10 A  
11 A 12 B 13 B 14 E 15 D 16 B

## CLEVELAND CLINIC CENTER FOR CONTINUING EDUCATION



# Visit Our Website

## For Information on Online CME & Upcoming Courses

- 3rd Annual Principles & Practices of Carotid Intervention, September 21-23
- An Intensive Review of Cardiology, September 24-29
- Gastroenterology Update, September 14-15

[www.clevelandclinicmeded.com](http://www.clevelandclinicmeded.com)