



The Clinical Picture

A 44-year-old man with a pruritic skin rash

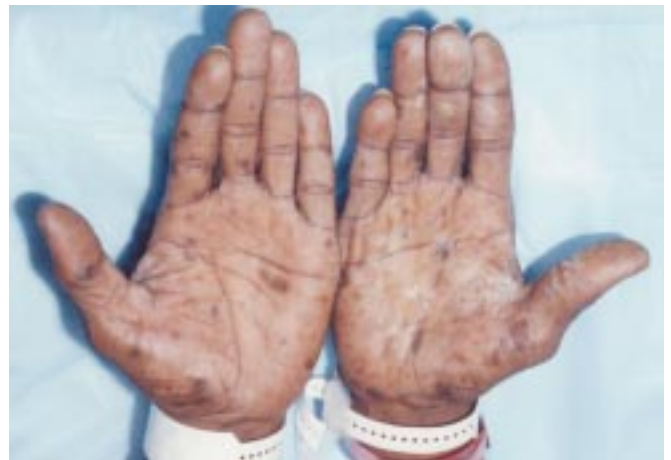
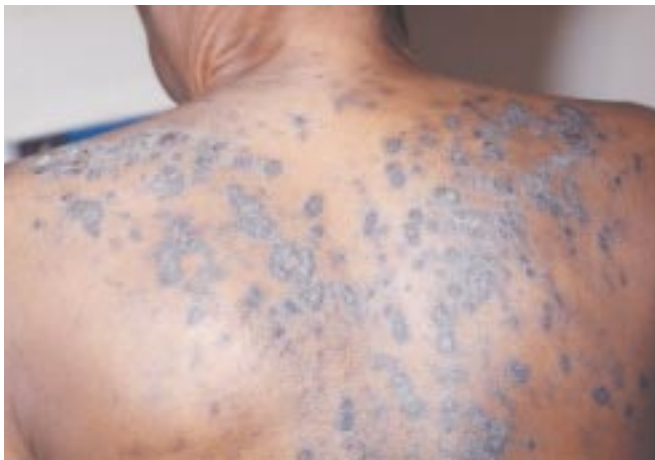
FIGURE 1. The rash was pruritic and symmetrically distributed

Q: A 44-YEAR-OLD MAN with a history of hypertension and end-stage renal disease presents with a pruritic skin rash lasting 6 months. The rash (FIGURE 1) is symmetrically distributed on the trunk, the palms, and the flexor aspect of the forearms and legs. He has no oropharyngeal lesions and no involvement of the genitalia.

He is currently on hemodialysis three times a week and is taking hydralazine, clonidine, multivitamins, and calcium carbonate.

What is the most likely diagnosis for his rash?

- ☐ Lichen planus
- ☐ Systemic lupus erythematosus
- ☐ Lichen planus-like eruption
- ☐ Secondary syphilis
- ☐ Psoriasis

A: The patient has lichen planus-like eruption, a chronic inflammatory dermatosis involving the skin or the mucous membranes or both. It appears as grouped or disseminated oval papules and plaques, clin-

ically indistinguishable from lichen planus. In fair-skinned patients it appears as violaceous, flat (Latin *planus*, “flat”), shiny papules with marked desquamation. Hyperpigmentation is common in dark-skinned patients. Involvement of the mucous membrane occurs in 40% to 60% of patients, less often than in idiopathic lichen planus.¹

■ LICHENOID DRUG ERUPTION

Lichen planus-like eruption has been described in association with lymphoma, chronic graft-vs-host disease, dermatomyositis, and commonly used drugs. When the condition is due to drugs, it is termed lichenoid drug eruption. The latent period between the administration of the offending drug and the skin eruption can be from 3 weeks to 3 years, depending on the drug, the dosage, and concomitant drug treatment.

The list of drugs that can cause lichenoid drug eruption is extensive and is expanding, with recent additions including sildenafil (Viagra)² and simvastatin (Zocor).³ Commonly implicated drugs are gold salts, antimalarials, diuretics, angiotensin-converting enzyme inhibitors, antibiotics (most commonly streptomycin and tetracycline), and beta-blockers.




■ DIAGNOSIS

The differential diagnosis of lichenoid drug eruption includes lichen planus, systemic lupus erythematosus, secondary syphilis, and psoriasis. Distribution of the lesions, negative serologic tests, and the patient's history often help to distinguish lichenoid drug eruption from other skin diseases and to identify the drug that is causing it.

Histopathologic analysis of a skin biopsy specimen helps with the diagnosis. The presence of eosinophils and plasma cells in the cellular infiltrate, accompanied by focal parakeratosis and perivascular inflammation, strongly suggests lichenoid drug eruption rather than idiopathic lichen planus.⁴ In fact, the presence of eosinophils in the infiltrate is now usually considered a clue to the diagnosis. In addition, in contrast to non-lichenoid drug reactions such as anaphylaxis and erythema multiforme, lichenoid drug eruptions are heavily inflamed with a prominent interstitial pattern.⁵ Even with a biopsy, however, it may not be possible to differentiate lichenoid drug eruption from idiopathic lichen planus.

In our patient, skin biopsy revealed inflammation with focal parakeratosis and a perivascular mixed cellular infiltrate with eosinophils, a histopathologic picture consistent with lichenoid drug eruption. Serologic tests for syphilis and antinuclear antibody (ANA) were negative.

■ TREATMENT

Therapy for lichenoid drug eruption consists of stopping the suspected offending drug. The time to resolution of symptoms depends on the drug and may take up to 12 weeks. In our patient, hydralazine was stopped, as the other drugs he was taking were less frequently reported to cause this condition. The rash resolved within a few weeks. Re-exposure to the same drug can be dangerous, so challenge tests are not recommended. 

■ REFERENCES

1. Halevy S, Shai A. Lichenoid drug eruptions. *J Am Acad Dermatol* 1993; 29:249–255.
2. Goldman BD. Lichenoid drug reaction due to sildenafil. *Cutis* 2000; 65:282–283.
3. Roger D, Rolle F, Labrousse F, Brosset A, Bonnetblanc JM. Simvastatin-induced lichenoid drug eruption. *Clin Exp Dermatol* 1994; 19:88–89.
4. Van den Haute V, Antoine JL, Lachapelle JM. Histopathological discriminant criteria between lichenoid drug eruption and idiopathic lichen planus: retrospective study on selected samples. *Dermatologica* 1989; 179:10–13.
5. Weedon D. *Skin pathology*. Edinburgh: Churchill Livingstone Co, 1997:39.

ADDRESS: Raed Bargout, MD, 1348 S. Finley Rd, Apt. 3D, Lombard, IL 60148.