



The Clinical Picture

A 47-year-old man with a sore throat

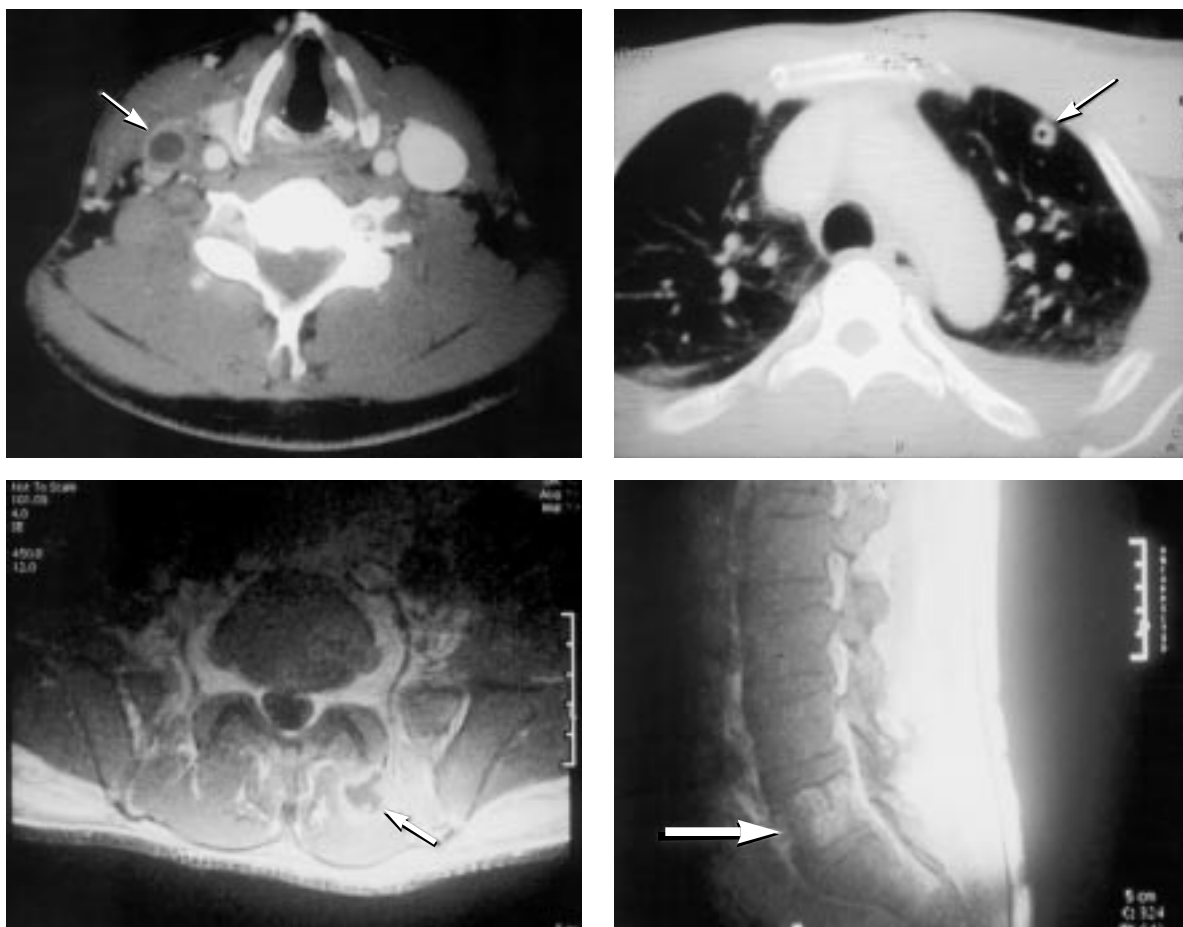


FIGURE 1

Q: A PREVIOUSLY HEALTHY 47-year-old man presented with fever, low back pain, and rash. Ten days earlier he had developed pharyngitis, which he treated with acetaminophen and throat lozenges. After 1 week of progressive odynophagia, he also developed ear pain and ataxia. Physical examination revealed fever (temperature 102.6° F, 38.7° C), palatal petechiae, a right-side ruptured peritonsillar abscess, anterior cervical lymphadenopathy, and bibasilar inspiratory crack-

les. There was tenderness to palpation of the lumbar spine, pain with internal and external rotation of the left hip, and palpable purpura on all four extremities. The white blood cell count was $21.9 \times 10^9/L$ with 86% neutrophils.

Subsequent studies revealed an intraluminal thrombus occluding the right internal jugular vein (FIGURE 1, upper left, arrow), pulmonary cavitary infiltrates (FIGURE 1, upper right, arrow), multiple paraspinal muscle abscesses (FIGURE 1, lower left, arrow), inflammation of the left hip joint, and osteomyelitis of the L5 vertebral body (FIGURE 1, lower right, arrow).

*The views expressed herein are those of the authors and do not necessarily reflect the views of the US Army or the Department of Defense.



What is the most likely diagnosis?

- ☐ Vincent's angina
- ☐ Ludwig's angina
- ☐ Lemierre syndrome
- ☐ Infective endocarditis
- ☐ Brucellosis

A: The presentation is consistent with Lemierre syndrome, which is characterized by an oropharyngeal infection with subsequent internal jugular vein or tonsillar vein thrombophlebitis, anaerobic bacteremia, and septic embolization to multiple potential sites. The causative organism is usually *Fusobacterium necrophorum*, a colonizer of the oropharynx.¹

Also known as necrobacillosis or postanginal sepsis, Lemierre syndrome typically affects previously healthy young adults or adolescents (mean age 20 years).² It has been hypothesized that immature tonsillar architecture may predispose this age group to progression of infection beyond pharyngitis to the deep parapharyngeal tissues.³ Indeed, at age 47, our patient is significantly older than most patients with this condition.

Typical presentation

Patients with Lemierre syndrome usually present with a systemic illness, with fever, rigor, and malaise. They typically describe an antecedent pharyngitis which may improve or resolve, and they may complain of trismus or neck pain. On physical examination, patients may have a tender palpable cord anterior to the sternocleidomastoid muscle near the ramus of the jaw—a sign of tonsillar vein or internal jugular vein thrombophlebitis. Septic embolization to the lungs and other distant sites frequently occurs, causing arthritis, osteomyelitis, soft-tissue abscesses, and disseminated intravascular coagulation.¹

Diagnostic techniques

The diagnosis of Lemierre syndrome is now more commonly applied to all cases of human necrobacillosis with a primary focus anywhere in the head, rather than exclusively in the oropharynx.⁴ The diagnosis is aided by enhanced computerized tomography (CT), magnetic resonance imaging (MRI), or angiography of the neck. Although they are not specific, abnormal laboratory values may reflect sites of metastatic disease (eg, elevated liver-associated enzymes caused by hematogenous seeding to the liver).

Treatment

Treatment of Lemierre syndrome consists of surgical drainage of abscesses and a prolonged course of intravenous antibiotics. *Fusobacterium* is usually sensitive to metronidazole, chloramphenicol, clindamycin, and imipenem. *Fusobacterium* species have also been highly sensitive to penicillin, but, there appears to be an increasing prevalence of beta-lactam resistance in these organisms.⁵

Venous ligation or resection is rarely necessary but may be indicated for persistent septicemia. In anecdotal reports,^{6,7} intravenous heparin was beneficial in treating thrombophlebitis, but its role is still controversial.

Disease course

In the era before antibiotics, Lemierre syndrome was a frequent complication of oropharyngeal infection and was often fatal.⁴ However, its incidence has sharply declined since then, causing some to call it a “forgotten disease.”^{8–11} This case reminds us to consider this diagnosis in the appropriate clinical setting in order to promptly initiate potentially life-saving therapy.

REFERENCES

- Chan ED, Hermanoff MH, Connick E. Lemierre's syndrome: review of the English literature over the past 25 years. *Clin Pulm Med* 1999; 6:333–338.
- Jousimes-Somer H, Savolainen S, Makitie A, Ylikoski J. Bacteriologic findings in peritonsillar abscesses in young adults. *Clin Infect Dis* 1993; 16 (Suppl 4):S292–298.
- Irigoyen MM, Katz M, Larsen JG. Postanginal sepsis in adolescents. *Pediatr Infect Dis* 1983; 2:247–250.
- Kristensen LH, Prag J. Human necrobacillosis, with emphasis on Lemierre's syndrome. *Clin Infect Dis* 2000; 31:524–532.
- Ahkee S, Srinath L, Huang A, Raff MJ, Ramirez JA. Lemierre's syndrome: postanginal sepsis due to anaerobic oropharyngeal infection. *Ann Otol Rhinol Laryngol* 1994; 103:208–210.
- Josey WE, Stagers SR. Heparin therapy in septic pelvic thrombophlebitis: a study of 46 cases. *Am J Obstet Gynecol* 1974; 120:228–233.
- Bach MC, Roediger JH, Rinder HM. Septic anaerobic jugular phlebitis with pulmonary embolism: problems in management. *Rev Infect Dis* 1988; 10:424–427.
- Moore-Gillon J, Lee TH, Eykyn SJ, Phillips I. Necrobacillosis: a forgotten disease. *BMJ* 1984; 288:1526–1527.
- Weesner CL, Cisek JE. Lemierre syndrome: the forgotten disease. *Ann Emerg Med* 1993; 22:256–258.
- Carlson ER, Bergamo DF, Coccia CT. Lemierre's syndrome: two cases of a forgotten disease. *J Oral Maxillofac Surg* 1994; 52:74–78.
- Koay CB, Heyworth T, Burden P. Lemierre syndrome: A forgotten complication of acute tonsillitis. *J Laryngol Otol* 1995; 109:657–661.

ADDRESS: Michael Zapor, MD, PhD, senior resident, Department of Medicine, Brooke Army Medical Center, 3851 Roger Brooke Dr, Fort Sam Houston, TX 78234-6200; e-mail: rzapor@idworld.net.