

**METIN ÖZKAN, MD**

Department of Pulmonary and Critical Care Medicine, Cleveland Clinic

**RAED A. DWEIK, MD**

Department of Pulmonary and Critical Care Medicine, Cleveland Clinic

**MUZAFFAR AHMAD, MD**

Department of Pulmonary and Critical Care Medicine, Chairman, Division of Medicine, Cleveland Clinic

# Drug-induced lung disease

## ABSTRACT

Drug-induced lung disease is a major source of iatrogenic injury. We review the various drugs known to induce injury and the various patterns of injury seen.

## KEY POINTS

Different drugs can cause similar pulmonary syndromes and presentations.

The most common presentations are an abnormality on the chest radiograph and a symptom complex.

Early diagnosis is very important and requires the physician to be vigilant for problems in the appropriate clinical settings.

The diagnosis is usually one of exclusion.

Stopping the drug is sufficient therapy for most drug toxicities, but corticosteroid administration may also be needed.

**A**WARENESS OF drug-induced pulmonary disease is increasing: a review published in 1972 identified only 19 drugs as having the potential to cause pulmonary disease<sup>1</sup>; now at least 150 agents are recognized,<sup>2,3</sup> and the list continues to grow (TABLE 1).

Adverse reactions occur in about 5% of patients receiving any drug, and 0.03% of hospital deaths are believed to be drug-related.<sup>2</sup>

Early diagnosis is important, because stopping the drug usually reverses toxicity, whereas unrecognized toxicity can be progressive and even fatal. Diagnosis requires being alert and vigilant for adverse pulmonary reactions in the appropriate clinical settings.

A carefully obtained history that includes medications (including those sold over-the-counter) is essential to suspecting a drug-induced reaction.

In this update, we review the patterns of response seen in drug-induced lung disease. We also review selected drugs because of their importance in drug-induced lung disease, classic presentations of toxicity, prevalence of use, or because our understanding of them has recently changed.

## PATTERNS OF RESPONSE

Drug-induced pulmonary diseases can present in a variety of syndromes (TABLE 2), clinical presentations (TABLE 3), and radiographic patterns (TABLE 4). The most common presentations of drug-induced pulmonary disease are an abnormality on a chest radiograph or a symptom complex.

### Hypersensitivity reactions

Most of the drugs that cause pulmonary side effects can show their effects as hypersensitivity reactions. Respiratory symptoms consist of dyspnea, cough, and fever. Peripheral eosinophilia,

**TABLE 1****Selected drugs known to adversely affect the lungs****Anticonvulsant, antipsychotic, antidepressant**

Carbamazepine  
Chlordiazepoxide  
Fluoxetine  
Phenothiazines  
Phenytoin  
Trazodone  
Tricyclics

**Anti-inflammatory**

Aspirin  
Gold  
Methotrexate  
Penicillamine

**Antimetabolic**

Azathioprine  
Cytarabine  
Fludarabine  
Gemcitabine  
6-Mercaptopurine  
Methotrexate

**Antimicrobial**

Amphotericin B  
Ethambutol  
Isoniazid  
Minocycline  
Nitrofurantoin  
Para-aminosalicylic acid  
Streptomycin  
Sulfasalazine  
Sulfonamides  
Tetracycline

**Biologic response modifiers**

Granulocyte-macrophage colony-stimulating factor  
Interferon  
Interleukin-2  
Tumor necrosis factor

**Cardiovascular**

Amiodarone  
Angiotensin-converting enzyme inhibitors  
Anticoagulants  
Beta-blockers  
Dipyridamole  
Flecainide  
Hydralazine  
Hydrochlorothiazide  
Protamine  
Tocainide

**Chemotherapeutic and immunosuppressive**

Bleomycin  
Busulfan  
Chlorambucil  
Cyclophosphamide  
Cyclosporin A  
Etoposide  
Hormonal agents  
    Bicalutamide  
    Nilutamide  
    Tamoxifen  
Melphalan  
Mitomycin-C  
Nitrosoureas  
Procarbazine  
Vinca alkaloids (with mitomycin)

**Contrast media and intravenous substances**

Blood  
Ethanolamine oleate  
Ethiodized oil  
Talc

**Illicit drugs**

Cocaine  
Heroin  
Methadone  
Methylphenidate  
Narcotic and sedative drugs

**Miscellaneous agents**

Appetite suppressants (dexfenfluramine, fenfluramine, phentermine)  
Beta mimetics (terbutaline, ritodrine)  
Bromocriptine  
Dantrolene  
L-tryptophan  
Methysergide  
Mineral oil  
Propylthiouracil  
Radiation  
Silicone  
Timolol (ophthalmic)  
Tocolytic agents

TABLE 2

### Syndromes of drug-induced pulmonary disease

Asthma  
 Bronchiolitis obliterans organizing pneumonia  
 Hypersensitivity infiltrate  
 Interstitial pneumonitis or fibrosis  
 Noncardiogenic pulmonary edema  
 Pleural effusions  
 Pulmonary infiltrates with eosinophilia  
 Pulmonary vascular disease

if present, may help indicate the diagnosis. Chest radiographs show localized or bilateral alveolar infiltrates.

#### Noncardiogenic pulmonary edema

The syndrome of noncardiogenic pulmonary edema manifests as acute respiratory distress occurring over several hours. In most instances this is due to capillary endothelial injury, causing increased permeability edema.<sup>4</sup> Chest roentgenograms show diffuse ill-defined acinar infiltrates and normal heart size. Physical examination demonstrates diffuse crackles, and laboratory examination shows significant hypoxemia.

#### Interstitial pneumonitis or fibrosis

Acute pneumonitis may present in a manner similar to noncardiogenic pulmonary edema. In the chronic form, manifestations are a slowly progressive cough, dyspnea, weight loss, and clubbing. Radiographic findings are usually reticular infiltrates starting in the subpleural region of the lung bases and progressing to include the entire lung. The prognosis generally is worse than for drug-induced noncardiogenic pulmonary edema.

#### Pleural and mediastinal disorders

Pleural effusions that resolve spontaneously or with discontinuation of the drug are seen in drug-induced systemic lupus erythematosus. Pneumothorax may complicate systemic chemotherapy and illicit drug use. Hemothorax or mediastinal hematoma can be a complication of anticoagulants. Mediastinal

adenopathy may be a complication of dilantin, cyclosporin, or methotrexate use. Mediastinal lipomatosis may complicate corticosteroid use.<sup>5</sup> An acute pleural effusion in association with drugs can also be seen as part of a hypersensitivity reaction.

#### Pulmonary vascular disease

The incidence of pulmonary veno-occlusive disease, characterized by the occlusion of pulmonary venules with subsequent elevated pulmonary arterial pressures, is increased in patients receiving cytotoxic agents for the treatment of malignancy. The diagnosis usually requires an open lung biopsy. Illicit drugs can cause angiitis and hypertension. Alpha-adrenergic nasal sprays have been associated with interstitial fibrosis and obliteration of pulmonary vessels. Estrogen-containing drugs as well as appetite suppressants have been associated with development of pulmonary hypertension.<sup>6</sup>

#### Drug-induced lupus

Drugs may exacerbate underlying lupus, induce lupus in a predisposed patient, or cause the disease. Patients with drug-induced lupus can develop a variety of systemic symptoms, including fever, myalgias, rash, arthralgias, arthritis, and serositis.<sup>7</sup> The lungs and pleurae are involved in 50% to 75% of cases of drug-induced lupus.<sup>4</sup> Patterns of response can be pleural effusion with or without pleuritic pain, diffuse interstitial pneumonitis, and alveolar infiltrates.<sup>4</sup>

Important features seen in drug-induced lupus can help differentiate it from spontaneous lupus. The female-to-male ratio is 1:1 in drug-induced lupus, but 9:1 in spontaneous lupus. Manifestations that are rare in drug-induced lupus include discoid lesions (occurring in 0% of cases in one series), malar erythema (2%), renal disease (5%), and central nervous system disease (0%). Complement and immune complexes are normal in drug-induced lupus and elevated in spontaneous lupus. In more than 95% of cases of drug-induced lupus, antihistone antibodies are present but other autoantibodies are absent, including those directed against double-stranded DNA.<sup>7</sup>

It is estimated that more than 90% of

The lungs are involved in 50% to 75% of cases of drug-induced lupus

**TABLE 3****Drugs causing common clinical presentations of pulmonary toxicity****Asthma**

Aspirin  
 Beta-blockers  
 Cocaine  
 Dipyridamole  
 Hydrocortisone  
 Interleukin-2  
 Methylphenidate  
 Nitrofurantoin  
 Protamine  
 Sulfasalazine  
 Timolol  
 Vinca alkaloids (with mitomycin)

**Bronchiolitis obliterans organizing pneumonia**

Amiodarone  
 Bleomycin  
 Cocaine  
 Cyclophosphamide  
 Methotrexate  
 Mitomycin-C  
 Penicillamine  
 Radiation  
 Sulfasalazine  
 Tetracycline, minocycline

**Drug-induced systemic lupus erythematosus**

Diltiazem  
 Diphenylhydantoin  
 Hydralazine  
 Hydrochlorothiazide  
 Isoniazid  
 Minocycline  
 Para-aminosalicylic acid  
 Penicillamine  
 Procainamide  
 Propylthiouracil  
 Streptomycin  
 Sulfonamides

**Hypersensitivity infiltrate**

Azathioprine plus 6-mercaptopurine  
 Busulfan  
 Fluoxetine  
 Radiation

**Interstitial pneumonia or fibrosis**

Amphotericin B  
 Bleomycin  
 Busulfan  
 Carbamazepine  
 Chlorambucil  
 Cocaine  
 Cyclophosphamide  
 Diphenylhydantoin  
 Flecainide  
 Heroin  
 Melphalan  
 Methadone  
 Methotrexate  
 Methylphenidate  
 Methysergide  
 Mineral oil  
 Nitrofurantoin  
 Nitrosoureas  
 Procarbazine  
 Silicone  
 Tocainide  
 Vinca alkaloids (with mitomycin)

**Noncardiac pulmonary edema**

Beta mimetics (terbutaline, ritodrine)  
 Chlordiazepoxide  
 Cocaine  
 Cytarabine  
 Ethiodized oil  
 Gemcitabine  
 Heroin  
 Hydrochlorothiazide  
 Methadone  
 Mitomycin-C  
 Phenothiazines  
 Protamine  
 Sulfasalazine  
 Tocolytic agents  
 Tricyclics  
 Tumor necrosis factor  
 Vinca alkaloids (with mitomycin)

**Parenchymal hemorrhage**

Anticoagulants  
 Azathioprine plus 6-mercaptopurine  
 Cocaine  
 Mineral oil  
 Nitrofurantoin  
 Radiation

**Pleural effusion**

Amiodarone  
 Anticoagulants  
 Bleomycin  
 Bromocriptine  
 Busulfan  
 Granulocyte-macrophage colony-stimulating factor (GM-CSF)  
 Interleukin-2  
 Methotrexate  
 Methysergide  
 Mitomycin-C  
 Nitrofurantoin  
 Para-aminosalicylic acid  
 Procarbazine  
 Radiation  
 Tocolytic agents

**Pulmonary infiltrate with eosinophilia**

Amiodarone  
 Amphotericin B  
 Bleomycin  
 Carbamazepine  
 Diphenylhydantoin  
 Ethambutol  
 Etoposide  
 GM-CSF  
 Isoniazid  
 Methotrexate  
 Minocycline  
 Mitomycin-C  
 Nitrofurantoin  
 Para-aminosalicylic acid  
 Procarbazine  
 Radiation  
 Sulfasalazine  
 Sulfonamides  
 Tetracycline  
 Trazodone

**Pulmonary vascular disease**

Appetite suppressants (dexfenfluramine, fenfluramine, phentermine)  
 Busulfan  
 Cocaine  
 Heroin  
 Methadone  
 Methylphenidate  
 Nitrosoureas  
 Radiation



cases of drug-induced lupus are caused by diphenylhydantoin, hydralazine, isoniazid, or procainamide.

### Drug-induced bronchospasm

Evidence of increased airway resistance is seen in normal persons and patients with asymptomatic asthma who use propranolol and other beta-adrenergic antagonists.<sup>8</sup> These agents should be avoided in all patients with known obstructive lung disease whenever possible. The same findings have been shown to occur in asthmatic patients receiving timolol eye-drops for glaucoma.

Aspirin produces bronchospasm in about 4% of asthmatic patients,<sup>4</sup> and similar symptoms are seen with other nonsteroidal anti-inflammatory agents. In asthmatic persons with nasal polyps, the incidence may be as high as 75%.<sup>9</sup> Aspirin-induced bronchospasm generally becomes apparent in the third to fourth decade of life and is more common in women.

Interestingly some inhalational preparations used in the treatment of bronchospasm (eg, albuterol) can induce cough or bronchospasm because of materials other than the bronchodilator agent in the preparation.

## ■ EFFECTS OF CARDIOVASCULAR DRUGS

### Amiodarone

Amiodarone is a classic example of a cardiovascular drug that causes pulmonary toxicity. It is widely used to suppress ventricular and supraventricular tachyarrhythmias. Amiodarone can cause different patterns of pulmonary toxicity, including chronic interstitial pneumonitis, bronchiolitis obliterans, acute respiratory distress syndrome (ARDS), and solitary lung mass.<sup>10</sup> Furthermore, following ventilation with high oxygen concentration, patients receiving amiodarone may develop an ARDS-like syndrome. Suspected mechanisms of amiodarone lung toxicity include immunologic disorders, direct toxicity to the lung cells, and effects of free radicals.

When interstitial pneumonitis occurs, it is usually in patients receiving more than 400 mg/day. Chronic interstitial pneumonitis is characterized by insidious onset of nonpro-

**TABLE 4**

## Radiographic patterns of drug-induced lung disease

### Focal alveolar opacities

- Amiodarone
- Nitrofurantoin
- Aminosalicylic acid
- Penicillin
- Sulfonamides
- Mineral oil aspiration

### Diffuse alveolar opacities

- Pulmonary edema
  - Cocaine
  - Cytosine arabinoside
  - Heroin
  - Interleukin-2
  - Morphine
  - OKT3
  - Ritodrine
  - Salicylates
  - Terbutaline
  - Tricyclics

### Pulmonary hemorrhage

- Anticoagulants
- Cocaine
- Penicillamine
- Quinidine

### Diffuse interstitial opacities

- Methotrexate
- Nitrofurantoin
- Procarbazine
- Carmustine
- Bleomycin
- Busulfan
- Cyclophosphamide
- Methotrexate
- Mitomycin-C
- Amiodarone
- Gold salts
- Oxygen
- Tocainide

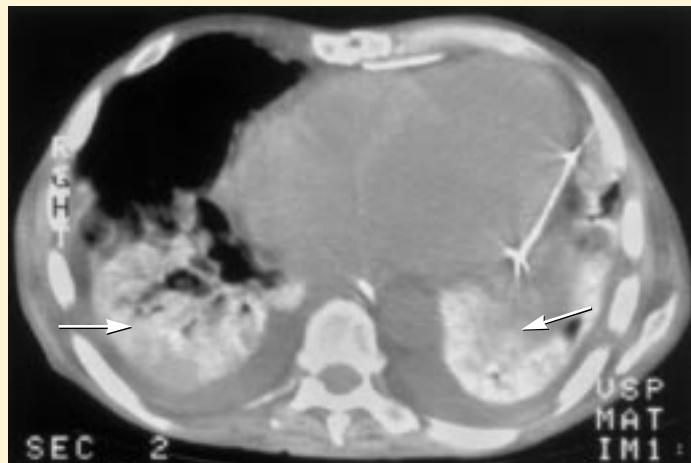### Pulmonary nodules

- Amiodarone
- Bleomycin
- Cyclosporine
- Mineral oil aspiration

**Bronchospasm due to aspirin generally becomes apparent in the 3rd to 4th decade of life**

ductive cough, dyspnea, weight loss, and diffuse interstitial and patchy alveolar infiltrates on the chest radiograph.

### Amiodarone-induced enhancement on computed tomography



**FIGURE 1.** A computed tomographic scan without contrast in a patient receiving amiodarone reveals infiltrates in both lung bases (arrows), due to the iodine content in amiodarone. This enhancement, however, is not pathognomonic for amiodarone toxicity.

### Cough develops in 3% to 20% of patients taking ACE inhibitors

Organizing pneumonia is characterized by nonproductive cough, pleuritic chest pain, fever, dyspnea, and patchy, alveolar opacities on chest radiographs (TABLE 4). It is seen in approximately 25% of cases of amiodarone pulmonary toxicity.

**Diagnosis.** Amiodarone toxicity (like most other drug toxicity) is a diagnosis of exclusion. The clinical presentation can be similar to pneumonia, congestive heart failure or pulmonary embolism.

Several tests may be helpful. It is important to emphasize, however, that none of these tests is specific or pathognomonic for amiodarone toxicity and cannot be relied on solely to make the diagnosis. These tests are used primarily to exclude other causes of the patient's presentation rather than to confirm amiodarone toxicity.

A positive gallium scan is seen in almost all patients with amiodarone pneumonitis and can help differentiate it from pulmonary embolism and congestive heart failure. A positive gallium scan, however, can also reflect pneumonia or other diseases causing infection or inflammation in the lungs, and thus cannot

be relied upon exclusively to make the diagnosis.

Because amiodarone contains about 37% iodine by weight, computed tomography (CT) of the lung (without contrast) may be helpful in diagnosis. Infiltrates caused by amiodarone toxicity may enhance even though contrast was not given (FIGURE 1).<sup>2</sup> This enhancement, however, is not pathognomonic for amiodarone toxicity either.

A bronchoscopy with bronchoalveolar lavage may be helpful in excluding infection. Histologically, an accumulation of foamy macrophages in the alveolar spaces, type II cell hyperplasia, and fibrosis are seen in amiodarone toxicity. These changes, however, are also seen in patients receiving amiodarone without toxicity and cannot be used solely to make the diagnosis.

**Primary treatment** is to stop amiodarone. Corticosteroid therapy, beginning with prednisone 40 to 60 mg/day and tapering over 2 to 6 months, can be life-saving in severe cases.<sup>10</sup>

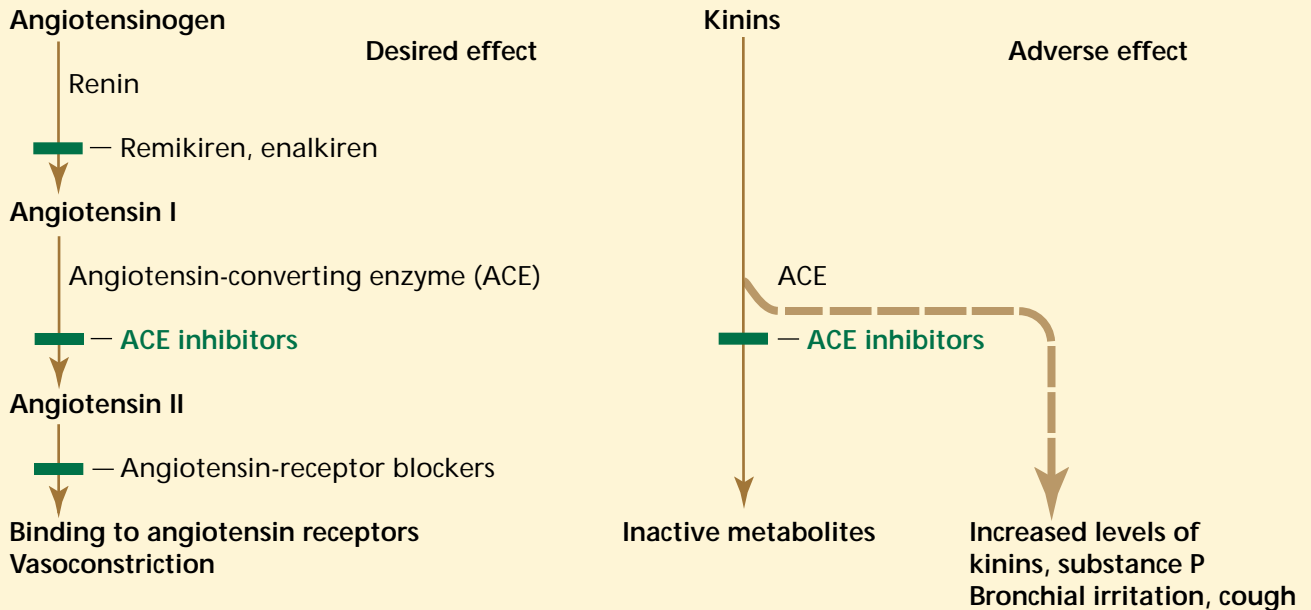
### Angiotensin-converting enzyme (ACE) inhibitors

In 3% to 20% of patients, ACE inhibitors induce a dry, persistent, and often nocturnal cough that may require stopping therapy. The cough usually begins several months after starting the drug but may begin as early as the first dose or as late as 1 year.<sup>2</sup> It usually diminishes significantly within 3 days and disappears entirely within 10 days of stopping the drug.

The pathogenesis of ACE inhibitor-induced cough is unclear, but kinins and substance P are suspected to play a role. Because both kinins and substance P are metabolized by angiotensin-converting enzyme (FIGURE 2), their levels are increased by converting enzyme inhibition,<sup>11</sup> leading to bronchial irritation and cough. Another possible explanation for cough is activation of the arachidonic acid pathway with ACE inhibition. By this mechanism, elevated levels of thromboxane may potentiate bronchoconstriction. In a study using picotamide,<sup>12</sup> which inhibits thromboxane synthase and antagonizes the thromboxane receptor, cough resolved in eight of nine patients who suffered from enalapril-induced cough.



## Why do angiotensin-converting enzyme (ACE) inhibitors cause cough? A possible explanation



**FIGURE 2.** ACE inhibitors have the favorable effect of blocking conversion of angiotensin I to angiotensin II (left), but also lead to accumulation of kinins and substance P (right), which may explain the side effects of bronchial irritation and cough associated with this class of medication. Newer agents (angiotensin II receptor blockers, remikiren, enalkiren) in theory would not be associated with cough.

Stopping the drug is usually enough for treatment. If the patient has a good antihypertensive response to the ACE inhibitor, an angiotensin II receptor antagonist, such as losartan, which blocks only angiotensin II receptors and has no effect on kinins or other mediators, can be considered.<sup>13</sup>

### ■ EFFECTS OF ANTI-INFLAMMATORY AGENTS

#### Aspirin

Aspirin triad is a syndrome characterized by asthma, nasal polyposis, and drug sensitivity. The frequency of the syndrome in asthmatic patients is approximately 4%.

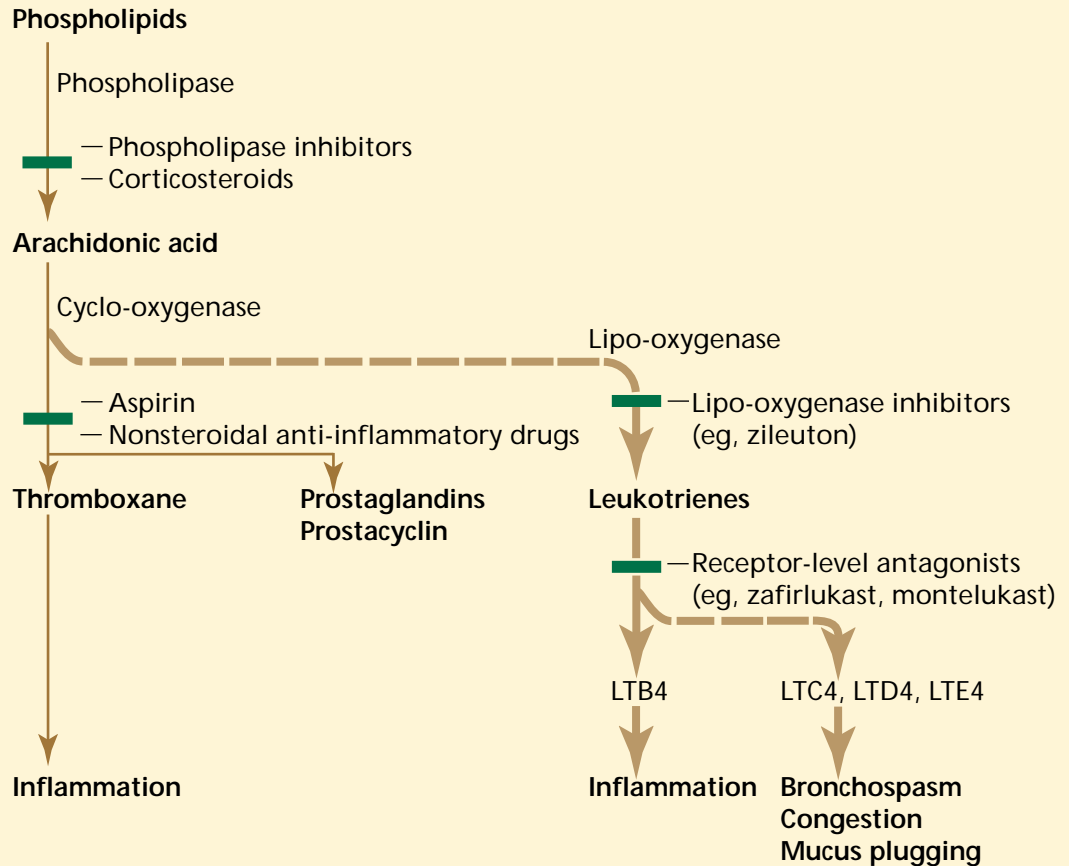
The first manifestation is vasomotor rhinitis with a watery discharge. It is followed by the appearance of nasal polyps, and by midlife, most patients demonstrate an asthmatic response.<sup>4</sup> Patients with aspirin-induced asthma are usually not previously sen-

sitive to aspirin; this usually appears in the third to fourth decade. Thirty minutes to 2 hours after aspirin ingestion, symptoms such as wheezing, facial flushing, angioedema, and gastrointestinal symptoms begin.

Aspirin inhibits cyclo-oxygenase I, which catalyzes the formation of prostaglandins and thromboxane from arachidonic acid. By inhibiting this pathway, an alternate pathway becomes more active, in which 5-lipo-oxygenase enzyme converts arachidonic acid to the potent inflammatory and bronchoconstrictor mediators: leukotrienes, LTC<sub>4</sub>, LTD<sub>4</sub>, and LTE<sub>4</sub> (FIGURE 3).

Traditionally, therapy included avoidance of aspirin and nonsteroidal anti-inflammatory drugs, and in rare cases, desensitization. With the recent availability of leukotriene modifiers, both inhibitors of leukotriene synthesis (such as zileuton) and LTD<sub>4</sub> receptor antagonists (such as zafirlukast and montelukast) have become the drugs of choice for treating

### How aspirin and nonsteroidal anti-inflammatory drugs may worsen asthma



**FIGURE 3.** Aspirin and nonsteroidal anti-inflammatory drugs inhibit cyclo-oxygenase activity, diverting arachidonic acid to the alternate lipo-oxygenase pathway, which converts arachidonic acid to potent bronchoconstrictor mediators: leukotrienes, LTC4, LTD4, and LTE4. Lipo-oxygenase inhibitors and receptor-level antagonists may counteract the effect.

**Methotrexate complications: infections, pneumonitis, fibrosis, asthma**

aspirin-induced asthma. This, in a way, represents the first specific therapy available for this type of asthma.

#### Methotrexate

Methotrexate is now commonly used in the treatment of rheumatoid arthritis and other connective tissue disorders. The anti-inflammatory dose of methotrexate is much lower than the traditional antineoplastic dose and is associated with different side effects.

Pulmonary complications seen in patients who use anti-inflammatory doses of

methotrexate include opportunistic infections (eg, pneumonitis due to *Pneumocystis carinii*, *Aspergillus*, *Histoplasma*, *Nocardia*, *Legionella*, or cytomegalovirus), acute interstitial pneumonitis, interstitial fibrosis, and asthma. In methotrexate pneumonitis, onset of dyspnea, fever, and cough is usually sub-acute.

Laboratory and radiologic findings include hypoxemia, a restrictive pattern on pulmonary function tests, and diffuse bilateral interstitial infiltrates. High-resolution computed tomographic scans of the chest





may demonstrate ground glass infiltrates. Bronchoalveolar lavage demonstrates lymphocytosis with a variable CD4/CD8 ratio. Transbronchial biopsies may show weakly formed granulomas.

The main challenge to the diagnosis is to exclude infection. This can be done on clinical grounds (absence of fever and leukocytosis, and sputum culture findings), but usually requires bronchoalveolar lavage.

Corticosteroid therapy and withdrawal of methotrexate usually halts pulmonary complications, and the prognosis is usually good.<sup>3,4</sup>

## ■ CHEMOTHERAPEUTIC AND IMMUNOSUPPRESSIVE DRUGS

### Bleomycin

Bleomycin is deposited in the skin and lungs; therefore, the most serious side effects are seen in the skin (ulceration) and the lungs (interstitial fibrosis).<sup>4</sup> These two organs are relatively deficient in the enzyme that inactivates bleomycin. Once within its target cells, the drug has the ability to cleave DNA, possibly by generating oxygen radicals. This could be the reason why high-concentration oxygen administration and radiation therapy augment the toxicity of bleomycin.<sup>2</sup> Life-threatening pneumonitis, which can progress to interstitial pulmonary fibrosis in up to 10% of patients, is the major limitation of bleomycin therapy.

Clinical variables that may increase the risk of developing bleomycin lung toxicity include higher cumulative doses (> 500 mg/m<sup>2</sup>), high fractions of inspired oxygen, radiation therapy, and use of other cytotoxic drugs. Symptoms include fever, cough, dyspnea on exertion, and substernal and pleuritic pain.

Radiographic abnormalities usually consist of bilateral bibasilar, reticular, reticulonodular, or fine nodular opacities, often showing a peripheral distribution.<sup>2</sup>

The vital capacity and diffusing capacity of the lungs for carbon monoxide have been used to monitor patients receiving the drug. There are no large studies demonstrating the efficacy of therapy for bleomycin-induced lung injury in humans, but cessation of the drug and corticosteroids are usually used.

Supplemental oxygen use should be minimized.

### Mitomycin-C

Mitomycin-C is an antineoplastic alkylating agent. Incidence of pulmonary toxicity is about 5%. Pulmonary disorders that have been described with mitomycin-C include bronchospasm, acute pneumonitis, hemolytic-uremic-like syndrome, acute lung injury, chronic interstitial pneumonitis, and pleural disease.

Pretreatment with corticosteroids may lower the incidence of lung toxicity but does not eliminate the development of lung injury.<sup>13</sup>

### Busulfan

Busulfan is an alkylating agent used in myeloproliferative disorders. Symptomatic pulmonary injury is estimated to occur in fewer than 5% of patients.

Patients present with cough and progressive dyspnea on exertion. Fever and weight loss may also occur. The interval between initiation of therapy and onset of pulmonary symptoms may be more than 4 years.<sup>14</sup> The chest radiograph usually shows a bilateral reticular or reticulonodular pattern.

### Cyclophosphamide

The incidence of cyclophosphamide-induced pulmonary toxicity is generally less than 1%. Patients complain of nonproductive cough, dyspnea, fever, and fatigue. Bilateral reticular or nodular diffuse opacities are seen on the chest x-ray. Histopathologic findings are nonspecific.

### Nitrosourea drugs

Nitrosourea drugs include **carmustine** (BCNU), **lomustine** (CCNU), and **semustine** (methyl CCNU). Carmustine is the most widely used and is associated with high risk of pulmonary toxicity. Up to 25% of patients who receive carmustine develop pulmonary fibrosis within 36 months (early-onset pulmonary fibrosis). Lung fibrosis is especially likely with high doses (> 1,500 mg/m<sup>2</sup>). Carmustine may also cause a late-presenting form of lung fibrosis (between 8 and 20 years after carmustine treatment).<sup>15</sup>

**Bleomycin toxicity is greater with higher doses, higher FIO<sub>2</sub>, radiation, other cytotoxic drugs**

### Others

**Procarbazine** causes acute interstitial lung disease with peripheral and pulmonary eosinophilia and pleural effusions.

**Melphalan**-induced lung toxicity is seen in fewer than 5% of patients receiving melphalan. Interstitial pneumonitis and fibrosis and pleural effusion are the usual manifestations.

**Paclitaxel** is a relatively new antineoplastic drug which may cause hypersensitivity reactions, characterized by dyspnea, bronchospasm, and pneumonitis.<sup>16</sup>

### ■ ANTIMICROBIAL DRUGS

**Nitrofurantoin** is the most commonly reported antimicrobial drug causing pulmonary toxicity. There are two distinct presentations: acute, developing hours to days after initiation of treatment; and chronic and insidious, becoming manifest after weeks to years of continuous therapy.

The acute form is a hypersensitivity reaction. The most frequently reported symptoms are fever, dyspnea, irritating cough, and rash. Chest pain and cyanosis may also occur. Radiographic manifestation consists of a diffuse reticular pattern with some basilar predominance. Eosinophilia is the most commonly reported laboratory finding in the acute form.<sup>17,18</sup>

The chronic form represents direct tissue damage from oxidants. Symptoms are dyspnea, dry cough, and fatigue. Fever is uncommon in the chronic form. High-resolution computed tomography may demonstrate a predominantly subpleural or peribronchovascular distribution of fibrosis.

**Sulfasalazine**, used in the treatment of inflammatory bowel disease, has been reported to cause interstitial pneumonitis, fibrosis, and bronchiolitis obliterans organizing pneumonia. The clinical presentation consists of dry cough, progressive dyspnea, and fever, often associated with skin rash and blood eosinophilia 1 to 6 months after initiation of treatment.<sup>4</sup>

**Tetracycline** and **minocycline** have been reported to cause lung disease resembling simple pulmonary eosinophilia.<sup>2</sup> **Sulfonamides**, **para-aminosalicylic acid**, **ethambutol**, **ampi-**

**cillin**, and **cephalosporins** have been associated with an eosinophilic lung reaction similar to that seen with sulfasalazine and tetracyclines.

**Griseofulvin**, **isoniazid**, **aminosalicylic acid**, **penicillin**, **streptomycin**, **sulfonamides**, and **tetracycline** are also capable of producing a drug-induced lupus syndrome.<sup>19</sup>

### ■ APPETITE SUPPRESSANTS AND PULMONARY HYPERTENSION

Several reports in recent years suggested an increased risk of pulmonary hypertension with appetite suppressant medications for treatment of obesity.<sup>20,21</sup> The association of these drugs with both primary and secondary pulmonary hypertension increases with increased duration of anorexigenic use, especially fenfluramine and primary pulmonary hypertension.<sup>6,21</sup>

The exact pathogenic events are not known. However, data from patients showed an increase in plasma 5-hydroxytryptamine (5-HT, serotonin) levels,<sup>22</sup> and an increased release of 5-HT from platelets.<sup>20,22</sup> It appears that these agents release 5-HT from storage sites or inhibit reuptake of 5-HT, or both.<sup>2</sup> It has been shown that 5-HT causes pulmonary vasoconstriction and produces both hyperplasia and hypertrophy of isolated cultured pulmonary artery smooth muscle cells.<sup>23</sup> Thus, appetite suppressants which affect the release or uptake of 5-HT may be trigger factors that lead to pulmonary hypertension. Another possible mechanism is through nitric oxide.<sup>24</sup>

### ■ MISCELLANEOUS DRUGS

**Antidepressant and antipsychotic agents** and **hydrochlorothiazide** have been associated with permeability (noncardiogenic) pulmonary edema.<sup>2</sup>

**Ergotamine** and **bromocriptine** have been reported to cause pulmonary fibrosis and pleural disease.<sup>2</sup>

The tocolytic beta-mimetic agents **terbutaline**, **ritodrine**, and **isoxsuprine** have been implicated in the development of permeability pulmonary edema. The incidence of this syndrome is higher in women with twin gestations. Treatment in almost all cases is discon-

**Nitrofurantoin toxicity can be acute or chronic**



tinuation of tocolytic therapy, diuresis, and administration of oxygen.<sup>25</sup>

**Zafirlukast and related leukotriene antagonists** have been associated with certain manifestations of the Churg-Strauss syndrome in the form of pulmonary infiltrates, cardiomyopathy, and eosinophilia.<sup>26</sup> It is not clear, however, whether these medications

actually trigger Churg-Strauss reactions or whether they unmask a preexisting infiltrative eosinophilic disorder as the glucocorticoid therapy is withdrawn.

**Pentamidine**, which is the treatment of *P carinii* pneumonia, may cause various pulmonary complications including cough, bronchospasm, and pneumothorax.<sup>27,28</sup>

## ■ REFERENCES

- Rosenow EC. The spectrum of drug-induced pulmonary disease. *Ann Intern Med* 1972; 77:977-991.
- Pulmonary disease caused by toxins, drugs, and irradiation. In: Fraser RS, Müller NL, Colman N, Pare PD, editors. *Diagnosis of diseases of the chest*. Philadelphia: W.B. Saunders, 1999:2517-2592.
- Rosenow EC. Drug-induced pulmonary disease. *Dis Mon* 1994; 40:253-310.
- Dweik RA, Ahmad M. Drug-induced pulmonary disease. In: Baum GL, Celli JDC, Karlinsky JB, editors. *Textbook of pulmonary diseases*, 6th ed. Philadelphia: Lippincott-Raven Publishers, 1998:477-490.
- Miller WT. Pleural and mediastinal disorders related to drug use. *Semin Roentgenol* 1995; 30:35-48.
- Rich S, Rubin L, Walker AM, Schneeweiss S, Abenheim L. Anorexigens and pulmonary hypertension in the United States: results from the surveillance of the North American pulmonary hypertension. *Chest* 2000; 117:870-874.
- Schur PH, Rose BD. Drug-induced lupus. UpToDate in pulmonary and critical care medicine [on CD-ROM]. American Thoracic Society; v.8.1, 2000.
- Meeker DP, Wiedemann HP. Drug-induced bronchospasm. *Clin Chest Med* 1990; 11:163-175.
- Copper JAD Jr. Drug-induced lung disease. *Adv Intern Med* 1997; 42:231-268.
- Chan ED, King TE. Amiodarone pulmonary toxicity. UpToDate in pulmonary and critical care medicine [on CD-ROM]. American Thoracic Society; v.8.1, 2000.
- Israilli ZH, Hall WD. Cough and angioneurotic edema associated with angiotensin-converting enzyme inhibitor therapy. A review of the literature and pathophysiology. *Ann Intern Med* 1992; 117:234-242.
- Malini PL, Strocchi E, Zanardi M, et al. Thromboxane antagonism and cough induced by angiotensin-converting-enzyme inhibitor. *Lancet* 1997; 350:15-18.
- Chan ED, King TE. Mitomycin-C pulmonary toxicity. UpToDate in pulmonary and critical care medicine [on CD-ROM]. American Thoracic Society; v.8.1, 2000.
- Russi EW. Busulfan-induced pulmonary injury. UpToDate in pulmonary and critical care medicine [on CD-ROM]. American Thoracic Society; v.8.1, 2000.
- O'Driscoll R. Nitrosourea (carmustine)-induced pulmonary injury. UpToDate in Pulmonary and Critical Care Medicine [on CD-ROM]. American Thoracic Society; v.8.1, 2000.
- Goldberg HL, Vannice SB. Pneumonitis related to treatment with paclitaxel. *J Clin Oncol* 1995; 13:534-535.
- De Zeeuw J, Schumacher J, Werninghous GS, Gillishen AG. Nitrofurantoin-induced pulmonary injury. UpToDate in pulmonary and critical care medicine [on CD-ROM]. American Thoracic Society; v.8.1, 2000.
- Cameron RJ, Kolbe J, Wilsher ML, Lambie N. Bronchiolitis obliterans organizing pneumonia associated with the use of nitrofurantoin. *Thorax* 2000; 55:249-251.
- Christodoulou CS, Emmanuel P, Ray RA, Good RA, Schnapf BM, Cawkwell GD. Respiratory distress due to minocycline-induced pulmonary lupus. *Chest* 1999; 115:1471-1473.
- Voelkel NF. Appetite suppressants and pulmonary hypertension. *Thorax* 1997; 52:S63-S67.
- Abenheim L, Moride Y, Brenot F, et al. Appetite-suppressant drugs and the risk of pulmonary hypertension. *N Engl J Med* 1996; 335:609-616.
- Herve P, Launay JM, Scrobohaci ML, et al. Increased plasma serotonin in primary pulmonary hypertension. *Am J Med* 1995; 99:249-254.
- Lee SL, Wang WW, Lanzillo JJ, Fanburg BL. Serotonin produces both hyperplasia and hypertrophy of bovine pulmonary artery smooth muscle cells in culture. *Am J Physiol* 1994; 266:L46-L52.
- Archer SL, Djaballah K, Humbert M, et al. Nitric oxide deficiency in fenfluramine- and dexfenfluramine-induced pulmonary hypertension. *Am J Respir Crit Care Med* 1998; 158:1061-1067.
- Pisani RJ, Rosenow III EC. Pulmonary edema associated with tocolytic therapy. *Ann Intern Med* 1989; 110:714-718.
- Wechsler ME, Garpestad E, Flier SR, et al. Pulmonary infiltrates, eosinophilia, and cardiomyopathy following corticosteroid withdrawal in patients with asthma receiving zafirlukast. *JAMA* 1998; 279:455-457.
- Gearhart MO, Bhutani MS. Intravenous pentamidine-induced bronchospasm. *Chest* 1992; 102:1891-1892.
- Katzman M, Meada W, Iglar K, Rachlis A, Berger P, Chan CK. High incidence of bronchospasm with regular administration of aerosolized pentamidine. *Chest* 1992; 101:79-81.

ADDRESS: Raed A. Dweik, MD, Department of Pulmonary and Critical Care Medicine, A90, The Cleveland Clinic Foundation, 9500 Euclid Avenue, Cleveland, OH 44195; e-mail [dweikr@ccf.org](mailto:dweikr@ccf.org).