



LI-LING LIM, MBBS

Department of Neurology,  
The Cleveland Clinic

RICHARD PRAYSON, MD

Department of Anatomic Pathology,  
The Cleveland Clinic

ROBERT SHIELDS, MD

Department of Neurology,  
The Cleveland Clinic

# A 45-year-old woman with acute-onset weakness in the intensive care unit

**A** 45-YEAR-OLD-WOMAN with long-standing asthma presented with cough, dyspnea, and chest tightness. She had been using inhalers and theophylline at home, but she was not taking steroids regularly.

The patient was tachypneic, cyanotic, hypoxemic, hypercapnic, and acidotic. The physicians in the emergency department diagnosed status asthmaticus, intubated her, and started intravenous methylprednisolone 100 mg every 6 hours, intravenous theophylline, and aerosol bronchodilators.

A chest radiograph showed a right perihilar infiltrate suggestive of pneumonia. Sputum cultures grew *Haemophilus influenzae* and *Staphylococcus aureus*; urine cultures grew *Enterococcus* species.

## Hospital course

The patient was admitted to the intensive care unit. She received multiple antibiotics (azithromycin, cefazolin, gentamicin, vancomycin, ciprofloxacin, ticarcillin clavulanate, dicloxacillin). She also received lorazepam and midazolam intravenously for sedation, insulin by sliding scale, famotidine, sucralfate, captopril, lisinopril, and digoxin. Neuromuscular blocking agents were not used.

The hospital course was complicated by gastrointestinal bleeding requiring transfusion; tension pneumothorax requiring a chest tube after an attempt to place a central venous line; and mental status changes likely related to multiple factors, including hypoxia, hypercapnia, and sedating drugs. The patient's mental status gradually improved, and she was extubated 2 weeks after the onset of her illness without difficulty.

At that time, the patient was noted to

have marked muscle wasting and diffuse weakness of her extremities, distally more than proximally: her muscle strength was graded 3 to 4 on a scale of 5 proximally and 0 to 2 distally. Her sensory systems and reflexes were normal. The muscles of the neck and respiratory system were not weak, and there were no other significant findings on neurologic examination.

## ■ DIAGNOSIS

### 1 What is the most likely diagnosis?

- ☐ An electrolyte disturbance (eg, hypokalemia, hypercalcemia, hypermagnesemia, hypophosphatemia)
- ☐ Guillain-Barré syndrome
- ☐ Spinal cord injury
- ☐ Stroke
- ☐ Critical illness myopathy
- ☐ Critical illness polyneuropathy

**Electrolyte disturbances** and other metabolic derangements are possible and should be looked for.

**Guillain-Barré syndrome** is unlikely. Although the patient had symmetric weakness, her reflexes were normal and she did not have sensory disturbances, autonomic dysfunction, or involvement of the extraocular or facial muscles.

**Spinal cord disease.** Acute myelopathy can occur after a difficult intubation, especially if the patient has underlying cervical arthropathy, ischemia, hemorrhage, or vitamin B<sub>12</sub> deficiency. This patient did not have upper motor neuron signs, a sensory level, or sphincter dysfunction, which would have suggested spinal cord disease.

The patient  
had muscle  
wasting and  
diffuse  
weakness of  
her extremities

TABLE 1

### Differential diagnosis of weakness of acute onset in intensive care

#### Metabolic, nutritional, and electrolyte disturbances, drugs and toxins

Diabetes, hypothyroidism, chronic renal and liver disease  
Vitamin B<sub>12</sub> deficiency, chronic alcohol abuse  
High or low potassium, calcium, or magnesium; hypophosphatemia  
Toxic neuropathies and myopathies

#### Central nervous system disease (brain and spinal cord)

Acute transverse myelitis  
Spinal stenosis  
Spinal cord injury, compression, infarct, or hemorrhage  
Stroke

#### Anterior horn cell disease

Motor neuron disease  
Enterovirus-related polio syndrome (eg, in immunocompromised patients)  
Paraneoplastic syndrome

#### Radiculopathy

Underlying malignancy or connective tissue disease  
Spondyloarthropathy  
Diabetic lumbosacral polyradiculopathy

#### Peripheral neuropathy

Critical illness polyneuropathy  
Guillain-Barré syndrome  
Drugs or toxins  
Paraneoplastic syndrome  
Connective tissue disease  
Thiamine deficiency  
Metabolic diseases (listed above)  
Acute intermittent porphyria

#### Neuromuscular junction disease

Paralytic agents  
Myasthenia gravis  
Hypermagnesemia  
Botulism

#### Myopathy

Critical illness myopathy  
Rhabdomyolysis  
Drugs or toxins  
Inflammatory myopathies (related to vasculitides or infection)  
Periodic paralyses (hypokalemic, potassium sensitive)  
Myotonia dystrophica  
Metabolic myopathies (eg, storage diseases, acid maltase deficiency, mitochondrial disease)

ADAPTED FROM RAPS EC, BIRD SJ, HANSEN-FLASCHEN J. PROLONGED MUSCLE WEAKNESS AFTER NEUROMUSCULAR BLOCKADE IN THE INTENSIVE CARE UNIT. CRIT CARE CLIN 1994; 10:799–813.

**Stroke** typically presents as an acute focal neurologic deficit with an upper motor neuron pattern of weakness. This patient had generalized weakness of the lower motor neuron type without significant cerebral or brain stem dysfunction.

**Critical illness myopathy and polyneuropathy** can both present with acute-onset weakness in the critical care setting. Critical illness myopathy has been reported in patients with status asthmaticus who have received steroids in high doses and, frequently, nondepolarizing neuromuscular blocking agents. Critical illness polyneuropathy occurs in sepsis and multiorgan failure, with clinical features of sensory involvement, diminished deep tendon reflexes, and encephalopathy (not usually seen in critical illness myopathy).

The presentation in this patient is consistent with critical illness myopathy with or without polyneuropathy (both may coexist<sup>1</sup>), albeit with atypical features: she did not have difficulty weaning from the ventilator, nor did she receive neuromuscular blocking agents. While the predominantly distal pattern of weakness suggested a peripheral neuropathy, her deep tendon reflexes were intact and there was no sensory involvement, as would be expected.

#### ■ APPROACH TO ACUTE WEAKNESS IN THE CRITICALLY ILL

Acute weakness in the critically ill is common. Multiple factors may contribute, such as:

- Long-standing disuse with muscle atrophy
- Underlying metabolic, nutritional, or toxic abnormalities (eg, diabetes, thyroid dysfunction, vitamin B<sub>12</sub> deficiency, electrolyte disturbances, or drugs such as corticosteroids or neuromuscular blocking agents)
- Sepsis
- Multiorgan failure.

In addition, severe illness can exacerbate or precipitate neuromuscular diseases such as Guillain-Barré syndrome, myasthenia gravis, and steroid myopathy.

#### Important information in the history

In approaching a patient with acute-onset weakness, one should determine if the patient



has any of the following:

- An underlying metabolic disease
- Exposure to drugs or toxins (including alcohol)
- A family history of neuromuscular disease.

After ruling out correctable metabolic, nutritional, and toxic causes of acute weakness, a systematic approach can help in determining the location of the problem (TABLE 1).<sup>2</sup>

### Is the weakness diffuse or focal?

In general, systemic processes such as deconditioning, metabolic disturbances, or nutritional deficiencies present with diffuse weakness with clinical features of the underlying disorder such as stigmata of chronic liver disease, chronic renal failure, or hypothyroidism.

Alternatively, the same systemic process can have a more focal pattern such as in myopathy (typically proximal weakness such as in hypothyroidism, toxic myopathies, critical illness myopathy), peripheral neuropathy (typically distal sensory or motor deficits such as in vitamin B<sub>12</sub> and vitamin E deficiency, chronic alcohol abuse, diabetes, chronic renal failure, toxic neuropathies, critical illness polyneuropathy), and radiculopathy (such as diabetic lumbosacral polyradiculopathy—also known as diabetic amyotrophy).

Nutritional deficiencies can also cause distinctive syndromes (eg, subacute combined degeneration of the cord in vitamin B<sub>12</sub> deficiency, cerebellar syndrome in vitamin E deficiency).

### Is it an upper or lower motor neuron problem?

**Disorders of the central nervous system** present with upper motor neuron signs: typically, increased tone, brisk deep tendon reflexes, and upgoing plantar responses. Specific disorders may have distinctive findings, such as:

- Stroke—hemisensory or motor deficits, cranial nerve dysfunction, language deficits
- Spinal cord disease—sensory level, paraparesis, bladder or bowel dysfunction.

**Lower motor neuron syndromes** include diseases of the anterior horn cells, nerve roots, peripheral nerves, neuromuscular junction, and muscles. These may present with wasting, reduced tone, diminished deep tendon reflex-

es, and normal plantar responses. Higher cortical function and cranial nerve testing are normal unless there are coexisting abnormalities.

Certain features may suggest the location:

- Fasciculations—anterior horn cell disease
- Radicular pain, dermatomal sensory loss, and myotomal weakness—radiculopathy
- Symmetric, distal weakness, often with diminished deep tendon reflexes, and peripheral sensory deficits—peripheral neuropathy
- Fatigable diffuse and extraocular involvement—neuromuscular junction, eg, in generalized myasthenia gravis
- Proximal weakness with normal sensory examination—most myopathies
- Delayed relaxation—myotonia dystrophica.

Some diseases have a combination of both upper and lower motor neuron signs. Examples are amyotrophic lateral sclerosis and vitamin B<sub>12</sub> deficiency (which causes peripheral neuropathy and subacute combined degeneration of the spinal cord). In addition, diseases can occur in combination, such as stroke in a diabetic patient with peripheral neuropathy.

## ■ DIAGNOSTIC TESTS

### 2 What diagnostic tests would be useful in this patient?

- ☐ Serum electrolytes (potassium, calcium, magnesium, phosphate) and glucose
- ☐ Creatine kinase
- ☐ Urine myoglobin
- ☐ Cerebrospinal fluid analysis
- ☐ Imaging studies of the spinal cord
- ☐ Electrodiagnostic examination
- ☐ Muscle and nerve biopsy

Diagnostic testing should be approached on the basis of the clinical findings, as outlined above.

**Electrolytes**, blood glucose levels, and renal and liver function tests should be measured if there is clinical evidence of metabolic disease. Potassium derangements occur in renal failure, with diuretic use, and in the periodic paralyses.

This patient's blood work revealed poly-

**Diagnostic testing should be guided by the clinical findings**



morphonuclear leukocytosis. Her lowest hemoglobin concentration was 8.8 mg/dL (normal 12.0–16.0). Her serum electrolyte and glucose levels were not significantly deranged.

**Creatine kinase** and other muscle enzymes should be measured if myopathy is suspected. Creatine kinase (MM fraction) leaks into the blood when skeletal muscles are injured and is a nonspecific but sensitive indicator of muscle disease.

This patient's creatine kinase concentration was 2,452 U/L (normal 30–220).

**Urine myoglobin** should be checked if rhabdomyolysis is suspected, especially in acute renal failure.

**Cerebrospinal fluid analysis** may show increased protein with a normal cell count in Guillain-Barré syndrome, abnormal cytology in malignancy, and inflammatory cells in transverse myelitis.

This patient underwent a lumbar puncture. The puncture was traumatic, but the findings were unremarkable.

**Imaging studies** (MRI or CT) of the brain or spine may be indicated if intracranial or spinal cord disease is suspected. MRI of the spine is also useful in evaluating nerve root compression.

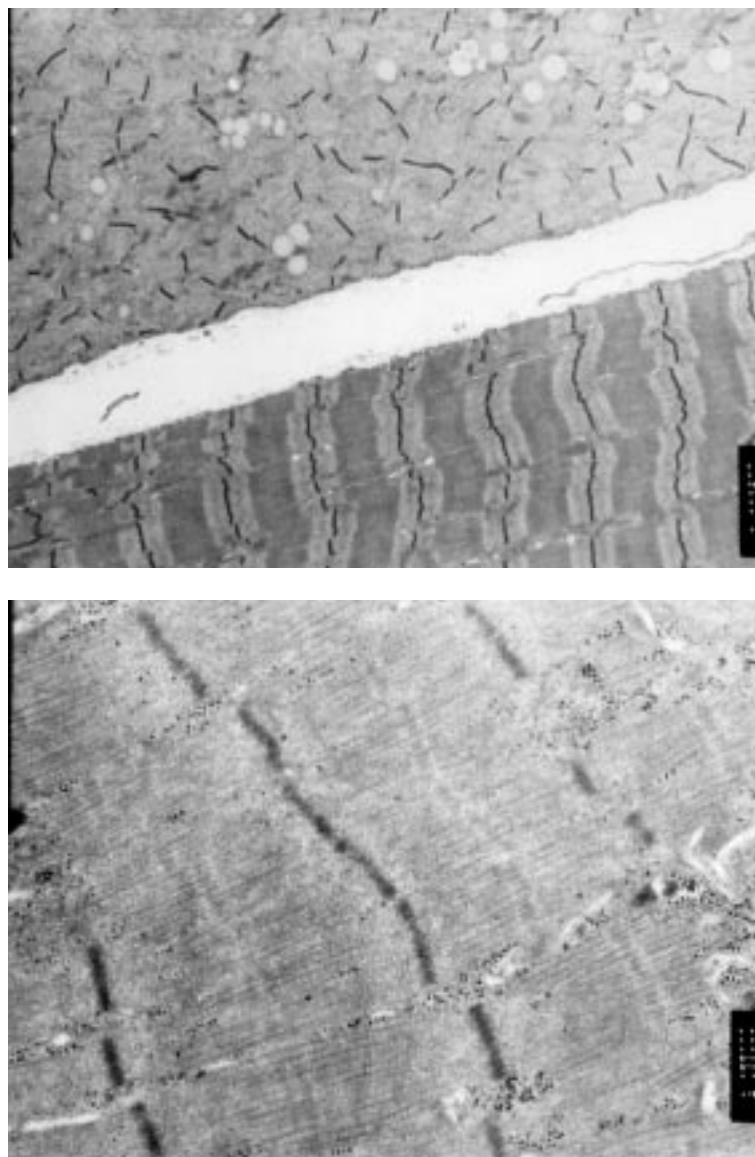
The patient underwent MRI of the cervical spine, which showed no significant abnormalities.

**The electrodiagnostic examination (EMG)** helps differentiate diseases of the anterior horn cells, nerve roots, peripheral nerves, neuromuscular junction, and muscle. It consists of nerve conduction studies and the needle electrode examination.

Nerve conduction studies measure the amplitude and conduction characteristics of the sensory and motor responses. Demyelinating neuropathies (eg, Guillain-Barré syndrome) may block or significantly slow conduction. Axonal-loss neuropathies (eg, critical illness neuropathy) reduce the amplitude of the sensory and motor responses with normal conduction velocities. Neuromuscular transmission can be assessed with repetitive nerve stimulation tests; defects are seen in myasthenia gravis, botulism, and with neuromuscular blocking agents.

The needle electrode examination mea-

## Critical illness myopathy



**FIGURE 1.** Top, low-magnification electron micrograph of muscle in critical illness myopathy. The muscle fiber on the bottom of the picture shows a normal banding pattern. The muscle fiber on top is marked by myofibrillar disarray with an abnormal banding pattern. Bottom, higher magnification electron micrograph of the abnormal muscle fiber showing loss of the normal myofibril banding pattern due to loss of myosin filaments.

sures changes in motor unit potentials and is helpful in differentiating neuropathic, myopathic, and neurotransmission disorders.

The patient underwent an electrodiagnostic study. The nerve conduction study showed



TABLE 2

## Comparison of critical illness myopathy and polyneuropathy

	CRITICAL ILLNESS MYOPATHY	POLYNEUROPATHY
Clinical features	Pure motor deficits	Sensory and motor deficits Diminished deep tendon reflexes
Risk factors	Neuromuscular blocking agents Steroids	Sepsis Multiorgan failure
Creatine kinase	Normal or mildly elevated	Normal
Sensory nerve conduction	Normal	Low amplitude
Motor nerve conduction	Low amplitude	Low amplitude
Motor unit morphology and recruitment	Myopathic	Neurogenic
Muscle excitability	Absent or decreased	Normal
Pathology	Patchy myosin loss Minimal necrosis	Axon loss neuropathy Denervation changes in muscle
Recovery	Rapid	Slow

Electro-  
diagnostic  
testing helps  
differentiate  
lower motor  
neuron  
diseases

normal sensory and low-amplitude motor responses; the needle electrode examination showed fibrillation potentials (seen typically in active denervation and also in necrotizing myopathies) and myopathic motor unit potentials.

**Muscle and nerve biopsy** may demonstrate changes of neuromuscular disease or systemic disease such as vasculitis, amyloidosis, and granulomatous disease. Furthermore, characteristic features can help distinguish between a neuropathic and a myopathic disorder. Electron microscopy gives ultrastructural information useful in diagnosing congenital and mitochondrial myopathies. Specific enzyme assays can further delineate the mitochondrial cytopathies and identify specific deficiencies in the metabolic myopathies (eg, glycogenoses, lipid disorders).

#### ■ FINAL DIAGNOSIS: CRITICAL ILLNESS MYOPATHY

The patient's CK elevation and electrodiagnostic findings suggested a myopathy of the necrotizing type, consistent with critical illness myopathy. Other necrotizing myopathies include the inflammatory myopathies (der-

matomyositis, polymyositis), rhabdomyolysis, the muscular dystrophies, and certain toxic myopathies (due to alcohol, cholesterol-lowering agents, or propofol). Myonecrosis is not a typical feature of steroid myopathy.

The patient underwent a muscle biopsy of the left quadriceps muscle, which showed prominent muscle fiber atrophy with scattered degenerating and regenerating muscle fibers. There was no evidence of inflammation, vasculitis, granulomas, amyloid, or ragged red fibers (seen in mitochondrial disease). Electron microscopy showed normal mitochondria, prominent myofilament disruption, and changes suggestive of loss of myosin filaments (FIGURE 1). The loss of myosin filaments was consistent with the clinical diagnosis of critical illness myopathy. Not found was type IIb muscle fiber atrophy, typically seen in steroid myopathy.

#### ■ CRITICAL ILLNESS MYOPATHY

This case illustrates a common problem in intensive care: acute-onset, reversible weakness, which may sometimes be accompanied by encephalopathy. While there were atypical features, other features helped to define the

## Critical illness myopathy and polyneuropathy can coexist

underlying neuromuscular problem as critical illness myopathy: the clinical picture (acute onset of pure motor deficits associated with steroid use in a critically ill patient, absence of any underlying metabolic disorder, and relatively rapid resolution), electrophysiologic findings (necrotizing myopathic changes) and histopathologic evidence (myosin loss).

Critical illness myopathy can be difficult to differentiate from critical illness polyneuropathy (TABLE 2),<sup>3</sup> and both disorders can occur in the same patient, giving clinical features of both.

These disorders are common. In a prospective study,<sup>4</sup> 62% of patients with difficulty weaning from the ventilator were found to have a neuromuscular disorder. A subsequent study<sup>1</sup> found the most common cause to be myopathy, with features consistent with critical illness myopathy in 42%. Polyneuropathy occurred in 13% of the patients.

Critical illness myopathy or neuromyopathy associated with status asthmaticus was reported as early as 1977,<sup>5,6</sup> and has been called “acute necrotizing myopathy of intensive care,” “acute quadriplegic myopathy,” “thick filament myopathy,” and “acute myopathy with selective loss of myosin filaments.” The patients initially described were mechanically ventilated and received intravenous corticosteroids in high doses and other drugs such as aminophylline, pancuronium, vecuronium, and antibiotics.

**Features of critical illness myopathy include:**

- Generalized weakness, which may include respiratory muscles and may be associated with difficulty weaning from the ventilator
- Normal sensory and autonomic function
- Normal or reduced deep tendon reflexes, with rare cranial nerve involvement
- Normal or mildly elevated creatine kinase levels<sup>6</sup>
- Normal sensory responses and reduced motor amplitudes on nerve conduction studies
- Persistent neuromuscular blockade (from the effects of paralytic agents) with decrement on repetitive nerve stimulation studies
- Abnormalities on needle electrode examination, which may include myopathic

motor unit potentials,<sup>7</sup> fibrillation potentials, and inexcitability of muscle to direct electrical stimulation<sup>8</sup>

- Necrotizing myopathy with selective loss of thick (myosin) filaments on muscle biopsy, with no evidence of denervation.<sup>9</sup>

Recovery has been reported to range from about 2 weeks to 6 months from onset. The prognosis depends on the patient's age and the underlying illness.

**Pathogenesis.** Critical illness myopathy is likely multifactorial and may be partly related to neuromuscular toxicity from drugs such as corticosteroids, aminophylline, and paralytic agents. Neuromuscular blocking agents have been implicated in prolonged weakness,<sup>1,5,6,10</sup> possibly by persistent disruption of synaptic transmission or a toxic myopathic effect. The prolonged drug effects occur particularly in patients with impaired hepatic or renal function. Prolonged use of intravenous corticosteroids at high doses and paralytic agents is discouraged,<sup>6</sup> especially when there is evidence of renal or hepatic impairment.

## ■ CRITICAL ILLNESS POLYNEUROPATHY


Critical illness polyneuropathy was first described in patients with sepsis and multiorgan failure who developed severe sensorimotor polyneuropathy.<sup>11</sup> It is the most common cause of neuropathy in the intensive care setting.

**Features of critical illness polyneuropathy** include predominant distal limb weakness, sensory involvement, and diminished deep tendon reflexes. Encephalopathy usually precedes the polyneuropathy. Weaning from the ventilator may also be difficult.<sup>12</sup> Patients gradually improve if they recover from the underlying illness, though the mortality rate in sepsis, multiorgan failure, and critical illness polyneuropathy is high.

The electrodiagnostic features are consistent with an axonal neuropathy.<sup>13</sup> Nerve conduction studies show reduced motor and sensory response amplitudes.


Muscle biopsy also shows changes of axonal neuropathy<sup>14</sup> without significant demyelination or inflammation.

**Pathogenesis.** The cause of critical illness polyneuropathy is unknown, but it is presum-



ably related to the combined effects of sepsis and multiple organ failure. Microcirculatory disturbances have been postulated to affect the peripheral nerves and other organ systems in the sepsis syndrome.

## ■ CASE CONTINUED

The patient recovered gradually and was able to walk using a walker. She was discharged to a rehabilitation facility 3 weeks after the initial presentation. An examination 3 weeks after discharge found her to be stronger, nearly normal. 

## ■ REFERENCES

1. Lacomis D, Petrella JT, Giulani MJ. Causes of neuromuscular weakness in the intensive care unit: a study of ninety-two patients. *Muscle Nerve* 1998; 21:610–617.
2. Raps EC, Bird SJ, Hansen-Flaschen J. Prolonged muscle weakness after neuromuscular blockade in the intensive care unit. *Crit Care Clin* 1994; 10:799–813.
3. Bird SJ, Rich MM. Neuromuscular complications of critical illness. *Neurologist* 2000; 6:2–11.
4. Spitzer AR, Giancarlo T, Maher L, Awerbuch G, Bowles A. Neuromuscular causes of prolonged ventilator dependency. *Muscle Nerve* 1992; 15:682–686.
5. Lacomis D, Smith TW, Chad DA. Acute myopathy and neuropathy in status asthmaticus: case report and literature review. *Muscle Nerve* 1993; 16:84–90.
6. MacFarlane IA, Rosenthal FD. Severe myopathy after status asthmaticus. *Lancet* 1977; 2:615.
7. Zochodne DW, Ramsay DA, Viera S. Acute necrotizing myopathy of intensive care: electrophysiological studies. *Muscle Nerve* 1994; 17:285–292.
8. Rich MM, Teener JW, Raps EC, Schotland DL, Bird SJ. Muscle is electrically inexcitable in acute quadriplegic myopathy. *Neurology* 1996; 46:731–736.
9. Ramsay DA, Montserrat J, Agusti-Vidal A. A syndrome of acute severe muscle necrosis in intensive care unit patients. *J Neuropathol Exp Neurol* 1993; 52:387–398.
10. Hirano M, Ott BR, Raps EC. Acute quadriplegic myopathy: a complication of treatment with steroids, nondepolarizing blocking agents, or both. *Neurology* 1992; 42:2082–2087.
11. Bolton CF, Gilbert JJ, Hahn AF. Polyneuropathy in critically ill patients. *J Neurol Neurosurg Psychiatry* 1984; 47:1223–1231.
12. Coronel B, Mercatello A, Couturier JC. Polyneuropathy: potential cause of difficult weaning. *Crit Care Med* 1990; 19:486–489.
13. Bolton CF. Electrophysiologic studies of critically ill patients. *Muscle Nerve* 1987; 10:129–135.
14. Zochodne DW, Bolton CF, Gilbert JJ. Polyneuropathy in critical illness: pathologic features. *Ann Neurol* 1985; 18:160–161.

---

ADDRESS: Li-Ling Lim, MD, Department of Neurology, S90, The Cleveland Clinic Foundation, 9500 Euclid Avenue, Cleveland, OH 44195; e-mail [liml@ccf.org](mailto:liml@ccf.org).