

PYNG LEE, MD

Department of Pulmonary and Critical Care Medicine, The Cleveland Clinic

THOMAS R. GILDEA, MD

Department of Pulmonary and Critical Care Medicine, The Cleveland Clinic

JAMES K. STOLLER, MD, MS*

Vice Chairman, Division of Medicine; Head, Section of Respiratory Therapy, Department of Pulmonary and Critical Care Medicine, The Cleveland Clinic

Emphysema in nonsmokers: Alpha 1-antitrypsin deficiency and other causes

ABSTRACT

Nonsmokers with signs of emphysema at an earlier age than is typical for emphysema deserve a workup for one of the less common causes of emphysema, which include alpha 1-antitrypsin deficiency, connective tissue diseases, hypocomplementemic urticarial vasculitis syndrome, intravenous drug use, human immunodeficiency virus infection, and several rare metabolic disorders.

KEY POINTS

The onset of typical, smoking-related emphysema is in the 6th to 8th decades of life, and chest radiography shows changes in the upper lung. In contrast, emphysema due to an uncommon cause tends to have an earlier onset, perhaps even in infancy, and different radiographic distribution of lung damage.

Alpha 1-antitrypsin deficiency is as prevalent as cystic fibrosis but is largely underrecognized. It accounts for most cases of emphysema due to uncommon causes.

Severe alpha 1-antitrypsin deficiency can affect the lungs, liver, and skin. Clinical features that should prompt testing for alpha 1-antitrypsin deficiency include unexplained emphysema, liver disease, and necrotizing panniculitis.

Emphysema with apical and cortical bullae occurs in 12% of HIV-seropositive patients, regardless of whether they have *Pneumocystis carinii* infection.

*The author has indicated that he has received grant or research support from Alpha Therapeutics and that he is a consultant for Baxter Healthcare Corporation.

ALTHOUGH CIGARETTE SMOKING is the most widely recognized cause of emphysema, 10% of patients with emphysema never or rarely smoked. These patients deserve a workup for one of the less common causes of emphysema:

- Alpha 1-antitrypsin deficiency
- Connective tissue disease (cutis laxa, Marfan syndrome, Ehlers-Danlos syndrome)
- Intravenous drug abuse
- Human immunodeficiency virus (HIV) infection
- Hypocomplementemic urticarial vasculitis syndrome
- Malnutrition and several rare metabolic disorders.

We review here the clinical features, diagnosis, and treatment of emphysema due to causes other than cigarette smoking, including genetic risk modifiers and occupational exposures (TABLE 1).¹⁻³

HOW EMPHYSEMA IS CLASSIFIED

Emphysema, one of the three main types of chronic obstructive pulmonary disease along with chronic bronchitis and bronchiectasis, is defined as the abnormal and permanent enlargement of the air spaces distal to the terminal bronchioles, accompanied by destruction of their walls and without obvious fibrosis.⁴

Three morphologic types of emphysema can be distinguished with respect to the acinus, the part of the lung structure beyond the terminal bronchiole⁵:

Centriacinar or centrilobular emphysema affects the central part of the acinus, including

**TABLE 1****Causes of emphysema unrelated to smoking: Clinical features**

CONDITION	CAUSE	ONSET (YEARS)	FEATURES	DISTRIBUTION	THERAPY
Alpha 1-antitrypsin deficiency	Lung damage due to unopposed elastase	35–45	Emphysema, liver disease, panniculitis	Basilar/panacinar	Pooled human plasma antiprotease, alpha 1-antitrypsin
Cutis laxa	Defect of elastin	Neonatal	Premature aging	Panacinar	None
Marfan syndrome	Defect of elastin	Neonatal	Skeletal, cardiac signs, lens subluxation	Apical, with bullae	None
Ehlers-Danlos syndrome	Defect of elastin	Neonatal	Skeletal, skin signs, pseudotumors	Panacinar	None
Intravenous drug abuse	Damage to capillary bed	Under 30	History of drug use, visible tracks	Apical/bullae (heroin, cocaine); basilar/panacinar (methylphenidate, methadone)	Stop drug use
Human immunodeficiency virus infection	Malnutrition, cytokines, decreased glutathione	Under 40	HIV risk factors	Apical, cortical, with bullae	Antiretroviral therapy
<i>Pneumocystis carinii</i> pneumonia	Leukoelastase activity	Under 40	Dyspnea, cough, fever	Cysts; otherwise, no specific picture	Treatment to reverse cysts
Hypocomplementemic urticarial vasculitis syndrome	Humoral	Under 30	Urticaria, arthritis, angioedema; female-male ratio 8:1	Panacinar	Glucocorticoids, dapsone
Malnutrition	Unopposed elastase injury	Under 40	Wasting	Peripheral	Refeeding
Salla disease	Impaired antiproteolysis	Under 35	Retardation, ataxia, nystagmus	Basilar/centriacinar	None
Menke syndrome	Copper accumulation in lung	Neonatal	Emphysema, optic atrophy	Centriacinar	None

the respiratory bronchiole. It is associated with long-standing smoking and predominantly affects the upper lung. Focal emphysema is another form of centriacinar emphysema that occurs in coal workers' pneumoconiosis.

Panacinar or panlobular emphysema involves the entire alveolus uniformly, predominantly affecting the lower half of the lungs. Panacinar emphysema is often seen in patients with severe homozygous alpha 1-antitrypsin deficiency, though pathologic evi-

dence of panacinar and centriacinar emphysema often coexist.⁶

Distal acinar or paraseptal emphysema mainly involves distal structures such as the alveolar ducts and alveolar sacs and typically occurs either subpleurally or adjacent to fibrous interlobular septa. Paraseptal emphysema can lead to apical or giant bullae, which may rupture and cause spontaneous pneumothorax or compress adjacent, normal lung tissue.



Bullae and blebs are other pathologic features of emphysema. Bullae are areas of marked focal dilatation of respiratory air spaces that may result from the coalescence of adjacent areas of emphysema.⁷ Blebs are intrapleural collections of air that arise as a complication of interstitial emphysema in the neonatal period or as a consequence of barotrauma due to mechanical ventilation.⁸

Emphysematous changes that are not emphysema

Lung changes that resemble emphysema may occur in other conditions, as when pulmonary fibrosis or sarcoidosis places traction on air spaces and causes alveolar distension. However, this air space enlargement does not fit the pathologic definition of emphysema, as it is due to fibrosis rather than to destruction of alveolar walls.

■ ALPHA 1-ANTITRYPSIN DEFICIENCY

Alpha 1-antitrypsin deficiency accounts for approximately 3% of cases of chronic obstructive pulmonary disease and causes early-onset emphysema in nonsmokers or minimal smokers.

Alpha 1-antitrypsin deficiency is inherited as an autosomal-codominant disorder, characterized by serum (and hence, lung) levels of alpha 1-antitrypsin far below the laboratory reference range of 20 to approximately 50 $\mu\text{mol/L}$. Normal levels neutralize the activity of neutrophil elastase, a protease that destroys elastin and other connective tissue components in the lung; however, a deficiency of alpha 1-antitrypsin represents an imbalance in favor of neutrophil elastase and, therefore, increases the risk of emphysematous lung destruction.^{9,10} The hypothesis that emphysema arises from an imbalance of elastase and anti-elastase is supported by studies that show that emphysema develops in the lungs of animals instilled with neutrophil elastase, as well as in nonsmokers with low serum and lung levels of alpha 1-antitrypsin.

Patients with alpha 1-antitrypsin deficiency tend to present with emphysema in the 4th to 5th decades of life,^{11,12} and they often present with liver disease as children.^{13,14}

TABLE 2

Threshold alpha 1-antitrypsin serum levels, genotype, and emphysema risk

GENOTYPE*	THRESHOLD SERUM LEVEL, $\mu\text{MOL/L}$ (MG/DL)	EMPHYSEMA RISK COMPARED WITH GENERAL POPULATION
MM [†]	20–50 (150–350)	No increase
MZ [‡]	12–35 (90–210)	No increase
SS	15–33 (100–140)	No increase
MS	18–52 (94–270)	No increase
SZ	8–19 (75–120)	Mildly increased risk
ZZ	2.5–7 (20–45)	High risk
Null-null	0 (0)	Extremely high risk

*M = normal allele; S = dysfunctional allele; Z = deficient allele; null = no detectable serum alpha 1-antitrypsin

[†]Includes all combinations of normal M-family alleles: M1(Val²¹³), M1(Ala²¹³), M2, and M3 alleles

[‡]Includes all combinations of normal M-family alleles with the Z allele

MODIFIED WITH PERMISSION FROM BRANTLY M, NUKIWA T, CRYSTAL RG. MOLECULAR BASIS OF ALPHA 1-ANTITRYPSIN DEFICIENCY. AM J MED 1988; 84:13–31.

Alpha 1-antitrypsin genotype indicates risk level

At least 90 different variants of the alpha 1-antitrypsin gene have been identified. The chief variants or alleles related to emphysema^{15,16} can be classified as:

- Normal (M) allele: normal serum alpha 1-antitrypsin levels with normal protein function; 90% of the US population is homozygous for the normal allele (PI*MM)
- Deficient (Z) allele: serum alpha 1-antitrypsin levels 35% below the average; the most common abnormal allele, carried by 2% to 3% of the white population in the United States
- Dysfunctional (S) allele: serum alpha 1-antitrypsin is present but does not function normally
- Null allele: no detectable serum alpha 1-antitrypsin level, due to a transcriptional or translational abnormality; the least common allele, representing fewer than 1% of all alpha 1-antitrypsin alleles; poses a high risk for emphysema.

A minimum alpha 1-antitrypsin plasma threshold of 11 $\mu\text{mol/L}$ or 80 mg/dL is felt to protect the lung against the development of

2% to 3% of US whites carry the deficient (Z) allele

TABLE 3

Clinical features that raise suspicion of alpha 1-antitrypsin deficiency

Emphysema with onset at an early age (eg, < 55 years)
Emphysema with basilar hyperlucency on chest radiograph
Emphysema in a nonsmoker or minimal smoker
Bronchiectasis
Panniculitis
Family history of unexplained liver disease or panniculitis

emphysema, based on population studies. People with serum levels below this protective threshold and who are thus at higher risk of emphysema include ZZ homozygotes, null-null homozygotes, and approximately 10% of SZ heterozygotes. In contrast, phenotype SS homozygotes and MZ or MS heterozygotes who do not smoke do not appear to be at increased risk for emphysema (TABLE 2).

Estimates of the prevalence of the high-risk alpha 1-antitrypsin ZZ genotype range from 1 in 1,575 to 1 in 5,097 people^{17,18}; based on a US population of 260 million, 80,000 to 100,000 Americans would be expected to have alpha 1-antitrypsin deficiency.

Alpha 1-antitrypsin deficiency is underrecognized

Although alpha 1-antitrypsin deficiency is as prevalent as cystic fibrosis, the condition is largely underrecognized. In a screening of 20,000 blood specimens submitted to the Saint Louis, Missouri, blood bank, only 28 (4%) of 700 people expected to have the ZZ genotype were recognized to have alpha 1-antitrypsin deficiency.¹⁹ In addition, a survey²⁰ reported a mean 7.2-year interval between patients' first symptoms and the initial diagnosis of alpha 1-antitrypsin deficiency. Furthermore, 44% of respondents reported seeing at least three physicians before the diagnosis was made.

Natural history

Our current understanding of the natural history of alpha 1-antitrypsin deficiency is incomplete. Experience shows that, in the first two decades of life, the clinical picture of

ZZ alpha 1-antitrypsin deficiency is dominated by liver dysfunction. Neonatal hepatitis can occur, often resolving spontaneously, but sometimes progressing to cirrhosis and the need for liver transplantation. Emphysema in these patients usually develops in the 4th or 5th decades, though it may develop earlier or later. Recent data suggest that liver disease is common in older patients with the ZZ type who do not develop emphysema earlier in life.

Factors associated with an even more accelerated decline of lung function in these patients include cigarette smoking, bronchodilator responsiveness, and older age. Severe alpha 1-antitrypsin deficiency also confers an increased risk of death due to the effects of both lung and liver disease. The death rate in patients in the National Institutes of Health Registry was 3% per year,²¹ with high rates in patients with more severe airflow obstruction.

Clinical effects, warning signs

Severe alpha 1-antitrypsin deficiency can affect the lungs, liver, and skin. Clinical features that should prompt testing for alpha 1-antitrypsin deficiency include unexplained emphysema, liver disease, and necrotizing panniculitis (TABLE 3).

In the earliest published series,²² 75% of patients with ZZ type alpha 1-antitrypsin deficiency had chronic obstructive pulmonary disease (59% emphysema, 38% chronic bronchitis), 11% had bronchiectasis, and 4% had asthma. In another report, the prevalence of bronchiectasis varied from 2% to 43% and occurred most commonly in lobes with higher emphysema scores.²³

The relationship between alpha 1-antitrypsin deficiency and bronchial asthma is uncertain, although one study has demonstrated that asthmatic symptoms are more common in Hispanics with S and Z genes.²⁴

CONNECTIVE TISSUE DISORDERS

Connective tissue disorders that can cause emphysema include cutis laxa, Marfan syndrome, and Ehlers-Danlos syndrome (TABLE 1). In each of these, the onset of emphysema is during infancy.

Emphysema onset in alpha 1-antitrypsin deficiency is in the 4th to 5th decades



Cutis laxa

Cutis laxa is an autosomal or X-linked inherited disorder characterized by premature aging due to abnormal formation of elastin.^{25,26} Symptoms of emphysema associated with cutis laxa have been known to occur early in the neonatal period or in infancy, and the recessive form of the disorder is associated with more severe emphysema.²⁵

Cutis laxa is caused primarily by a defect in the synthesis of elastin or tropoelastin or by an accelerated degradation of elastin by protease. On the other hand, the X-linked form of cutis laxa or Ehlers-Danlos type IX results from a deficiency of lysyl oxidase, which is required in the cross-linking of collagen.²⁶

Marfan syndrome

Marfan syndrome is an autosomal-dominant disease of type I collagen characterized by arachnodactyly (long, spider-like digits), posterior subluxation of the crystalline lens, and cardiac valvular defects. Emphysema and apical bullae occur in 10% of patients with this syndrome.

Ehlers-Danlos syndrome

Ehlers-Danlos syndrome is a heterogeneous group of inherited connective tissue disorders characterized by increased laxity of the skin, hypermobility of joints, easy bruisability, pseudotumors, and panacinar emphysema.²⁷

■ OTHER UNUSUAL CAUSES OF EMPHYSEMA

Intravenous drug abuse

About 2% of intravenous drug abusers develop emphysema (mainly basilar and panacinar) due to pulmonary vascular damage from injecting insoluble filler (cornstarch, cotton fibers, cellulose, talc) contained in methadone or methylphenidate.^{28,29} In addition, people who inject cocaine or heroin may develop bullous cysts, mainly in the upper lobes and the peripheral lung tissues.

Human immunodeficiency virus

Emphysema with bullae occurs in 12% of HIV-seropositive patients, regardless of whether they have *Pneumocystis carinii* infection.³⁰ Recent reports show that seropositivity for HIV alone increases the susceptibility to

accelerated emphysema among smokers.^{31,32} Emphysema in patients with HIV infection may develop due to malnutrition, decreased glutathione levels, or enhanced local cytokine or elastase release.³³ Diffusely distributed pneumatoceles may be observed in 10% to 20% of patients with *Pneumocystis carinii* pneumonia.³³

Hypocomplementemic urticarial vasculitis syndrome

Chronic obstructive pulmonary disease occurs in more than half of patients with hypocomplementemic urticarial vasculitis syndrome. This syndrome is eight times more common in women than in men. The time of onset is variable, between ages 23 to 66 years, but usually before age 30.

The most common presenting feature is urticaria, which often precedes chronic obstructive pulmonary disease. Other manifestations include angioedema (72% of patients), non-deforming arthritis or synovitis (50%), conjunctivitis, episcleritis, and pericarditis.³⁴

The most commonly reported symptom is dyspnea, the degree of airflow obstruction may be severe, and the rate of decline of forced expiratory volume in 1 second (FEV₁) may be unusually rapid.³⁵

Malnutrition

Severe malnutrition and weight loss have also been associated with emphysema. The putative mechanism is unopposed elastase-induced lung injury.³⁶

Rare hereditary diseases

Salla disease, an autosomal-recessive disorder of sialic acid metabolism, was first described in two nonsmoking siblings in Scandinavia. These patients had normal life spans but demonstrated severe mental retardation, ataxia, nystagmus, and emphysema.³⁷ The pathophysiology of emphysema in these patients is unknown, but it is postulated that the accumulation of sialic acid in the lysosomes of macrophages impairs antiproteolytic function, thereby promoting elastolysis and centrilobular emphysema.

Menke syndrome is an X-linked recessive disorder. Little is known about this disease, which is caused by abnormal elastin gene

2% of IV abusers of methadone, heroin, or cocaine develop emphysema



expression as a function of disordered copper metabolism in multiple organ systems,³⁸ including the lungs. Emphysema and optic atrophy are typical clinical features.

■ DIAGNOSIS OF EMPHYSEMA DUE TO UNCOMMON CAUSES

In patients with emphysema unrelated to smoking, the etiologic mechanism, age at onset, clinical features, and distribution of lung damage (TABLE 1) are often different from those of typical smoking-related emphysema. Symptoms of the underlying condition usually dominate the clinical presentation.

Specific differences in presentation

In smoking-related emphysema, the onset is usually in the 6th to 8th decades of life, and chest radiography usually shows hyperlucency at the lung apices. In emphysema due to an uncommon cause, however, the onset tends to be earlier, and the distribution of lung damage may be different.

In severe alpha 1-antitrypsin deficiency, the onset of emphysema is during the 4th and 5th decades and primarily affects the lung bases.

In connective tissue disorders, the onset is soon after birth. With cutis laxa and Ehlers-Danlos syndrome, the pattern is panacinar, and with Marfan syndrome the distribution is apical with bullae.

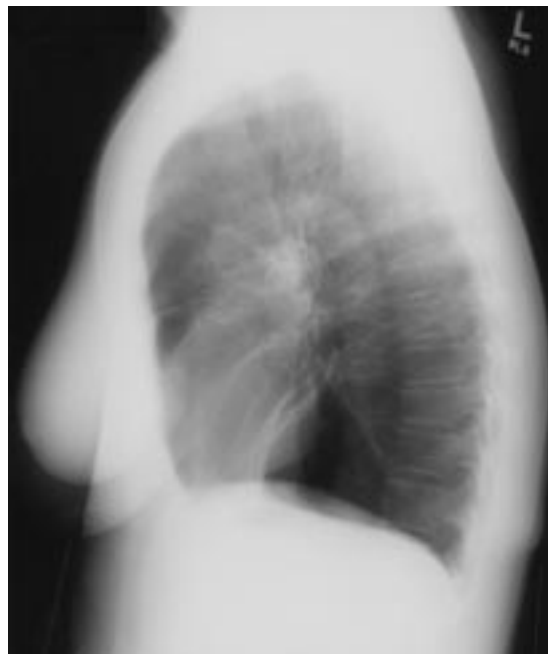
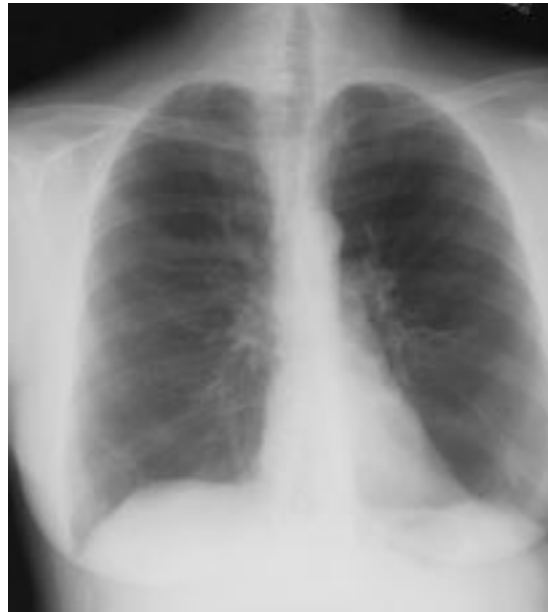In emphysema due to intravenous drug abuse, the onset is usually before age 30, and the distribution may be apical with bullae, as in those who inject heroin or cocaine, or basilar in those who inject methylphenidate or methadone.

In HIV infection or *Pneumocystis carinii* pneumonia, the onset is usually before age 40. Apical and cortical bullae are common in patients with HIV infection. Cysts are often seen in those with *Pneumocystis carinii* pneumonia, although no particular distribution is characteristic; these patients usually present with dyspnea, cough, and fever.

In hypocomplementemic urticarial vasculitis syndrome, the onset is before age 30.

Physical findings

Physical findings related to emphysema in patients with emphysema due to uncommon



In nonsmokers, physical findings of emphysema are the same, but they occur much earlier

FIGURE 1. Posteroanterior and lateral plain chest radiographs of a patient with homozygous ZZ phenotype alpha 1-antitrypsin deficiency. Note that the hyperlucency is greater at the bases of the lungs than at the apices.

causes are similar to those seen in smoking-related emphysema. Patients with mild emphysema usually have no signs or symptoms during quiet breathing. Patients with advanced disease, however, have the classic physical signs of

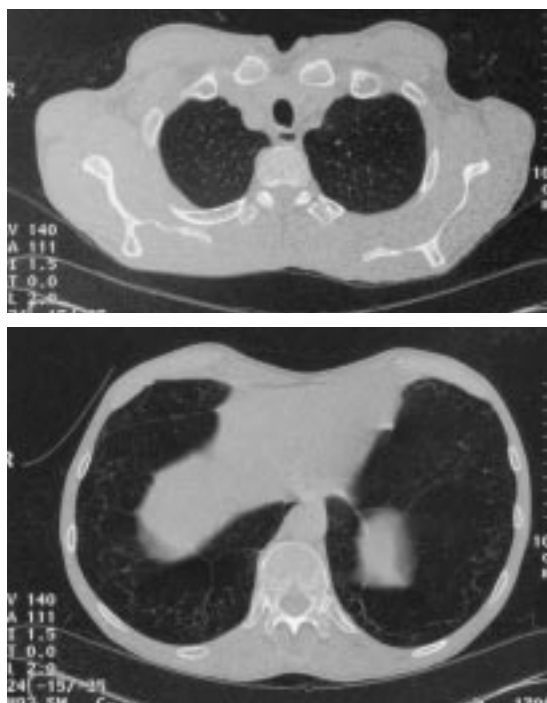


FIGURE 2. Computed tomographic scans of the chest. Both show emphysematous change manifested by the loss of parenchymal markings, which is more pronounced in the base of the lung (bottom) than in a more cephalad cut (top).

If emphysema is mild, chest radiography does not help the diagnosis

barrel-shaped chest, emaciation, pursed-lip breathing, and use of accessory muscles of respiration. During exacerbations of emphysema, patients may assume the tripod position: they sit forward by leaning on the elbows or supporting the upper body with extended arms. This stabilizes the shoulder girdle and places the accessory muscles of respiration (eg, the sternocleidomastoids) at a mechanical advantage. Also, patients with advanced emphysema may show signs of pulmonary hypertension and cor pulmonale, with displaced cardiac impulse, parasternal heave, loud pulmonary component of the second heart sound, and signs of right heart failure.

Chest radiography

Radiographic images of the lungs provide the clearest evidence of emphysema. Typical findings on the frontal and lateral radiographs in patients with smoking-related centriacinar emphysema include a low, flat diaphragm, increased retrosternal airspace, hyperlucency

of the lungs, a long, narrow heart shadow, and tapering of vascular shadows. Bullae—radiolucent areas larger than 1 cm in diameter—may be present and may reflect locally severe emphysema. When pulmonary hypertension or cor pulmonale develops, hilar vascular shadows become more prominent with enlargement of the cardiac silhouette and obliteration of the retrosternal space.

In emphysema due to alpha 1-antitrypsin deficiency, basilar involvement is common: 85% of 165 ZZ homozygotes in one series²² had basilar involvement, though the classic pattern of disproportionate basilar involvement was less common (FIGURE 1). TABLE 1 reviews the distributions typical of emphysema due to other uncommon causes.

Radiography is not helpful in detecting mild emphysema. Studies correlating the degree of emphysema with the appearance on plain chest radiography show that emphysema is consistently diagnosed when the disease is severe, is correctly diagnosed in approximately 50% of patients with moderate disease, and can be overlooked when the disease is mild.³⁹

Computed tomography

Computed tomography (CT) of the chest, especially high-resolution CT with collimation of 1 to 2 mm, has greater sensitivity and specificity than plain chest radiography for detecting emphysema, including mild emphysema (FIGURE 2). However, routine CT in patients with emphysema is not justified, since it alters neither the course of the disease nor its treatment.

CT can be used to guide surgical resection in patients with giant bullae or to diagnose concomitant bronchiectasis.

Pulmonary function testing

Pulmonary function testing is essential for the diagnosis of emphysema, as well as for long-term follow-up.

The FEV₁ is the most useful measure of lung function. It is easy to perform and is highly reproducible, and its relationship to age, sex, and height is well established. The FEV₁ is also used to grade disease severity and is a potent indicator of prognosis.⁴⁰

Reversible airflow obstruction, akin to an “asthmatic” component, may be a feature in



approximately two thirds of patients with chronic obstructive pulmonary disease, including emphysema due to alpha 1-antitrypsin deficiency.

Lung volume measurements may show an increase in total lung capacity and residual volume, with a concomitant reduction in forced vital capacity due to air trapping.

The single-breath carbon monoxide diffusing capacity is also decreased in proportion to the severity of emphysema, due to the loss of the alveolar capillary bed.

Arterial blood gas measurement in early emphysema reveals mild or moderate hypoxemia. As the disease progresses, hypoxemia may worsen, and hypercapnia may supervene. Hypercapnia is more often observed when the FEV₁ falls below 1 L, and these abnormalities may worsen during sleep or during an acute exacerbation.^{41–43}

Additional diagnostic considerations in emphysema due to uncommon causes

Ten to 15 of the variants of the alpha 1-antitrypsin gene are associated with serum levels below the protective threshold of 80 mg/dL or 11 μ mol/L,⁴⁴ and the Z allele accounts for 95% of cases of severe alpha 1-antitrypsin deficiency. For practical purposes, the diagnosis of alpha 1-antitrypsin deficiency due to the ZZ genotype is established if the serum level is 3 to 7 μ mol/L. Specific genotyping is reserved for patients with a low or borderline serum alpha 1-antitrypsin concentration (7 to 11 μ mol/L), or when genetic counseling or family analysis is needed.

The baseline evaluation of patients suspected of having alpha 1-antitrypsin deficiency also should include posteroanterior and lateral chest radiography, spirometry, measurement of oxygenation, and liver function tests.

Decreased levels of C1q and the presence of immunoglobulin G antibodies to C1q are diagnostic for hypocomplementemic urticarial vasculitis syndrome. In 61% of cases, antinuclear and anti-double-stranded DNA antibodies can also be detected.³⁴

TREATMENT CONSIDERATIONS

For patients with emphysema due to uncommon causes, the same therapeutic principles

apply as for smoking-related emphysema. Management includes bronchodilators, supplemental oxygen for hypoxemia, pulmonary rehabilitation, preventive strategies such as influenza and pneumococcal vaccination, and, when indicated, lung transplantation.

Treating alpha 1-antitrypsin deficiency

Current treatment of alpha 1-antitrypsin deficiency is to give augmentation therapy to patients who have established emphysema and a phenotype associated with serum levels below the protective threshold value.^{45,46} Augmentation therapy involves the infusion of pooled human plasma antiprotease to raise serum levels above the protective threshold and to also raise levels of antiprotease in the lungs.

Although there is no definitive evidence from randomized clinical trials that this therapy is clinically effective, observational studies suggest that restoring serum and lung levels of alpha 1-antitrypsin is biochemically effective, and that it is clinically effective in slowing the rates of decline in lung function, at least in patients with established emphysema and moderately severe airflow obstruction.²¹ Furthermore, observational data from the National Institutes of Health Registry of Individuals with Severe Deficiency of Alpha 1-antitrypsin show that recipients have a higher survival rate.²¹

As we already noted, the available evidence makes the indication for augmentation therapy strongest when airflow obstruction is moderate. However, we recommend intravenous augmentation therapy whenever emphysema is established in a patient with severe alpha 1-antitrypsin deficiency. A dose of 60 mg/kg once weekly is widely used. Because current preparations of pooled human plasma alpha 1-antiprotease contain immunoglobulin A, a deficiency of immunoglobulin A should be ruled out in prospective recipients.

Investigators are exploring alternative strategies for augmentation therapy, including recombinant alpha 1-antitrypsin in intravenous and inhaled formulations. Promising approaches in preliminary stages of investigation are enhancement of hepatocyte secretion of functional alpha 1-antitrypsin protein, gene therapy, and synthetic elastase inhibitors.

FEV₁ is the most useful test of lung function in emphysema



Treatment of hypocomplementemic urticarial vasculitis

Hypocomplementemic urticarial vasculitis

syndrome is generally treated with glucocorticoids. Dapsone has also been found to improve lung function in a few patients.⁴⁷

REFERENCES

- Korn RJ, Dockery DW, Speizer FE, Ware JH, Ferris BG Jr. Occupational exposures and chronic respiratory symptoms: a population-based study. *Am Rev Respir Dis* 1987; 136:298-304.
- Becklake MR. Occupational exposures: evidence for a causal association with chronic obstructive pulmonary disease. *Am Rev Respir Dis* 1989; 140(suppl):S85-S91.
- Oxman AD, Muir DC, Shannon HS, Stock SR, Hnizdo E, Lange HJ. Occupational dust exposure and chronic obstructive pulmonary disease. A systematic overview of the evidence. *Am Rev Respir Dis* 1993; 148:38-48.
- Snider G, Klinerman J, Thurlbeck WM. The definition of emphysema: report of the National Heart, Lung, and Blood Institute Division of Lung Diseases Workshop. *Am Rev Respir Dis* 1985; 132:182-185.
- Thurlbeck WM. Overview of the pathology of pulmonary emphysema in the human. *Clin Chest Med* 1983; 4:337-350.
- Thurlbeck WM. Pathology of chronic airflow obstruction. In: Cherniak NS, editor. Chronic obstructive pulmonary disease. Philadelphia: W.B. Saunders, 1991.
- Reid L. The pathology of emphysema. Chicago: Year Book Medical Publishers, 1967.
- Thurlbeck WM. Chronic airflow obstruction in lung disease. Major problems in pathology. Philadelphia: W. B. Saunders, 1976.
- Wewers M. Pathogenesis of emphysema. Assessment of basic science concepts through clinical investigation. *Chest* 1989; 95:190-195.
- Janoff A. Elastases and emphysema. Current assessment of the protease-antiprotease hypothesis. *Am Rev Respir Dis* 1985; 132:417-433.
- Larsson C. Natural history and life expectancy in severe alpha 1-antitrypsin deficiency. *Acta Med Scand* 1978; 204:345-351.
- Eriksson S. Alpha 1-antitrypsin deficiency: lessons learned from the bedside to the gene and back again. Historic perspectives. *Chest* 1989; 95:181-189.
- Eriksson S, Carlson J, Velez R. Risk of cirrhosis and primary liver cancer in alpha 1-antitrypsin deficiency. *N Engl J Med* 1986; 314:736-739.
- Sveger T. Liver disease in alpha 1-antitrypsin deficiency detected by screening of 200,000 infants. *N Engl J Med* 1976; 294:1316-1321.
- Brantly M, Nukiwa T, Crystal RG. Molecular basis of alpha 1-antitrypsin deficiency. *Am J Med* 1988; 84:13-31.
- Crystal RG, et al. The alpha 1-antitrypsin gene and its mutations. Clinical consequences and strategies for therapy. *Chest* 1989; 95:196-208.
- O'Brien ML, Buist NR, Murphey WH. Neonatal screening for alpha 1-antitrypsin deficiency. *J Pediatr* 1978; 92:1006-1010.
- Spence WC, Morris JE, Pass K, Murphy PD. Molecular confirmation of alpha 1-antitrypsin genotypes in newborn dried blood specimens. *Biochem Med Metab Biol* 1993; 50:233-240.
- Silverman EK, Miletich JP, Pierce JA, et al. Alpha 1-antitrypsin deficiency. High prevalence in the St. Louis area determined by direct population screening. *Am Rev Respir Dis* 1989; 140:961-966.
- Stoller JK, Smith P, Yang P, Spray J. Physical and social impact of alpha 1-antitrypsin deficiency: results of a survey. *Cleve Clin J Med* 1994; 61:461-467.
- The Alpha-1-Antitrypsin Deficiency Registry Study Group. Survival and FEV₁ decline in individuals with severe deficiency of alpha 1-antitrypsin. *Am J Respir Crit Care Med* 1998; 158:49-59.
- Brantly ML, et al. Clinical features and history of the destructive lung disease associated with alpha 1-antitrypsin deficiency of adults with pulmonary symptoms. *Am Rev Respir Dis* 1988; 138:327-336.
- Cuvelier A, Muir JF, Hellot MF, et al. Distribution of alpha 1-antitrypsin alleles in patients with bronchiectasis. *Chest* 2000; 117:415-419.
- Colp C, Pappas J, Moran D, Lieberman J. Variants of alpha 1-antitrypsin in Puerto Rican children with asthma. *Chest* 1993; 103:812-815.
- Beighton P. The dominant and recessive forms of cutis laxa. *J Med Genet* 1972; 9:216-221.
- Byers PH, Siegel R, Holbrook KA, et al. X-linked cutis laxa: defective cross-link formation in collagen due to decreased lysyl oxidase activity. *N Engl J Med* 1980; 303:61-65.
- Cupo LN, Pyeritz RE, Olson JL, McPhee SJ, Hutchins GM, McKusick VA. Ehlers-Danlos syndrome with abnormal collagen fibrils, sinus of Valsalva aneurysms, myocardial infarction, panacinar emphysema, and cerebral heterotopias. *Am J Med* 1981; 71:1051-1058.
- Pare JP, Cote G, Fraser RS. Long-term follow-up of drug abusers with intravenous talcosis. *Am Rev Respir Dis* 1989; 139:233-241.
- Stern EJ, Frank MS, Schmutz JF, Glenn RW, Schmidt RA, Godwin JD. Panlobular pulmonary emphysema caused by IV injection of methylphenidate (Ritalin): findings on chest radiographs and CT scans. *Am J Roentgenol* 1994; 162:555-560.
- Diaz PT, Clanton TL, Pacht ER. Emphysema-like pulmonary disease associated with human immunodeficiency virus infection. *Ann Intern Med* 1992; 116:124-128.
- Diaz PT, King ER, Wewers MD, et al. HIV infection increases susceptibility to smoking-induced emphysema. *Chest* 2000; 117(5 suppl 1):285S.
- Diaz PT, King MA, Pacht ER, et al. Increased susceptibility to pulmonary emphysema among HIV-seropositive smokers. *Ann Intern Med* 2000; 132:369-372.
- Gurney JW, Bates FT. Pulmonary cystic disease: comparison of pneumocystis carinii pneumatoceles and bullous emphysema due to intravenous drug abuse. *Radiology* 1989; 173:27-31.
- Wisniewski JJ, Baer AN, Christensen J, et al. Hypocomplementemic urticarial vasculitis syndrome. Clinical and serologic findings in 18 patients. *Medicine (Baltimore)* 1995; 74:24-41.
- Schwartz HR, McDuffie FC, Black LF, et al. Hypocomplementemic urticarial vasculitis: association with chronic obstructive pulmonary disease. *Mayo Clin Proc* 1982; 57:231-238.
- Sahajjani H. Emphysema-like changes in HIV [letter]. *Ann Intern Med* 1992; 116:876.
- Paakko P, Ryhanen L, Rantala H, Autio-Harmainen H. Pulmonary emphysema in a nonsmoking patient with Salla disease. *Am Rev Respir Dis* 1987; 135:979-982.
- Christiano AM, Uitto J. Molecular pathology of the elastic fibers. *J Invest Dermatol* 1994; 103(5 suppl):535-575.
- Sanders C. The radiographic diagnosis of emphysema. *Radiol Clin North Am* 1991; 29:1019-1030.
- Hodgkin JE. Prognosis in chronic obstructive pulmonary disease. *Clin Chest Med* 1990; 11:555-569.
- Barbera JA, Roca J, Ferrer A, et al. Mechanisms of worsening gas exchange during acute exacerbations of chronic obstructive pulmonary disease. *Eur Respir J* 1997; 10:1285-1291.
- McNicholas WT. Impact of sleep in respiratory failure. *Eur Respir J* 1997; 10:920-933.
- McNally E, Fitzpatrick M, Bourke S, et al. Reversible hypercapnia in acute exacerbations of chronic obstructive pulmonary disease (COPD). *Eur Respir J* 1993; 6:1353-1356.
- Brantly M. Report of the WHO meeting on alpha 1-antitrypsin deficiency. In: Human Genetics Programme Division of Noncommunicable Diseases. Geneva: World Health Organization, 1996.
- Abboud RT, Ford GT, Chapman KR. Alpha 1-antitrypsin deficiency: a position statement of the Canadian Thoracic Society. *Can Respir J* 2001; 8:81-88.
- American Thoracic Society. Guidelines for the approach to the patient with severe hereditary alpha 1-antitrypsin deficiency. *Am Rev Respir Dis* 1989; 140:1494-1497.
- Fortson JS. Hypocomplementemic urticarial vasculitis syndrome response to dapsone. *J Am Acad Dermatol* 1986; 15(5 pt 2): 1137-1142.

ADDRESS: James K. Stoller, MD, Department of Pulmonary and Critical Care Medicine, A90, The Cleveland Clinic Foundation, 9500 Euclid Avenue, Cleveland, OH 44195.