

KRISTINE M. ZANOTTI, MD

Section of Gynecologic Oncology, Department of Obstetrics and Gynecology, The Cleveland Clinic

JEROME BELINSON, MD*

The Taussig Cancer Center; Head, Section of Gynecologic Oncology, Department of Obstetrics and Gynecology, The Cleveland Clinic

Update on the diagnosis and treatment of human papillomavirus infection

ABSTRACT

Human papillomaviruses (HPVs) are associated with a spectrum of diseases, ranging from common warts to invasive carcinoma of the genital tract. The clinical manifestations of HPV infection depend on the viral subtype, the immune status of the patient, and environmental co-carcinogens. Infection with HPV is often asymptomatic, which makes viral detection challenging. Current therapies do not reliably eradicate HPV infection, and benign genital warts and genital tract intraepithelial neoplasia often recur after treatment. We discuss the pathogenesis, clinical manifestations, detection, and treatment of HPV infections of the anogenital tract.

KEY POINTS

More than 20 types of HPV infect the genital tract; types 6 and 11 are most commonly associated with benign genital warts; types 16, 18, 31, and others carry a high risk for malignancy.

Commercially available DNA binding techniques now allow detection and subtyping of HPV and are useful adjuncts to cervical cancer screening.

Current cytotoxic, physically ablative, excisional, and immunomodulatory therapies for genital warts may reduce symptoms but are relatively ineffective in eradicating the infection or preventing disease transmission.

Treatment recommendations for HPV infection are strongly influenced by the clinical manifestations and the potential for malignancy.

*The author has indicated he has received supplies and services from the Digene and Cytic corporations and is on the speakers' bureau of Cytic Corporation.

HUMAN PAPILLOMAVIRUS (HPV) infects the terminally differentiated cells of the skin and mucous membranes, often producing local epithelial proliferation or warts. Different HPV subtypes typically show a tropism for a distinct cell type. Currently, 23 HPV subtypes are known to infect the anogenital tract of humans, causing diseases ranging from benign genital warts to invasive carcinoma of the anogenital tract (TABLE 1).

In this article, we review the pathogenesis, clinical manifestations, detection, and treatment of HPV infections of the anogenital tract.

HPV AND ONCOGENIC RISK

HPV infection involves a complex interaction between the patient's cell-mediated and humoral immune system, environmental factors, and the viral subtype. HPV subtypes have been categorized as being of low or high oncogenic risk based on their association with benign epithelial proliferations, high-grade cancer precursors, or invasive carcinomas of the anogenital tract (TABLE 1).

Low-risk and high-risk subtypes

Low-risk HPV subtypes, most commonly HPV 6 and 11, are associated with benign genital warts. On the other hand, HPV 16, 18, 31, and others are associated with intraepithelial neoplasia and anogenital tract cancer and so are considered to carry a high oncogenic risk. DNA from high-risk HPV subtypes is found in nearly all cervical cancer specimens^{1,2} and can identify women with disease and those at particular risk of progression to invasive disease.³ DNA from high-risk HPV subtypes is also found in the neoplastic tissue of penile and



anal carcinomas: in a study of penile intraepithelial neoplasia,⁴ 70% to 100% of lesions were positive for HPV DNA, whereas lesions of invasive penile cancer were positive in 40% to 50% of cases.⁴

Verrucous carcinoma and bowenoid papulosis

Verrucous carcinoma and bowenoid papulosis are uncommon exceptions to these oncogenic risk generalities. Verrucous carcinoma is a slow-growing, locally invasive, but rarely metastatic neoplasm that may be associated with HPV types 6 and 11. Conversely, bowenoid papulosis is associated with high-risk HPV subtypes and is characterized by the histological findings of squamous cell carcinoma in situ, yet it follows a largely benign clinical course.

■ CLINICAL MANIFESTATIONS AND NATURAL HISTORY

Visible manifestations of HPV are seen in only a minority of persons infected with the virus.⁵ The average latency period is 3 months,⁶ and clinically apparent lesions may present from 3 weeks to years after initial exposure.

Genital warts

Benign genital warts (condylomata acuminata) initially present as exophytic papules typically seen on moist non-hair-bearing skin involving the vulva, vagina, cervix, perineum, penis, and anal region. Infection at multiple sites is common. These lesions may become confluent or progress to large pedunculated, cauliflower-like masses. Sessile plaque-like flat warts may also be present, most commonly on the penile shaft and in the vagina. Left untreated, genital warts can spontaneously regress, persist, or grow.

Intraepithelial neoplasia

HPV-associated intraepithelial neoplasia most commonly involves the uterine cervix but may also be found on the vulva, vagina, and male genitalia. Fortunately, most patients infected with high-risk HPV subtypes do not develop malignancy. Only 3% to 4% of women known to be infected with HPV worldwide go on to develop cervical cancer,

TABLE 1

Genital lesions associated with human papillomavirus infection

CONDITION	HPV SUBTYPE
Condyloma acuminatum	6, 11
Verrucous carcinoma	6, 11
Bowenoid papulosis	16, 31, 32, 34, 35, 37, 42
Intraepithelial neoplasia, invasive carcinoma (cervix, vulva, vagina, penis, anus)	16, 18, 31, 33, 35, 39, 42, 43, 44, 45, 51, 52, 56

the most common HPV-associated malignancy.⁷ These rates are higher in immunocompromised patients, such as those also infected with human immunodeficiency virus (HIV).

Contrary to prior belief, HPV infection may in fact be transient: for many people with HPV, infection may be cleared within 6 months to 2 years.^{8,9}

Papillomavirus infection and cancer risk

Years or decades are typically required for HPV infection to develop into a frankly malignant lesion, although considerable variability exists among individuals.

Long-term, persistent infection with certain HPV subtypes, especially at high viral loads, is a strong risk factor for high-grade precancerous lesions and cancers.^{10,11} Thus, the inability to clear infection with a high-risk HPV subtype is a significant risk factor for the subsequent development of precursor lesions and neoplasia.

Exposure to environmental carcinogens also significantly increases risk for the development of neoplasia. Cigarette smoking is a particularly significant co-carcinogen in these diseases.

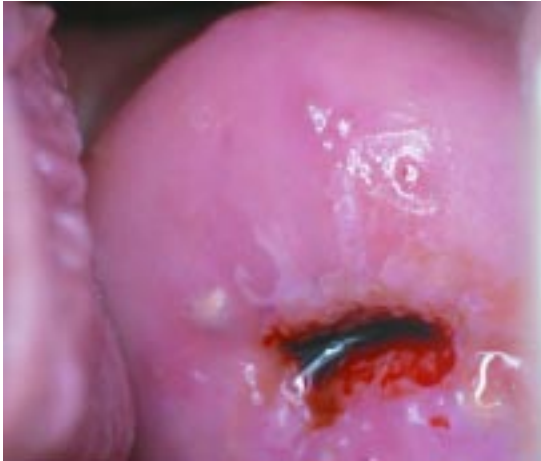■ CLINICAL EXAMINATION

Role of the Papanicolaou smear

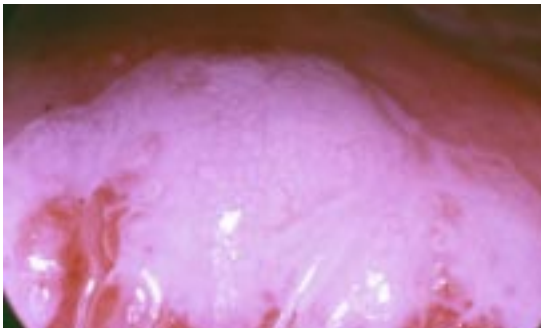
The cervical Papanicolaou (Pap) smear is one of the most effective indicators of common and potentially serious clinical manifestations of HPV infection. Cytologic changes such as koilocytosis, nuclear atypia, delayed maturation,

Visible signs of HPV occur in only a minority of those infected

Cervical dysplasia: Grade 1 intraepithelial neoplasia



Grade 3 intraepithelial neoplasia



Cervical cancer

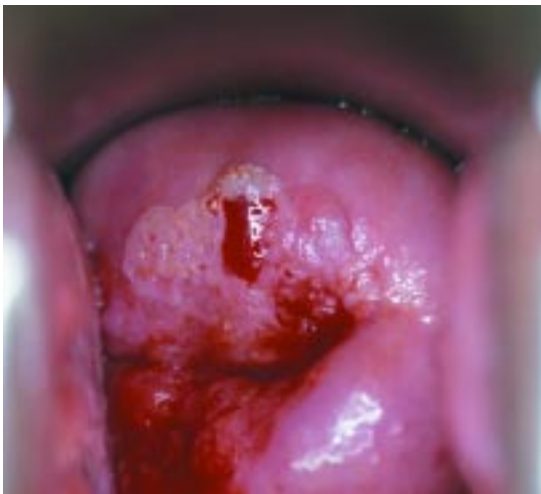

FIGURE 1. Colposcopic view of various stages of cervical dysplasia. Top, grade 1 cervical intraepithelial neoplasia. Middle, grade 3 cervical intraepithelial neoplasia. Bottom, cervical cancer (6 to 9 o'clock) in a background of grade 3 intraepithelial neoplasia.

tion, hyperkeratosis, and parakeratosis are all highly associated with HPV infection and identify neoplastic cervical precursor lesions with a high degree of accuracy. In fact, the success of the Pap smear in cervical cancer screening programs has served as a model for population-based screening, early detection, and treatment. Since the introduction of Pap screening in the United States, the incidence and mortality of cervical cancer have declined by more than 40%.¹²

Colposcopic follow-up of an abnormal Pap smear

Abnormalities delineated by Pap smear that suggest HPV cytopathy or cervical dysplasia should be further evaluated by colposcopy. (Any abnormality displaying any HPV cytopathic effect is considered at least a low-grade squamous intraepithelial lesion [LGSIL].) The colposcope magnifies the epithelium from 4 to 40 times, enabling visualization of epithelial and vascular changes typical of low-grade and high-grade dysplasia and cancer (FIGURE 1). Epithelium that turns white after a 1-minute or 2-minute exposure to 5% acetic acid often indicates an underlying histologic abnormality. Atypical vascular patterns within this epithelium may also be identified with the aid of a green light filter. Biopsy of suspicious lesions is performed under direct visualization during colposcopy.

What to do once a lesion is identified

Any time an HPV-associated lesion is identified, thorough magnified inspection of all regions of the anogenital tract is warranted. External lesions are often, but not always, pruritic. Vaginal intraepithelial neoplastic lesions are generally white with sharp borders and are often multifocal; as mentioned above, application of 5% acetic acid may help to identify these lesions.

Vulvar, penile, and anal intraepithelial neoplasia may present as irregular, sharply demarcated lesions most commonly involving the labia minora, the introitus, the penile glans, prepuce, and shaft, and the anus. Due to keratinization of the epithelium, prolonged application (3 to 5 minutes) of acetic acid may be necessary for better identification of dysplastic lesions. Lesions may be unifocal or

Use colposcopy
to evaluate Pap
test lesions
that suggest
dysplasia

**TABLE 2****Current tests that detect human papillomavirus DNA**

METHOD	SENSITIVITY	COMMENTS
Dot blot (ViraPap, ViraType, etc)	Moderate	FDA-approved, commercially available Uses radioactivity
Filter in situ hybridization	Low	
Southern blot hybridization	High	Uses radioactivity, labor-intensive, expensive
Hybrid Capture 2	High	FDA-approved, commercially available Detects 5 low-risk and 13 high-risk HPV subtypes Does not use radioactivity
Consensus primer polymerase chain reaction	Very high	Highest sensitivity of current tests Prone to contamination and false-positives High sensitivity may be of limited clinical relevance*

*This is because patients infected at very low levels are at low risk for significant disease, and patients with a sustained high level of infection are at greater risk for the development of disease.

multifocal and slightly raised, and their pigment may be white, reddish, gray, or even brown.

■ VIRAL DETECTION

HPV is a particularly difficult virus to study from an epidemiologic standpoint. The low incidence of clinical manifestations among people infected with HPV has prompted the development of alternative methods of viral detection. Unfortunately, there has been only very limited success in propagating HPV in the laboratory for study. An inability to grow HPV in tissue culture results from the virus's need for terminally differentiated epithelial cells, which can no longer divide and cannot be successfully maintained in cell culture. In addition, the exclusive species specificity of HPV also limits our ability to propagate it in animal models.

Serum immunologic markers have been of use in identifying some viral infections, but not HPV. HPV is inherently only weakly antigenic, and immune response to the virus is quite variable among individuals. In addition, viral subtyping is problematic with these techniques, since the capsid proteins of different

HPV subtypes are antigenically quite similar.

Molecular detection methods

A variety of molecular detection methods have been developed and are now used to detect HPV DNA and type the virus (TABLE 2). Each method has advantages and disadvantages, and sensitivity and specificity vary. One such test, the Hybrid Capture 2 HPV DNA test (Digene Corporation, Gaithersburg, Md), is reliable, user-friendly, and relatively inexpensive.

■ CLINICAL APPLICATIONS OF VIRAL DETECTION TESTING

A key clinical application of HPV detection and subtyping is in cervical cancer screening. In the United States, 2 to 3 million Pap smears annually reveal minimally abnormal findings, ie, LGSIL and atypical squamous cells of undetermined significance (ASCUS). Only a small number of these lesions are clinically significant, and nearly 80% spontaneously regress. Follow-up colposcopic evaluation of all minimally abnormal Pap smears represents a substantial financial cost for the health care system, and a substantial personal

HPV subtyping helps triage women with minimally abnormal Pap tests for further testing

FIGURE 2

**Not available for online publication.
See print version of the
*Cleveland Clinic Journal of Medicine***

**HPV testing
may be a cost-
effective
screening tool
in areas of the
world low on
resources**

and emotional cost for the patient. HPV viral subtyping has been identified as a useful method for triage of women with minimally abnormal Pap smears (eg, ASCUS) for further evaluation by colposcopy.

In a large prospective randomized trial by the National Cancer Institute evaluating the role of the Hybrid Capture 2 test in the triage of women with minimally abnormal Pap smear results,^{13,14} a positive test for HPV DNA of subtypes associated with a high oncogenic risk was highly sensitive in the detection of cervical cancer precursors in women with ASCUS Pap smears. Under current screening recommendations, only women with ASCUS who test positive for high-risk HPV subtypes warrant referral for colposcopic evaluation.¹⁵

The test is particularly useful in women age 35 and older with a diagnosis of ASCUS who test positive for high-risk HPV subtypes, as it indicates persistent, unresolved infection.¹⁶

HPV testing appears to be less useful, however, in the triage of women with LGSIL, because HPV infection is highly prevalent in this group of women.¹⁴

**Primary screening tool in areas
with few health care resources**

Considerable interest has also been devoted to the application of HPV testing as a primary screening tool in low-resource settings. This technique may provide a cost-effective screening method in areas of the world where more costly cytology-based screening programs are not feasible, thus reaching women at risk who otherwise might not benefit from cervical cancer screening.^{17,18}

HPV infection extremely common

The exact prevalence of HPV infection is impossible to define. Studies reporting these statistics have produced widely disparate results due to differing sensitivities in the methods used for detecting HPV infection, the frequency of HPV screening within a given population, and differences in the populations studied.

In general, screening in various populations indicates that HPV infection is extremely common, especially in young sexually active populations. The prevalence of high-risk HPV subtypes parallels that of overall viral detection rates. From 20% to 40% of young, sexually active men and women may be infected with HPV at some point, and up to 70% of those attending sexually transmitted disease clinics.¹⁹⁻²¹ HPV prevalence declines dramatically with age, correlating with fewer new sexual partners and resolution of viral infection (FIGURE 2).

Detection of cervical HPV DNA in apparently normal young patients implies relatively little about risk for cancer. Rather, in this group HPV DNA is mostly a marker of sexual activity. On the other hand, finding HPV DNA in the cervix and other tissues of the anogenital tract in older patients implies something quite different and is often related to a lack of viral immunity and increased cancer risk.²⁰

Incidence of cervical cancer

In the United States, cervical carcinoma is the sixth most common carcinoma among women, with an estimated 13,700 women diagnosed in 1998.¹² In less developed nations that lack effective screening programs, the incidence is substantially higher,

TABLE 3

Current therapies for papillomavirus-related warts and neoplasia**Cytotoxic agents**

Trichloroacetic acid	<p>For destruction of genital warts</p> <p>An 80% to 90% solution is applied directly to the wart in the clinic</p> <p>Causes chemical destruction of wart epithelium</p> <p>Treatment repeated weekly</p> <p>Not absorbed systemically; can be used in pregnancy</p>
Podophyllin	<p>For destruction of genital warts</p> <p>A plant compound that works by arresting cells in mitosis</p> <p>Applied to warts at a concentration of 10% to 25% in a compound tincture of benzoin</p> <p>The compound is applied in the clinic and should be washed off after 1 to 4 hours</p> <p>Applied weekly</p> <p>This compound is absorbed in the systemic circulation</p> <p>Excessive exposure can cause bone marrow depression</p> <p>Applications should be less than 0.5 mL</p> <p>Not to be used in pregnancy</p>
Podofilox	<p>For destruction of genital warts</p> <p>A 0.5% solution is applied twice a day for 3 days, followed by 4 days without treatment</p> <p>Designed for self-application; reduces the number of clinic visits</p> <p>Not to be used in pregnancy</p>
5-Fluorouracil	<p>For treatment of multifocal or extensive vulvar or vaginal intraepithelial neoplasia</p> <p>An antimetabolite, applied as a 5% cream</p> <p>Causes tissue destruction by interfering with DNA and RNA synthesis</p> <p>A thin layer of cream is usually spread over lesions 1 to 3 times per week, but regimens may vary</p> <p>Designed for self-application</p> <p>May cause significant local irritation</p> <p>Not to be used in pregnancy</p>

Physical ablation

Laser ablation	<p>For destruction of extensive genital warts or treatment of multifocal or extensive vulvar or vaginal intraepithelial neoplasia</p> <p>CO₂ laser uses intense focal heat to vaporize tissue</p> <p>This is a destructive method that does not permit pathologic assessment of involved tissue</p> <p>Usually, general anesthesia is required</p> <p>Postprocedural discomfort may be significant</p>
----------------	---

continued

and cervical carcinoma is among the leading causes of cancer-related death in women. Fortunately, penile and anal carcinoma are less common, with a relative incidence approximately one tenth that of cervical carcinoma.^{12,22,23}

■ TREATMENT OF GENITAL WARTS AND NEOPLASIA DUE TO PAPILLOMAVIRUS

The decision whether to treat HPV-associated lesions is strongly influenced by the clinical manifestations, symptoms, and the potential for malignancy. Pregnancy status, location and extent of genital warts, likelihood of compli-

ance, and cost also influence the choice of treatment method.

Genital warts

For many infectious diseases, there is no doubt that treatment is beneficial and worthwhile, and the standard infectious disease control objectives of eradication and prevention can be achieved. For benign genital warts due to HPV infection, the situation is not so clear-cut: no current therapy eradicates HPV infection, and current therapies have a limited impact in preventing wart recurrence and reducing the likelihood of disease transmission.

TABLE 3 continued

Excision

Surgical excision	Surgical excision with re-approximation and closure using absorbable suture is most often used for large exophytic condylomata or confluent vulvar or vaginal intraepithelial neoplasia Enables the pathologic assessment of diseased tissue Multifocal disease may not be amenable to this form of therapy General anesthesia is usually required Postprocedural discomfort generally less than with laser treatment
Loop electrode excision procedure (LEEP)	Primarily used to excise cervical intraepithelial neoplasia May also be used to excise genital warts or vulvar or vaginal intraepithelial neoplasia Depth of excision may be difficult to control for vulval and vaginal excision Uses a radiofrequency alternating current passed along a thin wire loop to excise lesions with minimal thermal artifact

Immunomodulation

Imiquimod	For the treatment of genital warts; recent evidence in small case series also suggests efficacy in vaginal intraepithelial neoplasia and anal dysplasia ^{26,27} Modifies the immune response; a potent inducer of interferon- α ; enhances cell-mediated cytologic activity against viral targets; topically applied, induces local production of interferon and other cytokines that can be important mediators of viral clearance Designed for self-application as primary or adjuvant therapy of genital warts; not recommended for mucosal surfaces, such as the vagina; a 5% cream is applied to warts overnight 3 times per week for up to 16 weeks; this regimen has led to complete clearance of genital warts in more than 30% to 60% of patients ^{24,25} Mild to moderate local inflammation is the most common side effect, but the drug is well tolerated; no systemic side effects have been reported
Interferons	Have both immunomodulatory and direct antiviral activity Routes of administration include intralesional injection, topical, and systemic; for recombinant interferon- α , intralesional injections are given at the base of each wart 3 times a week for 3 weeks; topical creams have little reported success; intramuscular or subcutaneous administration of interferon- γ is associated with a 30% to 50% clearance rate ^{28,29} Systemic adverse effects, such as flu-like symptoms and leukopenia, are substantial, even with intralesional use Despite its marked promise, interferon has never been widely used for primary therapy of genital warts because it had to be given via injection and produced systemic side effects

In most cases, the only attainable goal of treatment is to reduce the manifestations of the virus. Genital warts may be cosmetically unacceptable and uncomfortable and are associated with both physical and psychosocial dysfunction. Although eradication of the virus is not possible, for many patients treatment of benign genital warts is warranted to reduce these negative aspects of the disease. Patients must have a realistic understanding of these treatment goals before starting therapy.

Many of the current treatments for genital warts have been available for decades (TABLE 3).²⁴⁻²⁹ Most are effective in clearing warts or temporarily reducing their size. Recurrence rates, however, are high with all current treatments.³⁰

Unfortunately, the efficacy of the various treatments has rarely been assessed in placebo-controlled prospective clinical trials, and there are no trials comparing one treatment with another. Further, rates of recurrence reported from case series for the various treatment strategies vary widely and are often a function of the length of follow-up, rendering comparisons difficult. Nevertheless, clinical experience shows that treatment success in general is influenced by the location and extent of genital warts, the intensity of treatment efforts, and the immune status of the patient.

Immunomodulatory treatments. Until recently, treatments for genital warts have been limited to methods of chemical or physical destruction. More recently, immunomodulatory

latory strategies have been introduced. Among these is imiquimod (Aldara), an immune-response modifier that induces production of host interferon and other endogenous cytokines with antiviral properties (TABLE 3).

Intraepithelial neoplasia

Treatment of high-grade genital tract intraepithelial neoplasia generally warrants either excisional or ablative treatment. Many treatments appropriate for excision or ablation of genital warts may also be applied to intraepithelial neoplasia. A more detailed discussion of the treatment of these lesions and of genital tract cancers, however, is beyond the scope of this review.

As with benign genital warts, recurrences after therapy are common. Of note, cigarette smoking is a sufficiently strong co-carcinogen for HPV-mediated intraepithelial dysplasia to justify dedicated education and counseling for smoking cessation in these patients who smoke.

MANAGEMENT OF PARTNERS

The US Centers for Disease Control and Prevention mandates the reporting of cases of many types of communicable disease for control and prevention of the spread of infectious disease. However, reporting cases of HPV is not mandatory, for two reasons:

- When infection is identified, it cannot be eradicated either in the index patient or the exposed patient
- HPV's long latency period and the small percentage of patients who develop clinical manifestations make tracking the disease extremely difficult.

Nevertheless, disclosure of HPV infection to one's sexual partners is responsible behavior, and physicians should encourage it.

Specific recommendations

Because HPV infection is highly prevalent and highly contagious, current partners of infected individuals are likely to already be infected with HPV. Condom use may reduce the risk of viral spread, but because the virus has the ability to infect epithelium of the entire anogenital tract, exposure can still occur with condom use.

Routine examination of asymptomatic sexual partners of affected individuals is not compulsory, and there is also no evidence to support simultaneous treatment of the partner to reduce the likelihood of disease recurrence. Most recurrences within a patient are believed to be caused by activation of latent virus present in adjacent normal skin, rather than re-infection by a partner.³¹

As always, an annual Pap smear screening test is recommended for all sexually active women, and its importance should be emphasized in women with a history of exposure to HPV.

PREVENTION AND PROSPECTS FOR AN HPV VACCINE

Given the general ineffectiveness of treatments of the clinical manifestations of HPV infection, prevention is critical. The development of effective prophylactic vaccines against HPV is of particular interest worldwide for the prevention of anogenital neoplasms.


Prophylactic vaccination induces antiviral neutralizing antibodies that protect against subsequent viral exposure. For virally mediated carcinomas, one would expect a reduction in the incidence of these diseases with an effective vaccine program, and in fact, this has proven true. The incidence of hepatocellular carcinoma in Taiwanese children decreased by half after the introduction of universal hepatitis B vaccination.³²

HPV appears to be amenable to prophylactic vaccine therapy. Recombinantly expressed HPV L1 major capsid proteins have been shown to self-assemble into virus-like particles that are structurally identical to the HPV capsid and are capable of inducing neutralizing antibodies in the host.³³ However, numerous challenges of both vaccine design and clinical trial must be addressed when considering a large-scale vaccination program. Unless a common epitope is universally effective, it is likely that a multivalent vaccine will be necessary to achieve a true population-wide impact on HPV infection and its sequelae. In addition, appropriate clinical endpoints and target populations for trials must be identified for timely and cost-effective

Current sexual partners are likely already infected



evaluation of vaccine efficacy. Currently, the World Health Organization and NIH are considering several vaccine designs for trial.

A successful HPV vaccine could have a substantial impact on anogenital tract cancer mortality worldwide. 

■ REFERENCES

1. **Bosch FX, Manos MM, Munoz N, et al.** Prevalence of human papillomavirus in cervical cancer: a worldwide perspective. *J Natl Cancer Inst* 1995; 87:796–802.
2. **Walboomers JM, Jacobs MV, Manos MM, et al.** Human papillomavirus is a necessary cause of invasive cervical cancer worldwide. *J Pathol* 1999; 189:12–19.
3. **Koutsky L.** A cohort study of the risk of cervical intraepithelial neoplasia grade 2 or 3 in relation to papillomavirus. *N Engl J Med* 1992; 327:1272–1278.
4. **Dillner J, von Krogh G, Horenblas S, et al.** Etiology of squamous cell carcinoma of the penis. *Scand J Urol Nephrol* 2000; 205(suppl):189–193.
5. **Koutsky L.** Epidemiology of genital human papillomavirus infection. *Am J Med* 1997; 102:3–8.
6. **Oriel JD.** Natural history of genital warts. *Br J Vener Dis* 1971; 47:1–13.
7. **De Villiers EM, Wagner D, Schneider A, et al.** Human papillomavirus DNA in women without and with cytological abnormalities: results of a 5-year follow-up study. *Gynecol Oncol* 1992; 44:33–39.
8. **Moscicki AB, Palefsky J, Smith G, et al.** Variability of human papillomavirus DNA testing in a longitudinal cohort of young women. *Obstet Gynecol* 1993; 82:578–585.
9. **Chua KL, Hjerpe A.** Persistence of human papillomavirus (HPV) infections preceding cervical carcinoma. *Cancer* 1996; 77:121–127.
10. **Wallin KL, Wiklund F, Angstrom T, et al.** Type-specific persistence of human papillomavirus DNA before the development of invasive cervical cancer. *N Engl J Med* 1999; 341:1633–1638.
11. **Nobbenhuis MAE, Walboomers JM, Helmerhorst TJ, et al.** Relation of human papillomavirus status to cervical lesions and consequences for cervical cancer screening: a prospective study. *Lancet* 1999; 354:20–25.
12. **Ries LAG, Kosary CL, Hankey BF, Miller BA, Edwards BK, editors.** SEER Cancer Statistics Review, 1973–1995. Bethesda, Md: National Cancer Institute, 1998.
13. **Solomon D, Schiffman M, Tarone R.** For the Atypical Squamous Cells of Undetermined Significance/Low-Grade Squamous Intraepithelial Lesions Triage Study (ALTS) Group. Comparison of three management strategies for patients with atypical squamous cells of undetermined significance: baseline results from a randomized trial. *J Natl Cancer Inst* 2001; 93:293–299.
14. **The Atypical Squamous Cells of Undetermined Significance/Low-Grade Squamous Intraepithelial Lesions Triage Study Group.** Human papillomavirus testing for triage of women with cytologic evidence of low-grade squamous intraepithelial lesions: baseline data from a randomized trial. *J Natl Cancer Inst* 2000; 92:397–402.
15. **Kurman RJ, Henson DE, Herbst AL, Noller KL, Schiffman MH.** Interim guidelines for management of abnormal cervical cytology. *JAMA* 1994; 271:1866–1869.
16. **Belinson J, Qiao YL, Pretorius R, et al.** Shanxi Province Cervical Cancer Screening Study: a cross-sectional comparative trial of multiple techniques to detect cervical neoplasia. *Gynecol Oncol* 2001; 83:439–444.
17. **Manos MM, Kinney WK, Hurley LB, et al.** Identifying women with cervical neoplasia using human papillomavirus DNA testing for equivocal Papanicolaou results. *JAMA* 1999; 281:1605–1610.
18. **Cuzick J.** Human papillomavirus testing for primary cervical cancer screening. *JAMA* 2000; 283:108–109.
19. **Lorincz AT, Reid R, Jenson AB, Greenberg MD, Lancaster W, Kurman RJ.** Human papillomavirus infection of the cervix: relative risk associations of 15 common anogenital types. *Obstet Gynecol* 1992; 79:328–337.
20. **Schiffman MH.** Latest HPV findings: some clinical implications. *Contemp Ob Gyn* 1993; 27–41.
21. **Melkert PW, Hopman E, van den Brule AJ, et al.** Prevalence of HPV in cytologically normal cervical smears, as determined by the polymerase chain reaction, is age-dependent. *Int J Cancer* 1993; 53:919–923.
22. **Frisch M, Friis S, Kjaer SK, Melbye M.** Falling incidence of penis cancer in an uncircumcised population. *BMJ* 1995; 311:1471.
23. **Cummings B, Keane T, Thomas G, et al.** Results and toxicity of the treatment of anal canal carcinoma by radiation therapy or radiation therapy and chemotherapy. *Cancer* 1984; 54:2062–2068.
24. **Gollnick H, Barasso R, Jappe U, et al.** Safety and efficacy of imiquimod 5% cream in the treatment of penile genital warts in uncircumcised men when applied three times weekly or once per day. *Int J STD AIDS* 2001; 12:22–28.
25. **Beutner KR, Tying SK, Trofatter KF Jr, et al.** Imiquimod, a patient-applied immune-response modifier for treatment of external genital warts. *Antimicrob Agents Chemother* 1998; 42:789–794.
26. **Davis G, Wentworth J, Richard J.** Self-administered topical imiquimod treatment of vulvar intraepithelial neoplasia. A report of four cases. *J Reprod Med* 2000; 45:619–623.
27. **Pehoushek J, Smith KJ.** Imiquimod and 5% fluorouracil therapy for anal and perianal squamous cell carcinoma in situ in an HIV-1-positive man. *Arch Dermatol* 2001; 137:14–16.
28. **Kerby PK, Kiviat N, Beckman A, Wells D, Sherwin S, Corey L.** Tolerance and efficacy of recombinant human interferon-gamma in the treatment of refractory genital warts. *Am J Med* 1988; 85:183–188.
29. **Schonfeld A, Nitke S, Schattner A, et al.** Intramuscular human interferon-beta injections in treatment of condylomata acuminata. *Lancet* 1984; 1:1038–1042.
30. **Kraus SJ, Stone KM.** Management of genital infection caused by human papillomavirus. *Rev Infect Dis* 1990; 12(suppl 6):620–632.
31. **Ferenczy A, Mitao M, Nagai N, et al.** Latent papillomavirus and recurring genital warts. *N Engl J Med* 1985; 313:784–788.
32. **Chang MH, Chen CJ, Lai MS, et al.** Universal hepatitis B vaccination in Taiwan and the incidence of hepatocellular carcinoma in children. *N Engl J Med* 1997; 336:1855–1859.
33. **Murakami M, Gurski KJ, Stellar MJ.** Human papillomavirus vaccines for cervical cancer. *J Immunother* 1999; 22:212–218.

.....
ADDRESS: Kristine M. Zanutti, MD, Department of Obstetrics and Gynecology, A81, The Cleveland Clinic Foundation, 9500 Euclid Avenue, Cleveland, OH 44195; e-mail zanuttk@ccf.org.