

STEFAN MONEV, MD*

Department of Medicine, University of Mississippi
Medical Center, Jackson, Mississippi

Idiopathic retroperitoneal fibrosis: Prompt diagnosis preserves organ function

ABSTRACT

Prompt diagnosis of idiopathic retroperitoneal fibrosis improves chances of preserving renal function, preventing involvement of other organs, and relieving symptoms. Computed tomography or magnetic resonance imaging helps to exclude secondary causes, but open biopsy remains the gold standard for diagnosis. Management typically includes surgery (ureterolysis, stent placement), and drug treatment (corticosteroids), or a combination of both. However, no surgical or medical therapy has been tested in a randomized, controlled trial.

KEY POINTS

Most patients (80%) present with dull, poorly localized pain in the back, flank, or abdomen.

An elevated sedimentation rate is found in 80% to 90% of patients. Mild normochromic normocytic anemia, increased creatinine, and polyclonal hypergammaglobulinemia are also common.

Associations with ankylosing spondylitis, systemic lupus erythematosus, systemic sclerosis, Wegener granulomatosis, and polyarteritis nodosa have been described.

Biopsy is required to exclude malignancy, infection, and other causes of secondary retroperitoneal fibrosis.

*This paper discusses treatments that are not approved by the Food and Drug Administration (FDA) for the use under discussion.

THE CHIEF DANGERS from idiopathic retroperitoneal fibrosis—ureteral obstruction with loss of renal function, and other organ involvement—are avoidable and treatable with prompt diagnosis. This, however, requires a high index of suspicion in patients with abdominal, back, or flank pain or renal insufficiency.

In this brief overview, I outline the pertinent diagnostic features of retroperitoneal fibrosis and current treatment options.

A CLASSIC PRESENTATION OF RETROPERITONEAL FIBROSIS

A 54-year-old African American woman was evaluated for pneumonia in June 1996, and a chest radiograph at that time showed an apparent soft tissue mass in the retroperitoneum. Computed tomography (CT) of the abdomen revealed a periaortic mass and right hydronephrosis. Retroperitoneal fibrosis was diagnosed on the basis of a needle biopsy and open biopsy of the mass. No treatment was started at that time.

A CT scan in June 1997 showed that the retroperitoneal mass and the hydronephrosis had increased (FIGURE 1). The serum creatinine concentration was 0.8 mg/dL (normal 0.7–1.4). A repeat biopsy confirmed the diagnosis of retroperitoneal fibrosis. In December 1997, the patient developed dull right lower back pain, and she was referred to The Cleveland Clinic for evaluation.

Nothing in her physical examination or laboratory results was strikingly abnormal, but there were subtle trends. No abdominal mass,



hepatosplenomegaly, or leg edema was detected. Her blood pressure was only slightly elevated at 150/90 mm Hg, and her hemoglobin concentration was slightly low at 11.5 g/dL (normal 12–16). Her serum creatinine concentration was 0.8 mg/dL (normal 0.7–1.4), erythrocyte sedimentation rate 46 mm/hour (normal 0–20), C-reactive protein level 1.5 mg/dL (normal 0–2.0), and antinuclear antibody and rheumatoid factor titers negative. A C-reactive protein level of 1.5, even though still in the normal range, could indicate a mild inflammatory process.

In January 1998, the patient was started on tamoxifen 10 mg twice daily. In spite of this, at a follow-up visit in April 1998, she complained of persistent right lower back pain. On examination, she had mild right upper quadrant abdominal tenderness. However, CT revealed a moderate decrease in both the size of the retroperitoneal mass and the degree of hydronephrosis (FIGURE 2). The erythrocyte sedimentation rate had decreased to 24 mm/hour, and the C-reactive protein level was 0.5 mg/dL. The dose of tamoxifen was increased to 20 mg twice daily.

Nevertheless, by August 1998, her abdominal pain had worsened. CT showed no change in the retroperitoneal mass and her creatinine level was unchanged, but her C-reactive protein level had further decreased to less than 0.3 mg/dL. The effect of tamoxifen was considered inadequate, and prednisone 40 mg/day was added, after which her symptoms improved.

HISTORY AND EPIDEMIOLOGY

Idiopathic retroperitoneal fibrosis is a rare collagen vascular disease of the retroperitoneum. The French urologist Albarran described the first case in 1905,¹ and Ormond's description of two cases in 1948² established retroperitoneal fibrosis as a clinical entity. To date, more than 800 cases have been reported.

The estimated annual incidence is 0.2 to 0.5 per 100,000, with no difference between ethnic groups. The male to female ratio is 2:1 to 3:1. The average age at onset of retroperitoneal fibrosis is 50 years, and it is distinctly uncommon in children. Retroperitoneal fibrosis is described in 5% of patients with abdomi-

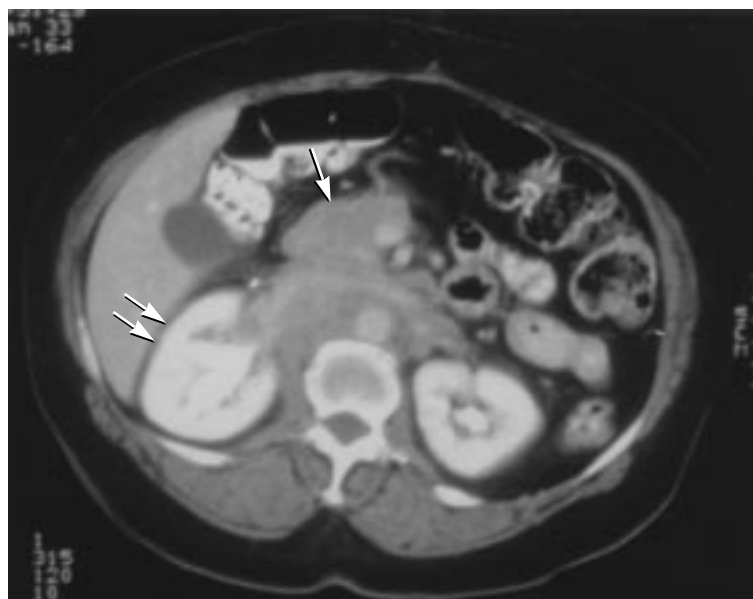


FIGURE 1. Abdominal computed tomography scan in June 1997 shows a large retroperitoneal soft tissue mass (arrow) and right hydronephrosis (double arrows)

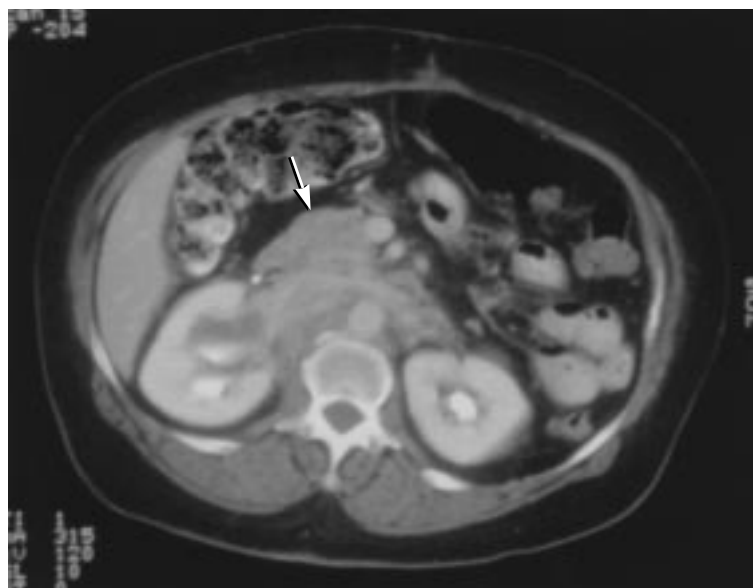

FIGURE 2. Follow-up scan in April 1998 reveals a moderate decrease in the periaortic soft tissue mass and right hydronephrosis

nal aortic aneurysm and is called “inflammatory aortic aneurysm.” The fibrosis often persists after repair of the aneurysm and may produce organ complications similar to those of idiopathic retroperitoneal fibrosis.³ It remains to be clarified if these are two separate entities or

part of the larger spectrum of retroperitoneal fibrosis. The following discussion is limited to idiopathic retroperitoneal fibrosis in patients without abdominal aortic aneurysm.

■ PATHOLOGY

Pathologic study reveals dense plaque in the retroperitoneum, starting at the aortic bifurcation and gradually enveloping the aorta, inferior vena cava, and ureters. The disease is bilateral in two thirds of cases. It may involve the gonadal, celiac, superior mesenteric, and renal arteries. Extraperitoneal fibrosis develops in 8% to 15% of patients and presents as mediastinal fibrosis, Riedel thyroiditis, orbital fibrous pseudotumor, periarteritis of coronary arteries, pulmonary hyaline nodules, or sclerosing cholangitis.

We do not yet know if these are associated entities or components of a systemic fibrotic disease. Associations with ankylosing spondylitis, systemic lupus erythematosus, systemic sclerosis, Wegener granulomatosis, and polyarteritis nodosa have also been described.

In the early stages of retroperitoneal fibrosis, the plaque contains highly vascular tissue, with deposition of collagen and infiltrates of polyclonal B and CD4⁺ T cells, plasma cells, macrophages, and histiocytes. The inflammatory tissue is gradually replaced by fibrosis. Rarely, vasculitic lesions may be found in the retroperitoneal mass. Severe aortic atherosclerosis and damage to the aortic media with protrusion of atheromatous debris into the adventitia is usually but not always present. The periaortic infiltrate in idiopathic retroperitoneal fibrosis is indistinguishable from that of inflammatory abdominal aortic aneurysm.

■ CAUSES

In idiopathic retroperitoneal fibrosis, inflammation starts in the area of the most severe atherosclerosis of the aorta. A local immune response to products of atheromatous plaques is suspected. Ceroid, an insoluble polymer of oxidized lipids and protein, appears to be the target antigen; it is detected in the necrotic base of the atherosclerotic plaques, adventitial macrophages, and regional lymph nodes. Circulating antibodies to ceroid are present in

more than 90% of patients with retroperitoneal fibrosis vs 60% of elderly controls and 0% of young controls.⁴ Increased production of cytokines such as interleukin-1, interleukin-2, and interferon-gamma is presumed to mediate the chronic inflammation and fibrosis.⁵

■ CLINICAL FEATURES

Most patients (80%) present with dull, poorly localized pain in the back, flank, or abdomen. Weight loss, anorexia, nausea, vomiting, and malaise are less frequent. Rarely, claudication, ureteral colic, hematuria, or Raynaud phenomenon is reported. The physical findings include hypertension (in 50% of cases), mild fever, abdominal or rectal mass, lower extremity edema, hydrocele, decreased lower extremity pulses, and, rarely, jaundice. Varying degrees of ureteral obstruction with hydronephrosis and renal insufficiency are the earliest and most common organ involvement. Venous thromboembolism occurs in up to 25% of cases. Small bowel or colon involvement causes intestinal obstruction or pseudo-obstruction. Retroperitoneal fibrosis may extend to the spinal canal, and cord compression may develop.

■ DIAGNOSIS

Diagnosis of retroperitoneal fibrosis requires a high degree of suspicion. An elevated sedimentation rate is found in 80% to 90% of patients. Mild normochromic normocytic anemia, increased creatinine, and polyclonal hypergammaglobulinemia are also common. Intravenous pyelography (IVP) typically shows ureters pulled toward the midline and various degrees of hydronephrosis, but these findings are not specific for retroperitoneal fibrosis. Retrograde pyelography is a useful diagnostic procedure in patients with contraindications to intravascular contrast media and allows detailed assessment of the renal excretory system.

CT is the most frequently used imaging method in patients with suspected retroperitoneal fibrosis. A periaortic soft tissue mass enveloping the aorta and the inferior vena cava between the renal hila and the sacral promontory is the usual CT finding.

Sedimentation rate is elevated in 80% to 90% of patients



Magnetic resonance imaging (MRI) is emerging as the diagnostic method of choice. It allows multiplanar imaging and better vascular definition and does not require iodinated intravenous contrast. The intensity of the retroperitoneal plaque is different from that of muscle or adipose tissue on T1 and T2 images. Thus, MRI provides an excellent assessment of the extent of the disease. CT contrast enhancement and high signal intensity on T2 images are reported to correlate with the degree of inflammation and may be used to guide the biopsy and assess the effect of therapy. Angiography or magnetic resonance angiography may also be needed.

■ DIFFERENTIAL DIAGNOSIS

The differential diagnosis of idiopathic retroperitoneal fibrosis includes secondary retroperitoneal fibrosis due to malignancy, infection, retroperitoneal injury, and adverse effects of drugs (TABLE 1). Because current imaging techniques cannot differentiate idiopathic retroperitoneal fibrosis from secondary retroperitoneal fibrosis due to malignancy, infection, or other causes, biopsy is required for histologic confirmation. Open, multiple deep biopsy is preferred, but laparoscopic biopsy may be appropriate in some cases. The choice of biopsy technique depends on many factors: eg, the size and anatomical location of the mass, CT or MRI evidence of active inflammation, the overall estimated risk of malignancy, the surgeon's level of experience, and patient preferences.

■ PROGNOSIS

The natural history of retroperitoneal fibrosis is not well studied. Different rates of progression have been reported. Complete resolution of the process without therapy is rare. Renal insufficiency resolves or improves significantly in the majority of treated patients, regardless of whether treatment is surgical or medical. However, recurrences after surgical, medical, or combined treatment are not uncommon.

The prognosis is guarded and depends on the severity of atherosclerosis. A diagnosis of retroperitoneal fibrosis, in itself, does not reduce life expectancy.

TABLE 1

Causes of retroperitoneal fibrosis

Malignancy

- Cancer metastases (breast, lung, gastrointestinal, genitourinary, thyroid)
- Lymphoma
- Sarcoma
- Carcinoid

Inflammatory periaortitis

- Abdominal aortic aneurysm

Drugs

- Methysergide
- Bromocriptine
- Beta-blockers
- Methyldopa
- Hydralazine

Retroperitoneal injury

- Hemorrhage
- Radiation
- Ruptured abdominal organ
- Urinary extravasation
- Instrumentation

Infection

- Histoplasmosis
- Tuberculosis
- Actinomycosis

Miscellaneous

- Mesenteric panniculitis
- Weber-Christian panniculitis

■ GOALS OF MANAGEMENT

Prompt diagnosis of retroperitoneal fibrosis helps preserve renal function, prevent other organ involvement, and relieve symptoms. Evaluating symptoms, testing plasma levels of acute-phase reactants such as C-reactive protein, and imaging are used to monitor treatment. The results of biopsy do not correlate well with treatment response because of the inherent heterogeneity of the process.

In the late stages of retroperitoneal fibrosis, the mass becomes mostly fibrous and is less likely to shrink with medical therapy. Still, we have no evidence that the goal of treatment should be complete disappearance of the mass. If the mass does not decrease significantly or recurs, a repeat biopsy is required to rule out malignancy or infection. Recurrences may be controlled with the same drug, but additional

Over time,
the mass
becomes less
likely to shrink
with medical
therapy

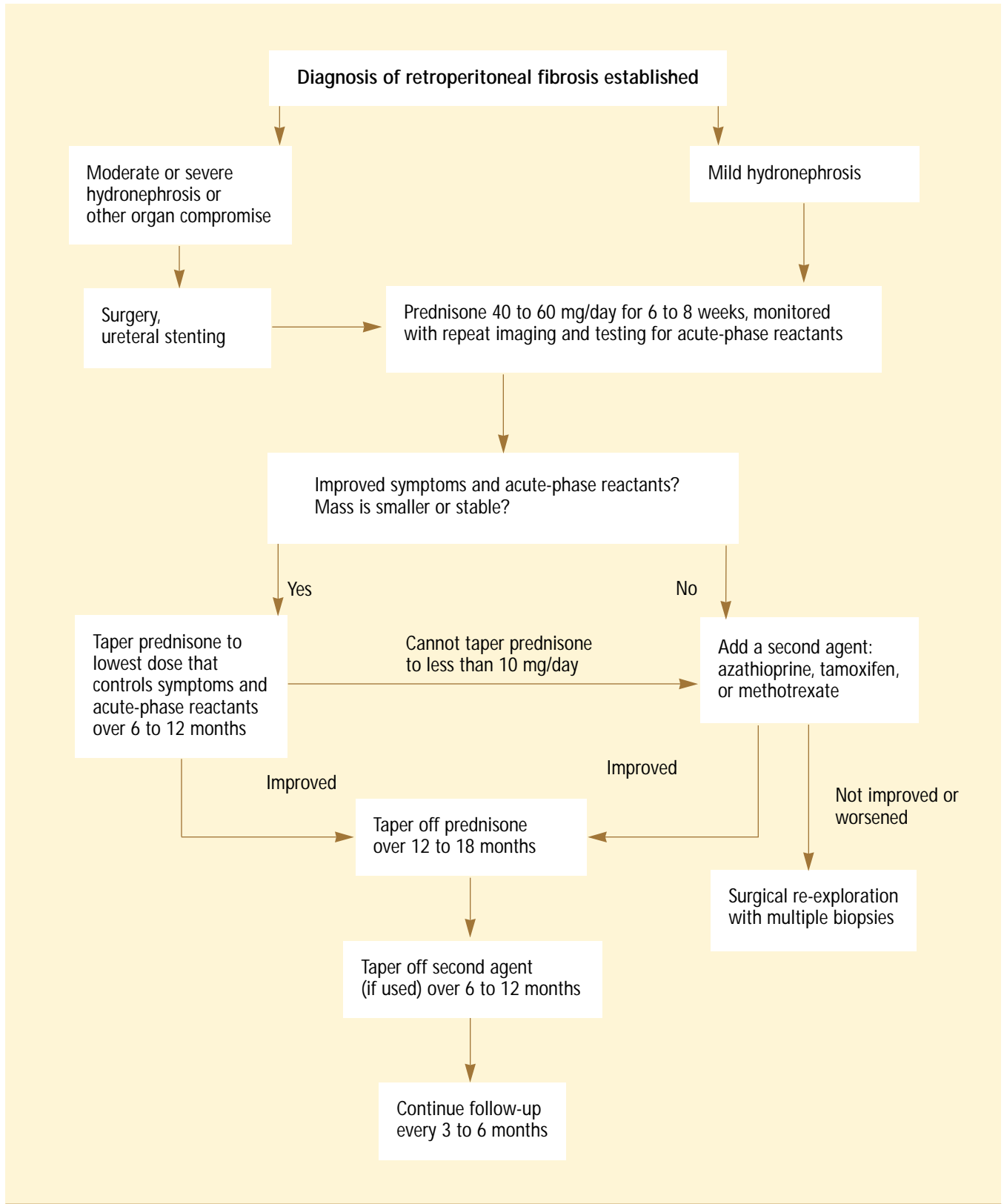


FIGURE 3. Algorithm of medical management of retroperitoneal fibrosis



drugs are often required (FIGURE 3).

No surgical or medical treatment has been tested in a controlled trial. The following discussion is based on case reports.

Surgery

Surgery confirms the diagnosis and is required in cases with severe ureteral or other organ involvement. The procedure of choice is ureterolysis (freeing the ureter from fibrotic adhesions) with lateral transposition and wrapping of the ureters with omentum. Cystoscopically placed ureteral stents are more frequently used and often obviate the need for open surgery. Patients with early retroperitoneal fibrosis or mild manifestations may be treated with drugs only.

Drug therapy

Corticosteroids are usually effective in suppressing the inflammatory process in retroperitoneal fibrosis, particularly in its early stages. The first reported use of corticosteroids in retroperitoneal fibrosis was by Ross and Tinckler in 1958.⁶ Corticosteroids may be used alone or in combination with other agents or surgery. In a large retrospective series, corticosteroid use combined with surgery resulted in a reduction of ureteral restenosis from 48% to 10%.⁷ However, steroids are not uniformly effective; unacceptably high doses may be required to control retroperitoneal fibrosis. After steroid therapy is stopped, relapses are not infrequent. A typical regimen is prednisone at 40 to 60 mg/day tapered to 10 mg/day within 2 to 3 months and gradually discontinued after 1 to 2 years. This regimen is similar to that used in giant cell arteritis.

Another regimen is a "pulse" dose of methylprednisolone (1 g/day intravenously for 3 days), which has been used along with azathioprine.⁸

Immunosuppressive drugs. Azathioprine has been used either when retroperitoneal fibrosis is unresponsive to corticosteroids or as a steroid-sparing agent.⁷⁻⁹ In most reported cases of azathioprine use, prednisone was given concomitantly, so differentiating the effect of each is difficult. McDougal and MacDonell¹⁰ reported the successful treatment of advanced renal impairment in a 14-

year-old girl with a combination of azathioprine 75 mg/day and prednisolone 50 mg/day tapered gradually over 20 months. Cogan and Fastrez¹¹ reported the use of azathioprine alone in a recurrence of retroperitoneal fibrosis after prednisone taper. Methotrexate 7.5 mg/week was reported to provide excellent long-term control in one patient.¹² Cyclophosphamide has been used in combination with steroids,¹³ but its effect is difficult to ascertain. It may be useful in severe cases, especially if vasculitis is present in the retroperitoneal mass.

Tamoxifen. The efficacy of the selective estrogen receptor modulator tamoxifen in pelvic desmoid tumors prompted its use in retroperitoneal fibrosis, even though, unlike desmoid tumors, the retroperitoneal tissue of retroperitoneal fibrosis contains no estrogen receptors. A number of these cases have been reported,¹⁴⁻²³ and two series were reported as abstracts.^{24,25} In the larger of the two,²⁴ nine patients on tamoxifen alone improved, and two of three patients on a combination of tamoxifen and corticosteroids improved. Only 1 of 13 patients worsened and one remained stable.²⁴

My colleagues and I reported mixed results in a series of four patients.²⁵ Two of the patients were treated with tamoxifen alone and two with concomitant corticosteroids. One patient in each group worsened clinically despite unchanged or modestly improved CT scans or plasma levels of acute-phase reactants. The other two patients remained stable during the period of observation (8 months, 2 years).²⁵

Tamoxifen appears to be effective in a significant proportion of reported cases. However, a positive reporting bias cannot be excluded. In addition, the adverse effects of tamoxifen, especially an increased risk of thromboembolism and ovarian cancer, have to be considered carefully for each patient. The place of tamoxifen in the treatment of retroperitoneal fibrosis remains to be defined.


Several possible mechanisms for the effectiveness of tamoxifen in retroperitoneal fibrosis have been proposed. Tamoxifen inhibits protein kinase C, an obligatory mediator of cell proliferation. It also increases apoptosis and production of transforming growth factor beta-1.²⁶

Steroids suppress the inflammation, particularly in the early stages



Recurrences are asymptomatic, follow-up is essential

Since recurrences of retroperitoneal fibrosis are often asymptomatic, careful long-term follow-up is mandatory. No published guidelines or cost-effective comparisons of different protocols exist. During the acute phase of the disease, blood counts, tests for plasma levels of acute-phase reactants, and renal function tests

are performed every 4 to 8 weeks. If immunosuppressive agents are used, more frequent laboratory monitoring is required. Abdominal CT with intravenous contrast or MRI may be repeated every 2 to 3 months. Intravenous pyelography or ultrasound may be used to monitor hydronephrosis. After achieving remission or stabilization of the disease, follow-up testing every 3 to 6 months is appropriate. 

REFERENCES

1. Albarran J. Rétention rénale par périurétérite. Libération externe de l'uretère. *Assoc Fr Urol* 1905; 9:511-517.
2. Ormond JK. Bilateral ureteral obstruction due to envelopment and compression by an inflammatory retroperitoneal process. *J Urol* 1948; 59:1072-1079.
3. Von Fritschen U, Maltzfeld E, Clasen A, Kortmann H. Inflammatory abdominal aortic aneurysm: a postoperative course of retroperitoneal fibrosis. *J Vasc Surg* 1999; 30:1090-1098.
4. Parums DV, Chadwick DR, Mitchinson MJ. The localization of immunoglobulin in chronic periaortitis. *Atherosclerosis* 1986; 61:117-123.
5. Ramshaw AL, Roskell DE, Parums DV. Cytokine expression in aortic adventitial inflammation associated with advanced atherosclerosis (chronic periaortitis). *J Clin Pathol* 1994; 47:721-727.
6. Ross J, Tinckler L. Renal failure due to periureteric fibrosis. *Br J Surg* 1958; 46:58-62.
7. Wagenknecht LV, Hardy JC. Value of various treatments for retroperitoneal fibrosis. *Eur Urol* 1981; 7:193-200.
8. Harreby M, Bilde T, Helin P, Mayhoff H, Vinterberg H, Nielsen VH. Retroperitoneal fibrosis treated with methylprednisolone pulse and disease-modifying antirheumatic drugs. *Scand J Urol Nephrol* 1994; 28:237-242.
9. Littlejohn JO, Keystone EC. The association of retroperitoneal fibrosis with systemic vasculitis and HLA-B27: a case report and review of the literature. *J Rheumatol* 1981; 8:665-669.
10. McDougal WS, MacDonell RC. Treatment of idiopathic retroperitoneal fibrosis by immunosuppression. *J Urol* 1991; 145:112-114.
11. Cogan E, Fastrez R. Azathioprine. An alternative treatment for recurrent idiopathic retroperitoneal fibrosis. *Arch Intern Med* 1985; 145:753-755.
12. Scavalli AS, Spadaro A, Ricciari V, et al. Long-term follow-up of low-dose methotrexate therapy in one case of idiopathic retroperitoneal fibrosis. *Clin Rheumatol* 1995; 14:481-484.
13. Kaipainen-Seppanen O, Jantunen E, Kuusisto J, Marin S. Retroperitoneal fibrosis with antineutrophil cytoplasmic antibodies. *J Rheumatol* 1996; 23:779-781.
14. Clark CP, Vanderpool D, Preskitt J. The response of retroperitoneal fibrosis to tamoxifen. *Surgery* 1991; 109:502-506.
15. Loffeld RJLF, van Weel TF. Tamoxifen for retroperitoneal fibrosis. *Lancet* 1993; 341:382.
16. Duffy TP. Clinical problem solving: an anatomy lesson. *N Engl J Med* 1994; 331:318-320.
17. Owens LV, Cance WG, Huth JF. Retroperitoneal fibrosis treated with tamoxifen. *Am Surg* 1995; 61:842-844.
18. Spillane RM, Whitman GJ. Treatment of retroperitoneal fibrosis with tamoxifen. *AJR* 1995; 164:515-516.
19. Tonietto G, Agresta F, Della Libera D, Bittesini L. Treatment of idiopathic retroperitoneal fibrosis by tamoxifen. *Eur J Surg* 1997; 163:231-235.
20. Ozener C, Kiris S, Lawrence R, Ilker Y, Akoglu E. Potential beneficial effect of tamoxifen in retroperitoneal fibrosis. *Nephrol Dial Transplant* 1997; 12:2166-2168.
21. Bourouma R, Chevet D, Michel F, Cercueil JP, Arnould L, Rife G. Treatment of retroperitoneal fibrosis with tamoxifen. *Nephrol Dial Transplant* 1997; 12:2407-2410.
22. Frankart L, Lorge F, Donkier J. Tamoxifen for retroperitoneal fibrosis. *Postgrad Med J* 1997; 73:653-654.
23. Al-Musawi D, Mitchener P, Al-Akara M. Idiopathic retroperitoneal fibrosis treated with tamoxifen only. *Br J Urol* 1998; 82:442-443.
24. Wilson JL, Proven A, Yacyshyn EA, Griffing L, Luthra HS. Clinical features and response to tamoxifen therapy in patients with retroperitoneal fibrosis. *Arthritis Rheum* 2000; 43(suppl):1385.
25. Monev S, Remer E, Calabrese L. Effect of tamoxifen in patients with idiopathic retroperitoneal fibrosis. *Arthritis Rheum* 1998; 41(suppl):419.
26. Grainger DJ, Metcalfe JC. Tamoxifen: teaching an old drug new tricks? *Nature Med* 1996; 2:381-385.

ADDRESS: Stefan Monev, MD, University Hospital and Clinics-Holmes County, 675 Northwest Avenue, Durant, MS 39063.