



JOHN R. QUEEN, MD

Department of Emergency Medicine,
The Cleveland Clinic

JONATHAN GLAUSER, MD

Department of Emergency Medicine,
The Cleveland Clinic

A young man with hyperthermia and new-onset seizures

A 22-YEAR-OLD MAN presents to the emergency department. He describes having had what sounds like a grand mal seizure while traveling on a bus from Chicago to Cleveland. He was returning from a vacation in the Bahamas and had flown from the Bahamas to Chicago.

He has no previous medical diagnoses and is currently taking no medications. He has smoked 1 pack of cigarettes a day for the past 4 years, says he “drinks socially,” and denies any illicit drug use. His sister, who accompanied him to the emergency room, says she is unaware of any history of seizure or of any recent injury.

Physical examination

His temperature is 103.5°F (39.7°C), pulse rate 120, respiratory rate 20, blood pressure 200/115 mm Hg, and oxygen saturation 100% by pulse oximetry while breathing room air.

He appears generally healthy, though he seems somewhat anxious. He is alert and is oriented to person, time, and place. His muscle strength is 5 on a scale of 5 in all major muscle groups. Cranial nerves II through XII are intact, there is no nystagmus, and extraocular muscle movements are normal. The Kernig and Brudzinski signs are absent. Bilateral sensation is intact, and his gait is normal.

His skin is warm and flushed, and he has no needle track marks. The pupils are 8 mm, equal, and sluggishly reactive to light. Funduscopic examination reveals normal, flat optic discs with normal venous pulsations. His neck is supple. His heart has a regular rhythm with tachycardia; no murmur, gallops, or rubs are noted. His lungs are clear to auscultation, and his abdomen is soft and nontender, with

normal bowel sounds and no hepatosplenomegaly. On rectal examination, the stool is negative for occult blood, there are no masses, and sphincter tone is normal.

Laboratory studies

Initial laboratory studies reveal a white blood cell count of $11.8 \times 10^9/L$ (normal 4–11) with 88% neutrophils (normal 40%–70%). The hemoglobin level is 16.4 g/dL (normal 12.0–16.0). Serum levels of sodium, potassium, chloride, carbon dioxide, blood urea nitrogen, creatinine, and glucose, as well as urinalysis values, are all within normal limits.

Seizure occurs in the emergency department

Initially, the patient was alert and was responding to questions in the emergency department. However, 30 minutes after his arrival, he became agitated, developed a grand mal seizure, and became cyanotic. The seizure lasted approximately 4 minutes and required 4 mg of lorazepam before termination.

DIFFERENTIAL DIAGNOSIS

1 Which of the following is the most likely cause of seizure in this hyperthermic patient?

- Bacterial meningitis
- Salicylate toxicity
- Cocaine toxicity
- Anticholinergic poisoning
- Sedative hypnotic withdrawal

Bacterial meningitis. Acute bacterial meningitis is usually due to infection by pyogenic bacteria that results in inflammation of the arachnoid and pia mater with involve-

See related
editorial,
page 465

ment of the cerebrospinal fluid. A subacute course can occur in rare cases as a result of infection by nonpyogenic bacteria. From 20% to 30% of patients with bacterial or viral meningitis will have one or more seizures during their illness.¹

The most common route of entry into the cerebrospinal fluid is hematogenous. Patients at increased risk for developing acute bacterial meningitis include those who are taking immunosuppressants or who have an immune globulin deficiency, a complement deficiency, asplenia, or splenic dysfunction.

Salicylate toxicity. Acute salicylate poisoning usually occurs in younger patients who intentionally overdose as a suicide attempt. Unless confounded with the ingestion of other substances, the presentation includes initial clinical findings of nausea, vomiting, agitation, and hallucinations, which may progress quickly to seizure, stupor, and coma.

Chronic salicylate toxicity is usually seen in elderly patients who unintentionally overdose; it is more difficult to identify and is frequently misdiagnosed as sepsis.

In either case, the classic acid-base disturbance is a metabolic acidosis with respiratory alkalosis from direct stimulation of respiratory centers in the brain. However, persistent emesis may result in metabolic alkalosis, and respiratory compromise may cause respiratory acidosis, which is a grave sign.

Cocaine toxicity. Due to the increasing use of cocaine in the United States, the incidence of emergency department visits, hospitalizations, and deaths from cocaine overdose is escalating. The first symptom of cocaine intoxication is typically dysphoric agitation, which may be followed by hypertension, hyperthermia, confusion, seizure, and coma. The treatment is typically supportive, and benzodiazepines are invaluable in decreasing the sympathetic effects and the seizures. Typically, the symptoms of cocaine overdose are self-limited and resolve within 24 hours.²

Anticholinergic poisoning. Anticholinergic substances include many prescription and over-the-counter medications, as well as some plants and mushrooms. The syndrome of anticholinergic toxicity is characterized by hyperthermia, mydriasis, dry skin, flushing, and confusion. These findings are easily

remembered by the phrases *hot as a hare, blind as a bat, dry as a bone, red as a beet, and mad as a hatter*. Other signs and symptoms include tachycardia, hypertension or hypotension, urinary retention, decreased gastrointestinal motility, and seizures. The diagnosis of anticholinergic poisoning is based on clinical signs and symptoms, and laboratory studies are useful only to rule out other possible causes. Therapy is largely supportive. The use of physostigmine is highly controversial.

Sedative hypnotic withdrawal. The most common sedative withdrawal syndrome that includes hyperthermia and seizures is delirium tremens. Alcohol withdrawal may be minor, with few hemodynamic derangements, or it may be severe, with agitation, confusion, hyperthermia, and hypertension. Most seizures related to alcohol withdrawal occur in minor withdrawal, though they may be seen in major withdrawal or full-blown delirium tremens. Long-acting benzodiazepines are the treatment of choice.

Barbiturate withdrawal symptoms include hypertension, tachycardia, hyperthermia, agitation, hallucinations, nausea, vomiting, and seizures. Treatment is supportive, with phenobarbital intravenously until symptoms resolve.

At this point, all of the above are considered possible causes; however, cocaine toxicity is the most likely, based on the physical examination.

■ ADDITIONAL TESTING CONSIDERED

2 Which test would not be useful in this case?

- Urine toxicology screen
- Blood toxicology screen
- Computed tomography (CT) of the head
- Cerebrospinal fluid analysis
- Serum ethanol measurement
- Electrocardiography
- Emergency electroencephalography

Because the patient had a witnessed seizure in the emergency department, and because the seizures are likely due to a treatable or self-limiting condition (eg, toxic ingestion, infection, withdrawal state), emergency electroencephalography is not useful. The remainder of the workup was as follows:

The patient appeared healthy, but seemed anxious

Urine toxicology screen was positive for cocaine and marijuana and negative for opiates, phencyclidine, barbiturates, and benzodiazepines.

Blood toxicology screen was negative for salicylates, acetaminophen, and tricyclic antidepressants.

CT of the head (without contrast) showed no bleeding, atrophy, significant mass, mass effect, or infarction.

Serum ethanol level was negative.

Electrocardiography revealed sinus tachycardia with a rate of 119, a PR interval of 116 ms, a QRS duration of 80 ms, and a normal QT/QTc interval.

Cerebrospinal fluid studies showed two red blood cells, no white blood cells, and no microorganisms on Gram stain. The cerebrospinal protein and glucose levels were within normal limits.

■ EMERGENCY DIAGNOSTIC WORKUP FOR SEIZURE

The suggested diagnostic workup in the emergency room is quite different in a patient with a history of seizure disorder than in the patient with seizure of new onset. Our patient had no history of seizure until the time of the apparent seizure on the bus, was not taking anticonvulsant medications, and had no history of ethanol abuse.

The American College of Emergency Physicians supports the use of CT in the evaluation of all first-time seizures of unknown cause.³ Predictors of an abnormal CT scan in patients with seizure of new onset include recent head trauma, abnormal neurologic findings, multiple seizures, focal seizure, or a history of central nervous system disorder or malignancy.⁴ CT may also be useful in patients who are taking an anticoagulant or who have a history of alcohol abuse. Alcohol abusers are more likely to have serious intracranial bleeding due to undiagnosed coagulopathy or to minor or undocumented head trauma.

Evidence indicates that most laboratory testing does not help in the emergency evaluation of adult-onset seizure.⁵ Serum electrolytes, blood urea nitrogen, creatinine, magnesium, calcium, and glucose measure-

ments, prothrombin time, and complete blood count are part of a “standard” laboratory evaluation. Alcohol and toxicology screening would be reasonable in any patient with no known predisposing factors. The white blood cell count seldom influences emergency therapy, as it is often elevated due to seizure, regardless of the cause. In several reports, no central nervous system infections were found that were suggested by an abnormal white cell count alone, and it had no significant impact on the diagnosis or management in any of their cases.^{6–10}

Testing for hyponatremia, hypoglycemia, hypocalcemia, hypercalcemia, or hypernatremia is seldom helpful unless a metabolic abnormality is suspected from the history and clinical data. Serum magnesium testing is rarely helpful unless hypomagnesemia is strongly suspected, as in diabetic ketoacidosis or alcohol abuse.^{6,11}

Experts urge testing drug levels of anticonvulsants in patients taking them: in one report,⁶ 88% of patients taking anticonvulsants were found to have subtherapeutic serum levels. In many patients, this is the only laboratory test necessary. Nonalcoholic patients with recurrent seizures and an otherwise normal medical history do not require an extensive metabolic workup.

Our patient did not have nuchal rigidity, petechiae, or persistent drowsiness, all of which would suggest infection and would mandate a lumbar puncture. He underwent a lumbar puncture to rule out bacterial meningitis because he was febrile and had new-onset seizures.

Electroencephalography may be indicated in some patients but is seldom available or necessary in the emergency setting.

Personal belongings reveal diagnostic clues

Examination of the patient’s belongings by accompanying family and emergency department staff revealed enemas, various over-the-counter laxatives, and figs. The presence of laxatives and enemas prompted abdominal radiography (FIGURE 1).

Confronted with the results of the urine toxicology test, the other studies, and the search of his personal belongings, the patient admitted to illegally transporting cocaine into

Symptoms of cocaine overdose usually resolve within 24 hours



the United States. He said he swallowed 25 cocaine-filled balloons before flying into Chicago. While in Chicago, he took stool softeners and magnesium citrate to help him pass the balloons. He reports recovering 20 of the 25 balloons and was waiting for the 5 remaining balloons to pass.

These facts confirmed that the cause of this patient's seizures is cocaine toxicity.

■ TREATMENT OF COCAINE INTOXICATION

3 Which are appropriate treatments for this patient with cocaine intoxication?

- Lorazepam
- Nitroprusside
- Metoprolol

Lorazepam. As stated earlier, supportive care and benzodiazepines such as lorazepam are the cornerstone of therapy. Cocaine has no known antidote.

Nitroprusside was not needed in our patient, as he had no evidence of end-organ damage with improving hypertension.

Metoprolol. Beta-1 selective antagonists such as metoprolol are contraindicated in acute cocaine toxicity due to the risk of precipitating unopposed alpha-stimulation.

■ FEATURES OF SEIZURE IN COCAINE INTOXICATION

Convulsions associated with intranasal cocaine were first reported in 1922,¹² and seizures are considered a major cause of cocaine-related mortality in the United States.¹³ Nonetheless, cocaine-induced seizures are relatively rare and seldom progress to status epilepticus.¹⁴

Most seizures due to cocaine intoxication are single and tonic-clonic and resolve without intervention.¹⁵ These seizures usually are not associated with abnormalities on computed tomography or electroencephalography or with chronic sequelae. Seizures can be induced after an accidental massive overdose, as in "body packer syndrome,"^{16–18} as well as after the recreational use of relatively low doses of cocaine. (A "body packer" or "mule" is a person who smuggles illegal drugs past customs inspectors by carefully packaging small amounts in condoms, balloons, or finger cots,

The patient's radiograph

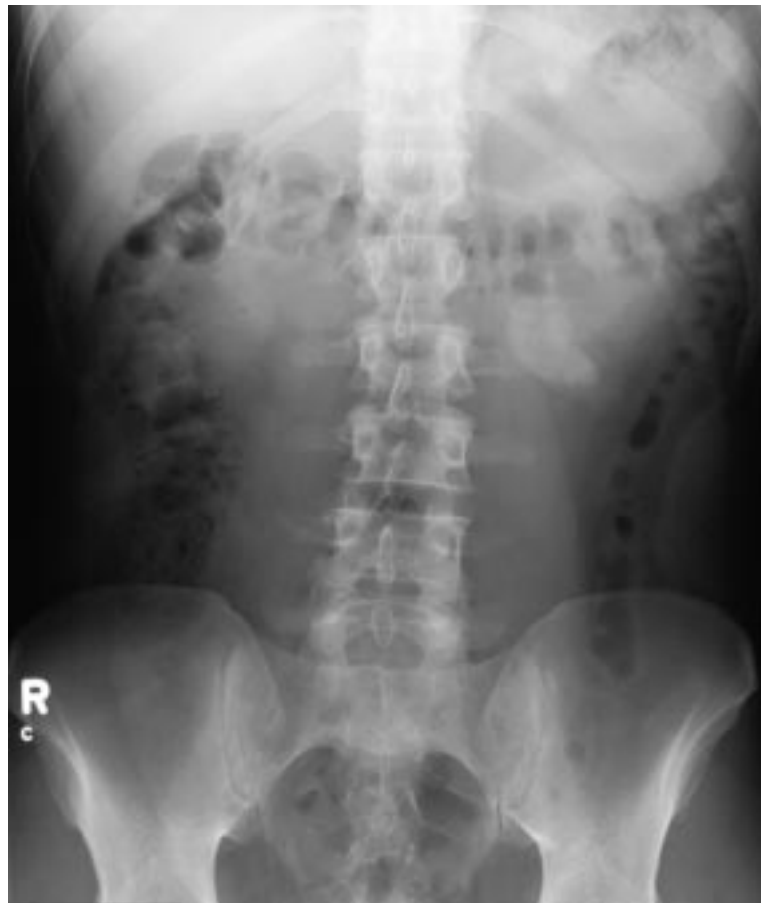


FIGURE 1. The patient's symptoms plus the finding of enemas and over-the-counter laxatives among the patient's belongings prompted the emergency department to obtain this abdominal radiograph.

then either ingesting them or inserting them rectally or vaginally.) The threshold for cocaine to precipitate seizures appears to decrease over time in cocaine abusers.

Seizures induced after a single, recreational dose of cocaine generally occur within 90 minutes of ingestion.^{19,20} Body packers and body stuffers (those who suddenly swallow evidence during drug raids, often in carelessly wrapped packets) are more likely to have recurrent seizures due to continued absorption of cocaine. Recreational cocaine use accounts for the vast majority of overdose-related seizures in the United States. Seizures are a major cause of death in cocaine poisoning, and prolonged seizures are often a preterminal event in cocaine poisoning.²¹



Case continued

After the initial dose of IV lorazepam, the patient had no further seizures in the emergency department. His blood pressure decreased to 182/94 mm Hg, and he remained tachycardic at 104 beats/minute without further therapy. His temperature remained elevated at 102.8°F (39.3°C) after receiving acetaminophen.

4 What is the appropriate treatment for this patient's hyperthermia?

- Rapid external cooling
- Dopamine-blocking neuroleptic drugs
- IV fluids and alkalization of the urine with sodium bicarbonate
- Hemodialysis

A number of prescription medications and illicit drugs are stimulants that may cause hyperthermia, which requires prompt treatment.

Dopamine-blocking neuroleptic drugs.

Since hyperthermia may be mediated by activation of dopamine receptors in the central nervous system, dopamine-blocking neuroleptic drugs have been proposed as a useful adjunct to current treatment regimens.²² These include chlorpromazine and the butyrophenones, such as haloperidol. Pharmacologically distinct D-1 and D-2 dopamine receptors have been identified, with the D-1 receptor the predominant mediator of the hyperthermic response in cases of psychostimulant poisoning.²³

Rapid cooling by spraying the exposed body surface with tepid water and by circulating air with fans is the preferred method of cooling patients with rectal temperatures above 40°C. Other methods include cooling blankets, immersion in iced water, iced saline lavage, or, in more severe cases, paralysis with mechanical ventilation. Successful cooling of patients with psychostimulant overdose and rectal temperatures above 40°C generally results in complete recovery.²⁴⁻²⁶

Dantrolene 1 mg/kg IV over 10 to 15 minutes has been used with variable rates of success^{24,27} in patients with hyperthermia refractory to standard treatment. At present, we lack sufficient evidence to recommend it in the treatment of cocaine-induced hyperthermia.

IV fluids and alkalization of the urine with sodium bicarbonate. Hyperthermia puts the patient at risk of developing rhabdomyolysis, which in animal studies is known to be potentially lethal. When rhabdomyolysis occurs in patients with cocaine intoxication, IV fluids and alkalization of the urine with sodium bicarbonate are indicated. Associated electrolyte abnormalities (eg, hyperkalemia) and abnormalities in calcium and phosphate metabolism must also be identified and treated.²² In rare cases, hemodialysis may be required.

Case continued

Rapid external cooling measures were started, including removal of clothing and cool mist water sprays with a fan. Radiography showed three cocaine-filled balloons. Since his history indicated five balloons still unaccounted for, a decision on removal of the balloons needed to be made.

5 What is the best way to remove the cocaine-filled balloons?

- Endoscopic removal
- Cathartics
- Enemas
- Surgery
- Whole bowel irrigation

Endoscopic removal. Attempted endoscopic removal of ingested cocaine-filled condoms has caused rupture of the condoms with sudden clinical deterioration necessitating emergency surgery,²⁸ so this approach is generally not recommended.²⁷

Cathartics such as psyllium, sodium sulfate, and bisacodyl suppositories may be useful. Oral activated charcoal with sorbitol may help to limit gastrointestinal absorption if the patient has ingested unwrapped crack cocaine.²⁹

Enemas may not be advisable: agitation, diaphoresis, and tachycardia suddenly developed in one patient 1 hour after receiving a tap water enema in an attempt to retrieve three rubber condoms containing cocaine.³⁰ That patient had a seizure complicated by severe acidosis and idioventricular rhythm before passing three condoms, one of which had apparently ruptured during rectal insertion of the enema nozzle.

Body packers use condoms, balloons, finger cots

Surgery. Immediate surgery was recommended by some when body packing was first described in 1977.²⁸ Currently, however, surgery is indicated only if the bowel is obstructed. If there is no obstruction and the risk of packet rupture is thought to be low (due to the packaging method), medical therapy is effective and acceptable.¹⁶ Furthermore, medical management is more likely to be successful if patients willingly receive treatment in a monitored setting. If there is any deterioration in status, however, immediate surgical intervention is indicated.¹⁶

As many as 88 intact balloons and 2 broken ones have been removed surgically from the gastrointestinal tract of a single body packer.¹⁷ In one report,¹⁷ only 3 of 50 patients required emergency surgery, with packets passing within a mean of 27.7 hours. Surgery was precipitated by signs of bowel obstruction in all cases.

Whole bowel irrigation. The patient underwent whole bowel irrigation with polyethylene glycol and was admitted to the observation unit. During the observation period, the remaining five balloons passed, and he had no further seizure activity. His hypertension improved but did not resolve, with systolic blood pressures between 156 and 188 mm Hg. The hyperthermia and tachycardia resolved, and he was discharged home in good condi-

tion the following day. The cocaine was turned over to the authorities.

■ THE COCAINE BODY PACKING SYNDROME

Body packer syndrome should be suspected in any international traveler who dies suddenly, has seizures, or presents with signs of cocaine toxicity. One body packer who died about 10 days after returning from Colombia was found to have one aluminum foil packet in his pylorus and a ruptured finger cot in his cecum.¹⁸

The risk of lethal toxicity varies with the body packing technique. For example, body stuffers are more likely to ingest leaky packages, and so they are at greater risk of toxicity. Condoms, balloons, and finger cots are susceptible to rupture, but since they are made of semipermeable membranes, they do not have to break for cocaine to leach out.³¹ Some packets are not visible on abdominal radiographs.³¹ Most of these patients are apprehended by customs officials at international airports and transferred to a hospital, but usually only after they develop complications.

Typically, body packers swallow numerous bags, each containing 3 to 6 g of cocaine. As many as 147 packets totaling 460 g have been described in one report,¹⁸ as well as 175 packets containing 5 to 7 g each³¹ and as many as 182 packets.¹⁷

■ REFERENCES

1. Segreti J, Harris A. Acute bacterial meningitis. *Infect Dis Clin North Am* 1992; 10:798–802.
2. Cregler LL, Mark H. Medical complications of cocaine abuse. *N Engl J Med* 1986; 315:1495–1500.
3. American College of Emergency Physicians. Clinical policy for the initial approach to patients with a chief complaint of seizure who are not in status epilepticus. *Ann Emerg Med* 1997; 29:706–724.
4. Turnbull TL, Howes DS, Eisner RF, et al. The utility of cranial computed tomography in adult patients with new onset seizures [abstract]. *Ann Emerg Med* 1988; 17:1120.
5. Bradford JC, Kyriakedes CG. Evaluation of the patient with seizures: an evidence-based approach. *Emerg Med Clin North Am* 1999; 17:203–220.
6. Eisner RF, Turnbull TL, Howes DS, et al. Efficacy of a “standard” seizure workup in the emergency department. *Ann Emerg Med* 1986; 15:33–39.
7. Sempere A, Villaverde F, Martinez-Menendez B, et al. First seizure in adults: a prospective study from the emergency department. *Acta Neurol Scand* 1992; 86:134–138.
8. Rosenthal RH, Helm ML, Waeckerle JF, et al. First-time major motor seizure in an emergency department. *Ann Emerg Med* 1980; 9:242–245.
9. Day SC, Cook EF, Funkenstein H, et al. Evaluation and outcome of emergency room patients with transient loss of consciousness. *Am J Med* 1982; 73:15–22.
10. Turnbull TL, Vanden Hoek TL, Howes DS, et al. Utility of laboratory studies in the emergency department patient with new onset seizure. *Ann Emerg Med* 1990; 19:373–377.
11. Powers RD. Serum chemistry abnormalities in adult patients with seizures. *Ann Emerg Med* 1985; 14:416–420.
12. Pulay E. Cocaine poisoning. *JAMA* 1922; 78:1855.
13. Spivey WH, Euerle B. Neurologic complications of cocaine abuse. *Ann Emerg Med* 1990; 19:1422–1428.
14. Casas PI, Gatto E, Fernandez PMM, et al. Neurologic complications of cocaine abuse. *Medicina* 1994; 54:35–41.
15. Lowenstein DH, Massa SM, Rowbotham MC, Collins SD, McKinney HE, Simon RP. Acute neurologic and psychiatric complications associated with cocaine abuse. *Am J Med* 1987; 83:841–846.
16. Trent MS, Kim U. Cocaine packet ingestion: surgical or medical management? *Arch Surg* 1987; 122:1179–1181.
17. Caruana DS, Weinbach B, Goerg D, Gardner LB. Cocaine-packet ingestion. *Ann Intern Med* 1984; 100:73–74.



18. **Wetli CV, Mittleman RE.** The "body packer" syndrome: toxicity following ingestion of illicit drugs packaged for transportation. *J Forens Sci* 1981; 26:492–500.
19. **Van Dyke C, Byck R.** Cocaine. *Sci Am* 1982; 246:128–141.
20. **Pascual-Leone A, Dhuna A, Altafullah I, Anderson DC.** Cocaine-induced seizures. *Neurology* 1990; 40:404–407.
21. **Mittelman RE, Wetli CV.** Death caused by recreational cocaine use. *JAMA* 1984; 252:1889–1893.
22. **Callaway CW, Clark RF.** Hyperthermia in psychostimulant overdose. *Ann Emerg Med* 1994; 24:68–76.
23. **Kosten TR, Kleber HD.** Rapid death during cocaine abuse: a variant of the neuroleptic malignant syndrome? *Am J Drug Alcohol Abuse* 1988; 14:335–346.
24. **Rosenberg J, Pentel P, Pond S, Benowitz N, Olson K.** Hyperthermia associated with drug intoxication. *Crit Care Med* 1986; 14:964–969.
25. **Roberts JR, Quattrochi E, Howland MA.** Severe hyperthermia secondary to intravenous drug abuse. *Am J Emerg Med* 1984; 2:373.
26. **Merigan KS, Roberts JR.** Cocaine intoxication: hyperpyrexia, rhabdomyolysis, and acute renal failure. *Clin Toxicol* 1987; 25:135–148.
27. **Beck NE, Hale JE.** Cocaine "body packers." *Br J Surg* 1993; 80:1513–1516.
28. **Suarez C, Arango A, Lester L.** Cocaine-condom ingestion. *JAMA* 1977; 237:1391–1392.
29. **Riggs D, Weibley RE.** Acute toxicity from oral ingestion of crack cocaine: a report of four cases. *Ped Emerg Care* 1990; 6:24–26.
30. **Jonsson S, Omeara M, Young JB.** Acute cocaine poisoning: importance of treating seizures and acidosis. *Am J Med* 1983; 75:1061–1064.
31. **McCarron MM, Wood JD.** The cocaine "body packer" syndrome. *JAMA* 1983; 250:1417–1420.

ADDRESS: John R. Queen, MD, Department of Emergency Medicine, E19, The Cleveland Clinic Foundation, 9500 Euclid Avenue, Cleveland, OH 44195; e-mail queenj@ccf.org.