

SUBACUTE MENINGOMYELITIS SIMULATING SPINAL CORD TUMOR

Report of a Case

A. T. BUNTS, M.D.

Inasmuch as surgery is the primary form of treatment of spinal cord tumors, but is definitely contraindicated in the presence of inflammatory or degenerative lesions of the cord, it seems worthwhile to review the case of a patient who died soon after a laminectomy for suspected spinal cord tumor. This clinical diagnosis proved to be wrong, and post-mortem examination revealed a definite subacute meningomyelitis. The operation undoubtedly hastened the patient's death, and for that reason, in spite of the apparent justifiability of laminectomy as viewed in retrospect, the clinical features of the case deserve a searching analysis in order to determine if possible the reasons for the erroneous diagnosis and thus to avoid surgery in similar cases in the future.

CASE REPORT

Chief complaint—The patient, a 53 year old white housewife, who had been in previous good health except for menopausal symptoms, stated that during the year prior to coming to the Clinic she had experienced occasional pain between the shoulder blades radiating around the chest to its anterior aspect. The pain was more noticeable at night. No other symptoms were noted until eleven weeks before entrance to the Clinic, when she felt a sudden pain in the lower back while stooping over; this pain lasted for two or three days. During the next two weeks her legs gradually became numb and stiff, more markedly so on the right side. She began to stumble and fall when she walked, she was unable to feel a hypodermic needle in her leg, and she burned her right leg without realizing it. The numbness of the legs gradually extended up the trunk to the arms and there was an "itchy" sensation across the breasts. Six weeks before entering the Clinic the patient lost control of the vesical and rectal sphincters. There was no history of fever or headache during the present illness.

Family history and past history were irrelevant to the present condition. There was no history of tuberculosis, influenza, or other infectious disease prior to the onset of the present illness.

General physical examination revealed a slender adult white woman in no apparent distress, perfectly conscious and cooperative. Temperature 98.6° F. Pulse rate 100 and regular. Blood pressure 120/84. There was no evidence of pulmonary, cardiac, or intra-abdominal disease.

Neurological examination. There was practically complete anesthesia below the fourth thoracic dermatome. Both legs were very weak, the right leg more so than the left leg. Abdominal reflexes were absent.

SUBACUTE MENINGOMYELITIS SIMULATING SPINAL CORD TUMOR

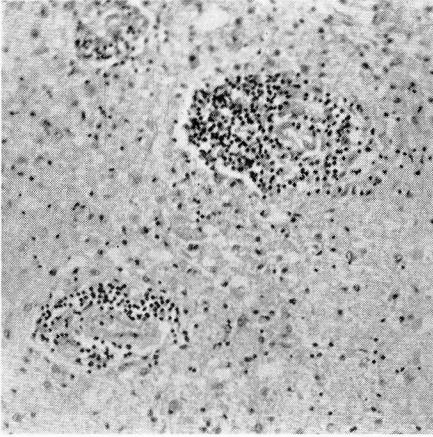


FIGURE 2: Photomicrograph of section from eighth cervical segment of spinal cord showing marked necrosis of the grey matter and extensive perivascular and parenchymatous infiltration with round cells. Hematoxylin and eosin stain. (x 150).

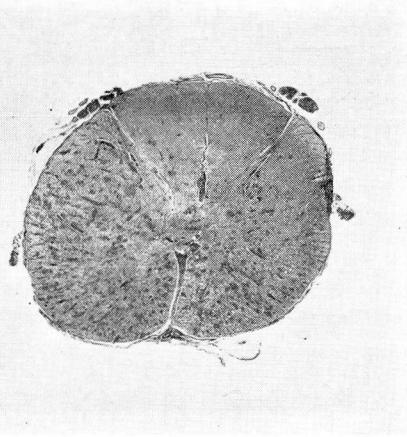


FIGURE 1: Section from eighth cervical segment of spinal cord showing degeneration of the long fiber tracts and extensive perivascular infiltration. Weigert myelin sheath stain.

Both patellar reflexes were hyperactive and there was a positive Babinski sign on both sides. The rectal sphincter was relaxed.

Roentgen examination of the thoracic spine showed no abnormal change.

Laboratory data. Urinalysis was negative except for a trace of albumin; red blood cells 5,550,000; white blood cells 6000; hemoglobin 91 per cent; blood sugar 95 mgm. per cent; and blood Wassermann and Kahn reactions were negative.

Lumbar puncture showed clear, colorless cerebrospinal fluid at an initial pressure of 130 mm. of water. There were no arterial pulsations in the column of fluid. The Queckenstedt test showed a very slow rise of the fluid level during jugular compression and a slower fall on release of jugular compression. These dynamic studies definitely indicated a partial spinal subarachnoid block.

Examination of the cerebrospinal fluid revealed a cell count of 22 lymphocytes per cubic millimeter, globulin negative, total protein content 275 mgm. per 100 cc., Wassermann reaction negative, colloidal gold reaction negative. No culture or smear of the fluid was made.

A tentative diagnosis of spinal cord compression at the fourth thoracic segment by an extramedullary tumor was made.

One cubic centimeter of heavy lipiodol was injected into the cisterna magna and it failed to descend in the spinal subarachnoid space below the level of the third cervical vertebra.

Operation. Laminectomy was carried out from the third cervical

vertebra to the second thoracic vertebra inclusive. The dura appeared to be normal and when it was opened in the midline and held aside with traction sutures throughout the length of the exposure, there was found to be practically no cerebrospinal fluid in the subarachnoid space. There were numerous adhesions between the arachnoid and the pia and between the arachnoid and the dura throughout the exposure. Many of the pia-arachnoidal adhesions were separated by means of forceps, and high up beneath the first and second cervical vertebrae the cerebrospinal fluid appeared to be imprisoned in loculations or adhesions of the arachnoid. After freeing some of the adhesions, a small amount of fluid together with globules of lipiodol escaped. The arteries of the upper cervical cord appeared to be somewhat dilated and engorged. At the level of the eighth cervical and first thoracic segments, the cord was enlarged in fusiform fashion and filled the canal; there was no vascular engorgement at that level. No extramedullary tumor was found at any level of the exposure. Because it was thought that the fusiform swelling of the cord might be due to an intramedullary tumor or a cystic cavity, a hypodermic needle on a syringe was inserted through the posterior columns of the cord, but no fluid was obtained by aspiration. It was the operator's final impression that he was probably dealing with a meningomyelitis and that the adhesions which obstructed the free flow of cerebrospinal fluid in the subarachnoid space had been the cause of the partial block by Queckenstedt's test. The wound was closed, and because of the patient's low blood pressure at the end of the operation she was given a transfusion of 500 cc. of whole blood.

Postoperative course. *The patient did not react properly after operation and her blood pressure remained very low in spite of stimulation with caffeine and ephedrine and venoclysis. Because of periods of apnea the patient was placed in an oxygen tent. During the day after operation there was a gradually progressive cardiorespiratory failure, which failed to respond to any form of treatment, and the patient expired thirty-five hours after operation.*

Post-mortem examination. *The external surface of the brain appeared to be grossly normal and showed no evidence of meningitis. Gross transverse sections of the brain showed no abnormal changes. The entire spinal cord was removed and it presented some interesting features. At the level of the eighth cervical and first thoracic segments there was a well-marked, diffuse swelling of the cord which was soft in consistency. A transverse section of the cord at this level showed necrosis and a small area of hemorrhage about the central canal. The lumbar portion of the cord was much narrower than normally and presented an atrophic appearance. There were numerous adhesions between the arachnoid and the cord throughout its length. Microscopic examination of the cord at the eighth cervical and first thoracic segments showed necrosis of the cord and*

SUBACUTE MENINGOMYELITIS SIMULATING SPINAL CORD TUMOR

extensive round cell infiltration in the perivascular spaces and in the meninges. The lower thoracic and lumbar segments of the cord also showed a similar round cell infiltration, but no extensive necrosis. No organisms were found in the sections and special stains for tubercle bacilli revealed none. Gross and microscopic examination of the cord failed to disclose a tumor of either the extramedullary or intramedullary type. Examination of the thoracic and abdominal organs showed only congestion and edema of the lungs, congestion of the liver, spleen and kidneys, and fibroids of the uterus.

Final pathological diagnosis: Subacute meningomyelitis of unknown origin.

Greenfield and Turner¹, reporting three cases similar to the above case, have given an excellent description of their clinical and pathological features.

DISCUSSION

In reviewing the history of the patient's illness, one is impressed by the initial symptom of interscapular pain radiating around the chest. This suggests "root pain" which is often the first symptom of extramedullary tumor. The afebrile course of the disorder and the gradual development of numbness and weakness of the legs, numbness of the trunk and arms, and loss of sphincter control, together with the sensory level and pyramidal tract signs found on examination are entirely consistent with a diagnosis of spinal cord compression. Complete or partial spinal subarachnoid block and elevation in the total protein content of the cerebrospinal fluid obtained by lumbar puncture are present in approximately 90 per cent of cases of spinal cord tumor, so that similar findings in this case appeared to be additional evidence in favor of such a lesion.

In the face of what appeared to be overwhelming evidence in favor of the presence of a spinal cord tumor, the important diagnostic finding of 22 cells per cubic millimeter in the cerebrospinal fluid was disregarded. For practical purposes, normal cerebrospinal fluid may be considered to contain not more than 5 cells per cubic millimeter, according to Merritt and Fremont-Smith². The same authors³, reviewing the findings in 36 cases of tumor in the spinal canal, found that the cell count was normal in two-thirds of the fluids and was greater than 25 per cubic millimeter in only five. The highest cell counts in their series were 78 and 90 in patients with meningiomas. In a series of 36 spinal cord tumors at the Cleveland Clinic, analyzed five years ago, the cell count in the cerebrospinal fluid was below five in 89 per cent of the cases and never above 17. A cell count of 22 per cubic millimeter of cerebrospinal fluid is definitely abnormal, and in the case which has been presented, it was the only finding which seemed out of place in the convincing clinical picture of

A. T. BUNTS

spinal cord tumor. It now seems clear that an abnormally high cell count in the cerebrospinal fluid, even though of very moderate degree, should cause one to hesitate before making a diagnosis of spinal cord tumor and before advising operation. At least it might be justifiable to try the effect of some nonsurgical form of therapy before resorting to laminectomy. Roentgen therapy, which has proved beneficial in some cases of acute and subacute encephalitis, should be given a trial in selected cases of nontuberculous and nonsyphilitic inflammatory disease of the spinal cord, particularly in those cases which present a lymphocytic pleocytosis in the cerebrospinal fluid.

REFERENCES

1. Greenfield, J. C. and Aldren Turner, J. W.: Acute and subacute necrotic myelitis, *Brain*, 62:227-252, (September) 1939.
2. Merritt, H. H. and Fremont-Smith, F.: *The Cerebrospinal Fluid*, W. B. Saunders Co., Philadelphia (1937), p. 57.
3. *Ibid*, p. 171.