

# ANEURYSM OF THE INNOMINATE ARTERY

## *Report of a Case*

GEORGE CRILE, JR., M.D., AND H. F. ELIAS, M.D.

Aneurysm of the innominate artery is not common and comprises only about 3 per cent of all aneurysms. This type of aneurysm is of special interest to the surgeon as its diagnosis is not as hopeless as that of the aortic aneurysm for which it may be mistaken. The treatment is within the province of surgery as has been demonstrated by Rundle<sup>1</sup>, who collected seven cases successfully treated by excision of the innominate artery, and by Schwyzer<sup>2</sup>, whose case was living and well 22 years after operation. Early diagnosis and treatment are desirable as adherence to the sternum, vascular complications, (especially cerebral), and the accumulation of large amounts of clot in the aneurysmal sac are all said to decrease the likelihood of obtaining a good result from surgery.

The innominate artery is the first branch of the arch of the aorta, and is usually 4 to 5 cm. long. It most frequently arises at the level of the upper border of the second right costal cartilage, ascending obliquely upward, backward and to the right. At the level of the upper border of the right sternoclavicular articulation it divides, forming the right common carotid and right subclavian arteries. Excision or ligation of this artery can be successfully accomplished if adequate collateral circulation has been established.

The following is the report of a case of a large innominate aneurysm.

*A 52 year old colored coal miner entered the Clinic on July 24, 1939, complaining of a lump in his neck and right chest of 18 months' duration. The mass was first noted as a painless swelling, and was not related to any known trauma. There had been progressive increase in size of the mass with associated local pain and dull ache in the right arm present for the past 7 months. In the past 2 months, the patient had noted a change in his voice and a choking sensation when in the recumbent position. There had been no nocturnal or exertional dyspnea, but a non-productive cough had been present for some time.*

*Family history: Noncontributory.*

*Marital history: Married—wife living and well. Two children died in infancy and the last pregnancy was a miscarriage.*

*Past history: Past illnesses included mumps, tonsillitis and influenza in 1918. Patient denied venereal disease by name and symptoms.*

*Physical examination revealed a colored man, 65 inches tall, weighing 123 pounds, temperature 98.2°, pulse 96, blood pressure, right arm 134/104, left arm 122/100. The skin was dry and the mucous membranes were normal. The pupils were equal and reacted slowly to light. The teeth were carious and there was considerable pyorrhea alveolaris.*

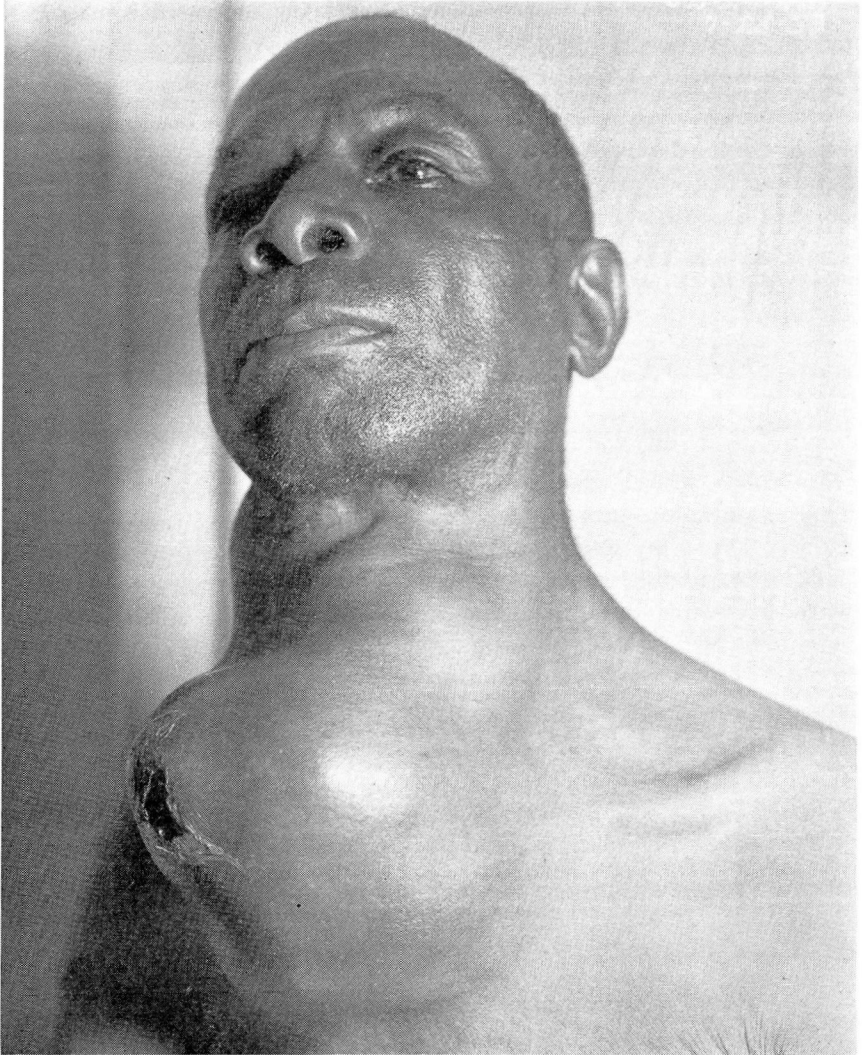


FIGURE 1: Photograph showing anterior view of innominate aneurysm.

*Both vocal cords were thickened but of normal color. The left cord did not approximate well in the midline but motion of both cords was demonstrated. Examination of the neck revealed a mass extending from the level of the hyoid bone down to the third intercostal space. The mass was 8 inches wide and protruded approximately 6 inches from the anterior chest wall (figs. 1 and 2).*

*The mass pulsated forcefully with the heart beat. On the right anterolateral surface of this mass, over an area 3 inches in diameter, the skin was crusted and was obviously breaking down. The superficial vessels*



## ANEURYSM OF THE INNOMINATE ARTERY

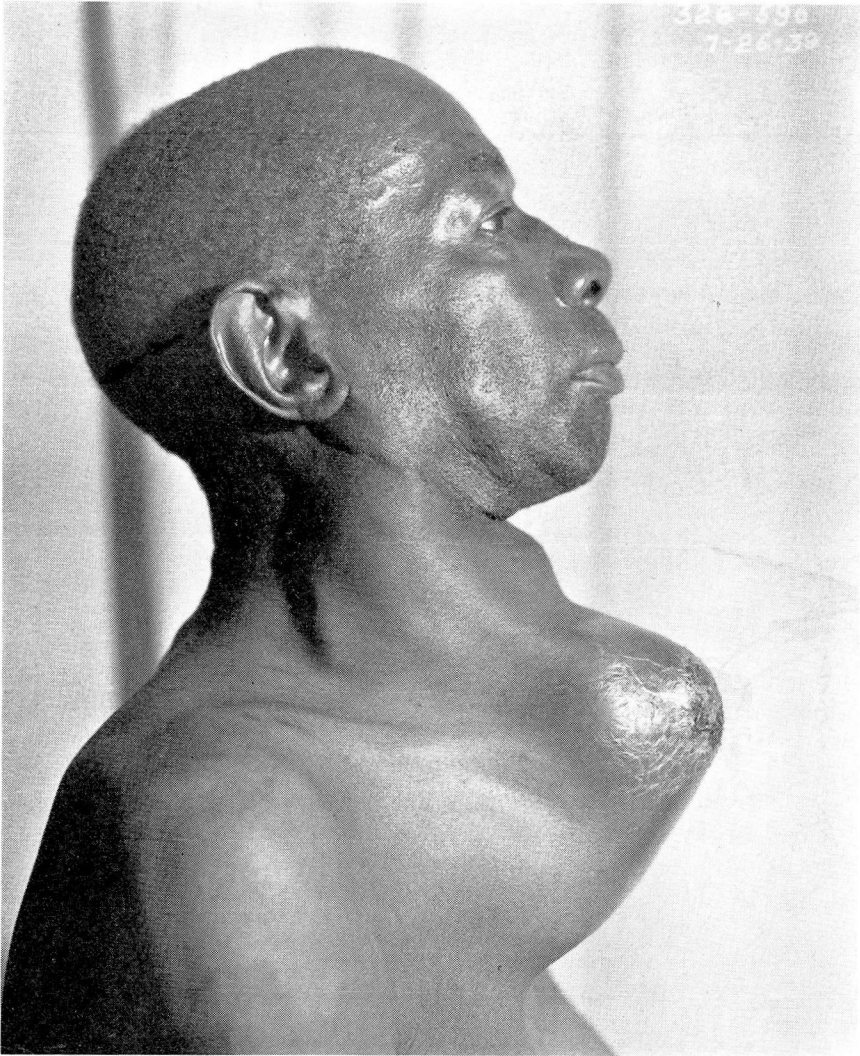


FIGURE 2: Photograph showing lateral view of aneurysm with crusted area.

*in the right cervical region were dilated. Both carotids could be palpated pulsating synchronously behind the main body of the tumor. All vessels were thickened and sclerotic.*

*The lungs were clear to percussion and auscultation. The cardiac borders were not enlarged, the heart sounds were rhythmic, of good quality and no murmurs could be heard. The radial pulses were equal and synchronous. The remainder of the examination, including neurological examination, showed no abnormalities. There were no penile scars.*

*Laboratory examination revealed the following data:*

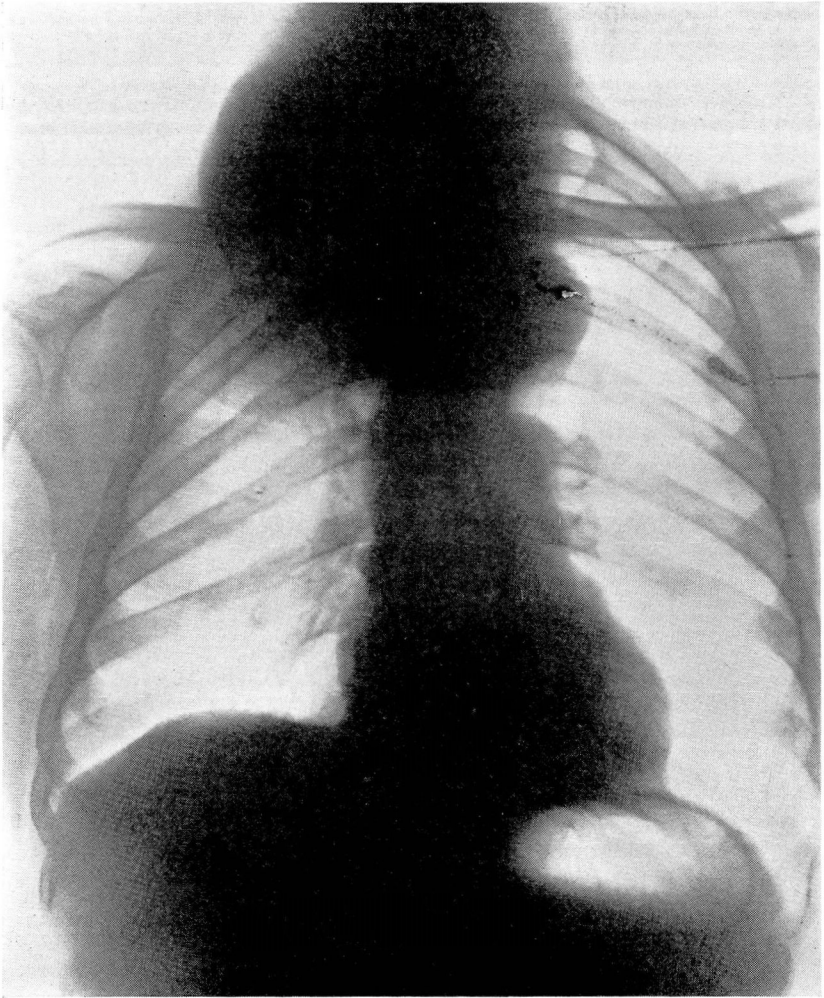


FIGURE 3: Roentgenogram showing mass pushing clavicles anteriorly and lateralward. The sternum is not eroded.

*Blood: Red blood cells 3,740,000, hemoglobin 50 per cent, white blood cells, 4,900; neutrophils 78; eosinophil, 1; lymphocytes, 21. Blood sugar fasting was 92 mgm. Wassermann and Kahn tests were negative. Recheck of Wassermann and Kahn tests again gave negative reactions.*

*Urinalysis was negative.*

*Roentgenograms of the chest showed the mass as seen in figure 3.*

*The shadow of the aorta was interpreted as showing no abnormalities.*

*An electrocardiogram showed no diagnostic changes.*

*The basal metabolic rate was +11 per cent.*

*To differentiate between a pulsating thyroid neoplasm and an*



## ANEURYSM OF THE INNOMINATE ARTERY

*aneurysm of the innominate artery, a 24 gauge needle was inserted at the periphery of the mass and bright red blood under high pressure was obtained.*

*Because of the enormous size of the aneurysm, it was questionable if any operative procedure could be undertaken, especially in view of the fact that rupture of the mass was thought to be near at hand, and would surely take place if any incision was made in the adjacent skin. We felt, however, that if exposure were possible, an endaneurysmorrhaphy with the vessel might be accomplished. The next day, when preparation was being made for operation, the aneurysm spontaneously ruptured during an attack of coughing. The rupture would admit a large amount of blood but fortunately was closed quickly by application of pressure. Bleeding was controlled temporarily by pressure and the patient was taken to the operating room.*

*A cannula was introduced into the femoral vein and was connected with a large container of normal saline. Pressure was removed from the aneurysm and the blood spurting from the aneurysm was collected in a container and citrated, three liters of blood being obtained. This was transferred to the vessel of normal saline connected to the femoral vein. The patient became unconscious as the third liter was obtained and the blood flow diminished. The aneurysm was immediately incised widely, the blood was collected, the clots were removed and the opening was found. The opening was only about 2 cm. in diameter and appeared to be located at the junction of the subclavian and innominate arteries, involving the anterior wall of the vessel. The opening was rapidly closed with three layers of continuous steel alloy sutures and the blood and saline were simultaneously injected in the femoral vein. Artificial respiration was started and adrenalin was injected into the femoral vein. The apex impulse was visible but no heart sounds could be heard. After a five minute interval, during which time artificial respiration was maintained and intracardiac adrenalin had been administered, a hockey stick incision was made over the sternum, the ribs of the precordium were reflected and the heart was massaged. No response was obtained. Exploration revealed a large post-mortem blood clot filling the aorta. The medial third of the right clavicle had been completely destroyed by the aneurysm.*

### COMMENT

This unusually large aneurysm of the subclavian artery was obviously not well suited to surgical treatment as the size greatly increased the technical difficulties and the thin wall of the sac made any manipulation about the area hazardous.

In view of the size of the aneurysm, the age of the patient and the degree of arteriosclerosis present, it was believed that ligation of the innominate artery could not be successfully accomplished. It was there-

fore decided to attempt to repair the aneurysm by endaneurysmorrhaphy. The size of the tumor and the thinness of its walls precluded the possibility of exposing the innominate artery and temporarily controlling its circulation while the aneurysm was being repaired.

Before the aneurysm ruptured and forced us to play our hand before we were prepared, we had planned the operation in the following steps:

1. Slow exsanguination of the patient, removing a pint of blood every six hours until the hemoglobin reached dangerously low levels.
2. Storing of all blood removed.
3. Procuring an additional 1000 cc. of blood from [REDACTED]
4. Insertion of large cannulas in both femoral veins and [REDACTED] veins and connecting these cannulas with reservoirs containing [REDACTED] and adrenalin.

5. Wide incision of the aneurysm with collection of the blood and transfer of blood to the previously prepared reservoirs.

6. After "death" by rapid exsanguination, rapid endaneurysmorrhaphy was to have been performed. (It was estimated that the first layer of sutures could be inserted in one or two minutes.)

7. Rapid autotransfusion of blood and adrenalin and an attempt to resuscitate the patient while repair of the aneurysm was being completed.

Unfortunately, when the aneurysm ruptured we had not as yet procured the necessary cannulas and furthermore the patient was already in mild shock from loss of blood. No blood was immediately available for transfusion. We had therefore to rely on glucose solution to replace the blood lost in hemorrhage.

Collection of the blood from the aneurysm was easily accomplished and the sac was found as we had expected, to have a small mouth and to be well adapted to repair. Only about one and one-half minutes elapsed between the collapse of the patient and the completion of the first row of sutures in the repair of the aneurysm.

However, the femoral cannulas were not large enough and the blood was not delivered with sufficient rapidity. Nearly seven minutes had elapsed between the patient's collapse and the transfusion of enough fluid to replace the amount lost. In spite of the fact that the heart beat faintly for a few moments after the administration of intracardiac adrenalin, it was apparently too late for resuscitation to be effective.

This case has proved to our satisfaction that such an attack is feasible from the technical standpoint provided that with adequate preparation, rapid delivery of the blood could have been effected. Post-mortem examination of the repaired aneurysm showed the defect in the vessel wall well closed and the lumen of the vessel patent.

#### REFERENCES

1. Rundle, Frank: Aneurysm of the innominate artery treated by surgery; report of 3 cases and records of 22 cases collected from the literature, *Brit. J. Surg.*, 25:172-190, (July) 1937.
2. Schwyzer, Arnold: Aneurism of the innominate artery, *Ann. Surg.*, 96:666-669, (October) 1932.