

ESOPHAGOSCOPY

Treatment of Lesions of the Esophagus

PAUL M. MOORE, JR., M.D.

Practically all lesions of the esophagus have one outstanding symptom in common,—dysphagia—and it is because of this that patients seek the advice of a physician. The name esophagus is derived from the Greek and means to carry food. This is its sole function. Any lesion which interferes with its normal function produces dysphagia. A puncturing injury or an ulcerating lesion may lead to mediastinitis, a tracheo-esophageal or broncho-esophageal fistula or to a fatal hemorrhage.

The only ways by which the esophagus may be visualized are by the use of the roentgen rays and barium meal and by the use of the esophagoscope. The first should always be used. In the majority of cases this should be supplemented by esophagoscopy. Esophagoscopy has a two-fold use. First, it is a diagnostic aid of proved value. By its use the entire length of the esophagus can be inspected, and lesions which may be too small to be visualized by roentgen examination can be seen. Biopsy specimens can be removed for pathologic examination and diagnosis. Secondly, it can be used for treatment. The most important use in this respect is the removal of foreign bodies. Local treatments can also be given when they are indicated.

The procedure is attended by little danger when it is done by a careful and experienced operator. Rough handling and the use of too much force may produce a rupture in the thin wall of the esophagus and lead to a fatal mediastinitis. The point where the greatest care must be observed is at the very beginning of the esophagus where it is kept closed by the contraction of the cricopharyngeus muscle. A spasm of this muscle must be overcome by gentle pressure but it cannot be forced. The presence of a sharp pointed or edged foreign body carries grave danger of perforation and mediastinitis, and its removal must be accomplished with the greatest care.

Contraindications for use of the esophagoscope are aneurysm, advanced organic disease, extensive esophageal varicosities, and acute esophagitis.

In performing esophagoscopy, the patient is given preoperatively a hypodermic of morphine and atropine. A local anesthesia of cocaine or pontocain is used. No pain is associated with the procedure but there is some discomfort. It is a great help if the patient is relaxed and not nervous and tense.

Among the *congenital abnormalities*, one in particular can be treated through the esophagoscope. This is the case with webs across the lumen of the esophagus. These webs can be cut or removed and thus result in an unobstructed passageway for food. If a stricture is present, it can be

ESOPHAGOSCOPY

treated by dilations. The whole subject of dilating the esophagus and the various methods used will be discussed later.

In the pulsion type of diverticulum, the esophagoscope can be a valuable aid to the surgeon who is to remove the sac. Preoperatively, it can be used to clean the sac and to clear up any infection which is present. It is often inserted into the sac at the time of operation to help the surgeon locate it and to determine its size and extent.

Foreign Bodies: There is usually a history that the patient has swallowed a foreign body and that this was followed by more or less dysphagia. In the case of an infant who has been playing among an assortment of toys and who is not under the watchful eye of an elder, this history may be missing. The only thing that is noticed is that the child has difficulty in swallowing or refuses food. There may be an associated cough. The infant becomes listless and if forced to take food, regurgitation may occur. Any infant showing such symptoms should be suspected of having a foreign body in the esophagus. It is well to remember that the roentgen examination may give negative findings if the foreign body is not radio-opaque. The barium meal and esophagoscopy should be used. One infant who was admitted to the University Hospital at Ann Arbor while I was an interne made a lasting impression on me. It had been months since the child had first shown signs of sickness. During this time, he had been observed and treated but a roentgen examination had not been made until just before he was sent in. The roentgenogram showed two safety pins in the upper end of the esophagus. When removal was attempted, these were found to be deeply imbedded in the wall of the esophagus. Removal was followed by mediastinitis and death.

Another example of the disastrous result of neglecting a foreign body is shown by the following case. A 14 year old girl swallowed a chicken bone which lodged in the esophagus. On the assumption that it might pass on, nothing was done. A few days later she had less difficulty in swallowing and seemed to be all right. No roentgenogram was taken. Several weeks passed. Then severe hemorrhages from the mouth began and she was rushed to the hospital. She arrived in severe shock from the loss of so much blood. She was in no condition for manipulation but transfusions were given immediately and she was treated for shock. She failed to rally and died. At necropsy, the esophagus was found to be filled with blood. The chicken bone had lodged crosswise but was so narrow that it did not cause complete obstruction. There was necrosis of the esophageal wall at either end of the bone. If esophagoscopy had been performed soon after the bone became lodged, an entirely different outcome could have been expected.

Chicken and fish bones are often too small to show in the roentgen films, although it is sometimes possible to find a filling defect by the use of barium. In any case, every patient with a positive history should be

examined with the esophagoscope unless it can be definitely proved that the foreign body has passed on into the stomach or has been regurgitated. In this way tragedies like the above two cases can be averted. It is true that in many cases the small bone scratches the mucosa but does not lodge. This leaves a sensation of pain on swallowing and the patient often feels as though the bone were still in the throat. On examination the mucosal injury is seen and the absence of the foreign body is demonstrated. This requires a very careful and thorough examination because the many folds in the upper end of the esophagus may conceal a small foreign body. There is danger of perforation and mediastinitis when sharp points or edges are present and removal should be accomplished with the least possible trauma.

Whenever possible, a duplicate of the foreign body should be procured. The family should be instructed to bring a duplicate if they possibly can. This enables the operator to make a better selection of forceps and to work out the mechanics of removal before starting the operation.

In the case of globus hystericus and Plummer-Vinson syndrome, the negative findings on esophagoscopy help establish the diagnosis. In carcinoma a biopsy can be taken. Varices can be seen and may be treated by puncture diathermy. Ulcerations can be treated locally in the same way that ulcerations in the mouth are treated.

All patients with cardiospasm (see fig. 1) and strictures (see fig. 2) should have the benefit of esophagoscopy. The diagnosis can be definitely established and the presence of a small inciting carcinoma or ulceration can be ruled out. In the former the findings are characteristic. The esophagus is more or less dilated all the way down to just above the stomach. In cases of long standing the dilation may be very great. At the location of the spasm, the esophagus is tightly drawn together. The Jackson esophageal dilators can be passed gently into the stomach. This dilation is continued until the largest size that can be used has been passed. As soon as the patient has recovered from the immediate effects of the manipulation, he notices a distinct improvement. Subsequent dilations can be carried on without the use of the esophagoscope.

In the case of cicatricial stricture the problem is much greater. These patients have usually swallowed lye or some other corrosive agent. After they have recovered from the burn itself they may be able to eat quite well and the contraction from scar tissue may not be manifested for a period of weeks after the original injury. If seen during this time the prognosis should be guarded because obstruction may develop later on.

Patients with congenital and cicatricial strictures, cardiospasm or carcinoma can all be treated by dilatation of the esophagus. In the case of carcinoma, treatment is merely palliative and is attended by the danger of rupturing through the wall of the esophagus. Dilations should

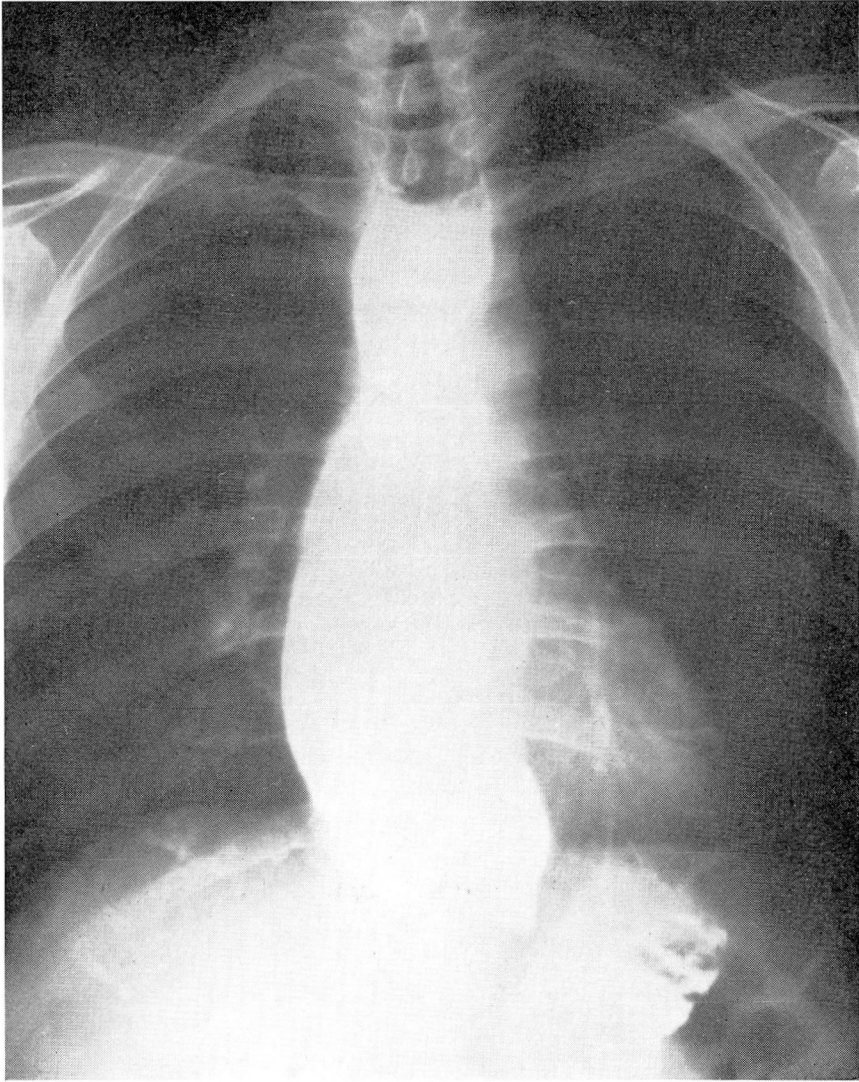


FIGURE 1. Cardiospasm.

be done very gently. The patient swallows a string and this is used to guide the olive-tip dilator. If a gastrostomy is performed so that the patient can be fed directly into the stomach, dilatations are not necessary.

Cardiospasm or preventiculospasm can be treated successfully, and excellent results can usually be expected. The Mosher bag has largely replaced the old Plummer hydrostatic bag. The former is expanded by air, is safer and is more convenient. It has metallic ribs so that the dilatations can be done under fluoroscopy if desired. Another very use-

ful dilator is the graduated flexible dilator filled with mercury. The dilatations should be done at intervals of 2 or 3 weeks, and the intervals should be lengthened as the patient improves. Atropine and a bland smooth diet should be given until the co-existing esophagitis is cured.

Patients with strictures, either congenital or traumatic, require a much longer and more tedious course of treatment. Formerly, dilations from above along guiding strings or under direct vision through the esophagoscope were used, but this method resulted in too many ruptures of the esophagus and complicating mediastinitis. Pockets or small

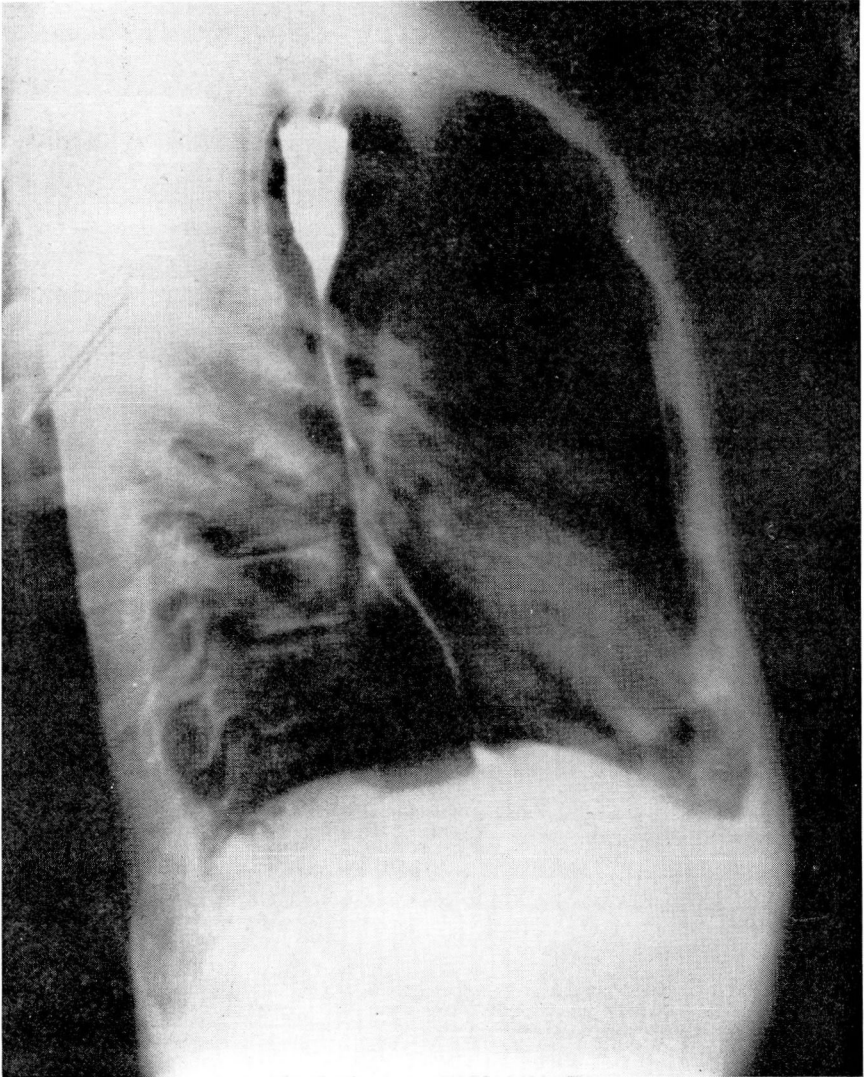


FIGURE 2. Stricture of the Esophagus.

ESOPHAGOSCOPY

diverticula are often present above the stricture. When dilations are attempted from above, the end of the dilator may pass into the pocket and be forced through the esophageal wall. The blind use of dilators or bougies to dislodge foreign bodies is also attended by the same danger of rupture of the esophagus. In this case the foreign body may deflect the end of the bougie and cause it to pass through the esophageal wall. If the foreign body has sharp edges or points it may lacerate the wall so that infection may pass through.

The best procedure with stricture cases is to perform a gastrostomy. After this is healed, the patient swallows a string to the end of which has been fastened a small lead shot. When the shot has reached the stomach as shown by the roentgenogram, the string is recovered through the gastrostomy wound. The esophagus is then dilated by the retrograde method. The dilator is fastened to the string and passed through the stomach and into the esophagus. It is allowed to remain in place a few minutes and is then drawn out by way of the gastrostomy wound and a larger dilator is passed. Between dilations nutrition is maintained by feedings through the gastrostomy tube. The string is left in place with the upper end through the nose. This is continued until a size 40 dilator can be passed through the esophagus and until at least a month has elapsed without any contraction of the stricture. Then only is the gastrostomy wound allowed to close. After the esophagus has become pretty well dilated, the patient is allowed to take food by mouth and the string may be removed between dilations, to be reswallowed at the time of the next dilation.

In closing, I should like to mention one more patient whom I saw some years ago. This patient had dysphagia due to an obstruction midway in the esophagus. The first esophagoscopy had been somewhat unsatisfactory but, because of the marked obstruction and loss of weight, a gastrostomy had been done so that he could be fed. A string with the lead shot on the end was then given to him to swallow. The string was to act as a guide for a second esophagoscopy and to be used for retrograde dilation later. Some hours after he had been given the string to swallow, he began to cough violently. When the coughing failed to subside it was thought that he might have aspirated the string instead of swallowing it. An attempt to pull the string out through the mouth showed it to be firmly held in place. Examination with the laryngoscope showed the string to be leading down into the esophagus. But it also showed a string leading into the larynx and trachea. He had a tracheo-esophageal fistula, had swallowed the string but it had passed through the fistula into the trachea. His coughing had blown the bead and string attached to it up through the larynx where it had become entangled with the other portion of the string and had tied itself in a knot. The string leading into the larynx had to be cut before it could be removed.