

VESICAL LITHIASIS CONCOMITANT WITH BENIGN ENLARGEMENT OF THE PROSTATE

F. C. SCHLUMBERGER, M.D.

It is a commonly accepted fact that urinary stasis is a requisite to the formation of bladder stones. Therefore, one would expect to find stones frequently associated with obstructive lesions at the bladder neck.

In a review of one hundred cases of vesical lithiasis seen at the Cleveland Clinic, 40 per cent were found to have been associated with benign enlargement of the prostate. This is one reason why vesical calculus occurs almost exclusively in men in this country. Only two cases of vesical calculus occurred in women in this group. Other common causes in men were primary urethral stricture, stricture of the bladder neck following prostatectomy, and diverticulum of the bladder.

Stasis of urine alone is not always enough to bring about the formation of calculi. Infection, changes in the level of the pH of the urine, and the presence of a nucleus markedly influence their formation. Infection greatly increases the rapidity of formation. Urine mixed with inflammatory exudates has, by no means, the same physical characteristics as normal urine. Clumps of bacteria, blood clots, and inflammatory exudates often form the nucleus of a stone. Sepsis produces a change in the surface tension of the urine, thus enhancing the tendency to form deposits.

Changes in the composition and pH of the urine have an important bearing on the type of calculus formed. An acid urine predisposes to the formation of calculi composed of urates and oxalates. However, a change in the bacterial flora of the urine may so alter its pH that precipitation of alkaline substances takes place. This explains the formation of laminated calculi. Blood and excessive amounts of mucus in the urine also influence the composition of the stone.

Where urinary stasis exists, only a nucleus is necessary to begin the formation of a calculus. The rapid precipitation of crystals may form a nucleus or a small stone may pass from the kidney into the bladder. When bladder calculi exist, one always should rule out their presence in the upper urinary tracts. On one occasion in our experience, the nucleus of a stone was a small piece of resected prostate gland. This, of course, emphasizes the importance of completely removing all the pieces following resection of the prostate, and maintaining the bladder free of blood clots following this procedure. This also applies to litholopaxy, because retained fragments of stone may form the nucleus of a recurrent stone.

It has also been our experience to see formation of calcarious deposits on a sloughing surface following incomplete resection of the prostate.

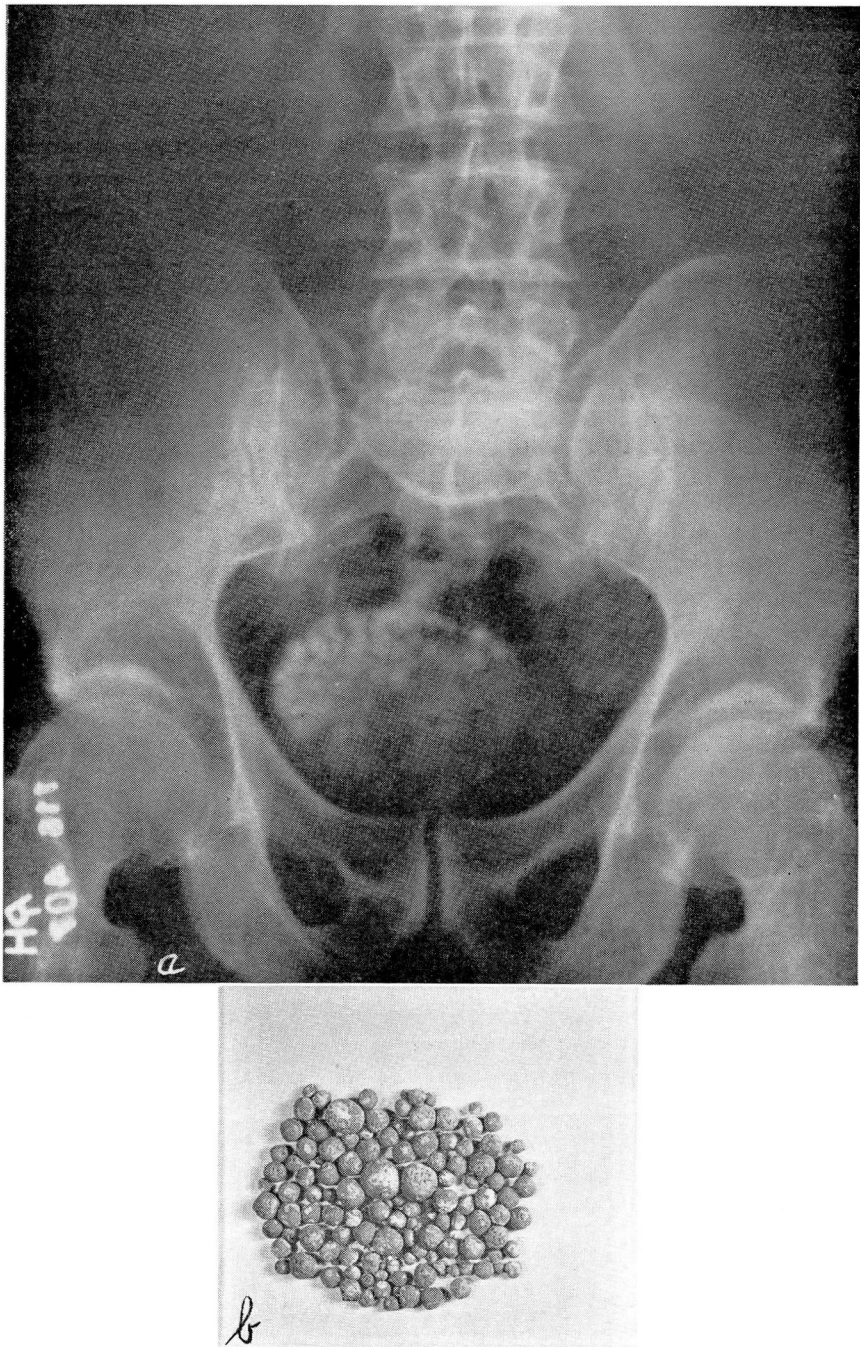


FIGURE 1: a. Roentgenogram showing multiple calculi associated with benign enlargement of the prostate.
b. Photograph of calculi removed transurethrally.

VESICAL LITHIASIS

In this case, healing of the resected prostatic bed takes place slowly and, in the presence of infection, the sloughing area becomes a ready nucleus for the deposition of crystals. Particles often break off and form free calculi in the bladder. This may be avoided by cleanly resecting the prostate, which allows healing to occur more smoothly and rapidly.

In this group of bladder stones associated with prostatic hypertrophy, multiple calculi were found in thirty-six cases and single calculi only in four cases. Multiple calculi were associated with large amounts of residual urine. Development of multiple stones in such instances is dependent upon the wide separation of minute nuclei by a large quantity of fluid which discourages the formation of a single calculus (Fig. 1). These small calculi usually are faceted or wedge-shaped and jackstones occur occasionally. The shape of the calculi is greatly influenced by the amount of tenesmus present and the compression in the bladder. Single calculi often become impacted in a deep bas fond or prostatic pouch and assume the shape of the pouch.

Considerable emphasis has been placed upon the chemical composition of calculi formed in the urinary tract. This factor has become of importance in the recurrent formation of stones and is responsible for recently advanced therapeutic measures. Chemical analysis was carried out in twenty-one of the forty cases in this group. In sixteen cases, the composition of the calculi consisted largely of calcium phosphate and calcium carbonate with traces of oxalate; in three cases the calculi were composed of urates and oxalates with traces of phosphates, and in one case the calculus consisted of oxalates alone. The precipitation of pure oxalate crystals often occurs in sterile urine. Alkaline substances are precipitated in the presence of urea splitting organisms such as the proteus bacillus, certain strains of the Staphylococcus, and colon bacillus. These organisms, because of their ability to split urea, maintain the urine alkaline in reaction and facilitate the precipitation of phosphates. Thus it becomes important to make a careful culture of the bladder urine and to determine whether the organism present has the power to split urea. Following removal of the stone, one may then institute the proper dietary and medical management to maintain the urine at the desired pH in an attempt to prevent the recurrent formation of calculi.

A few characteristic symptoms often lead to a diagnosis of a stone in the bladder. However, in elderly men with prostatic obstruction, this condition sometimes gives relatively few symptoms. Often the obstructive symptoms overshadow those produced by the calculi and they may be entirely overlooked.

Severe pain and terminal tenesmus many times is a major complaint. This discomfort is usually described as a knife-like pain at the bladder

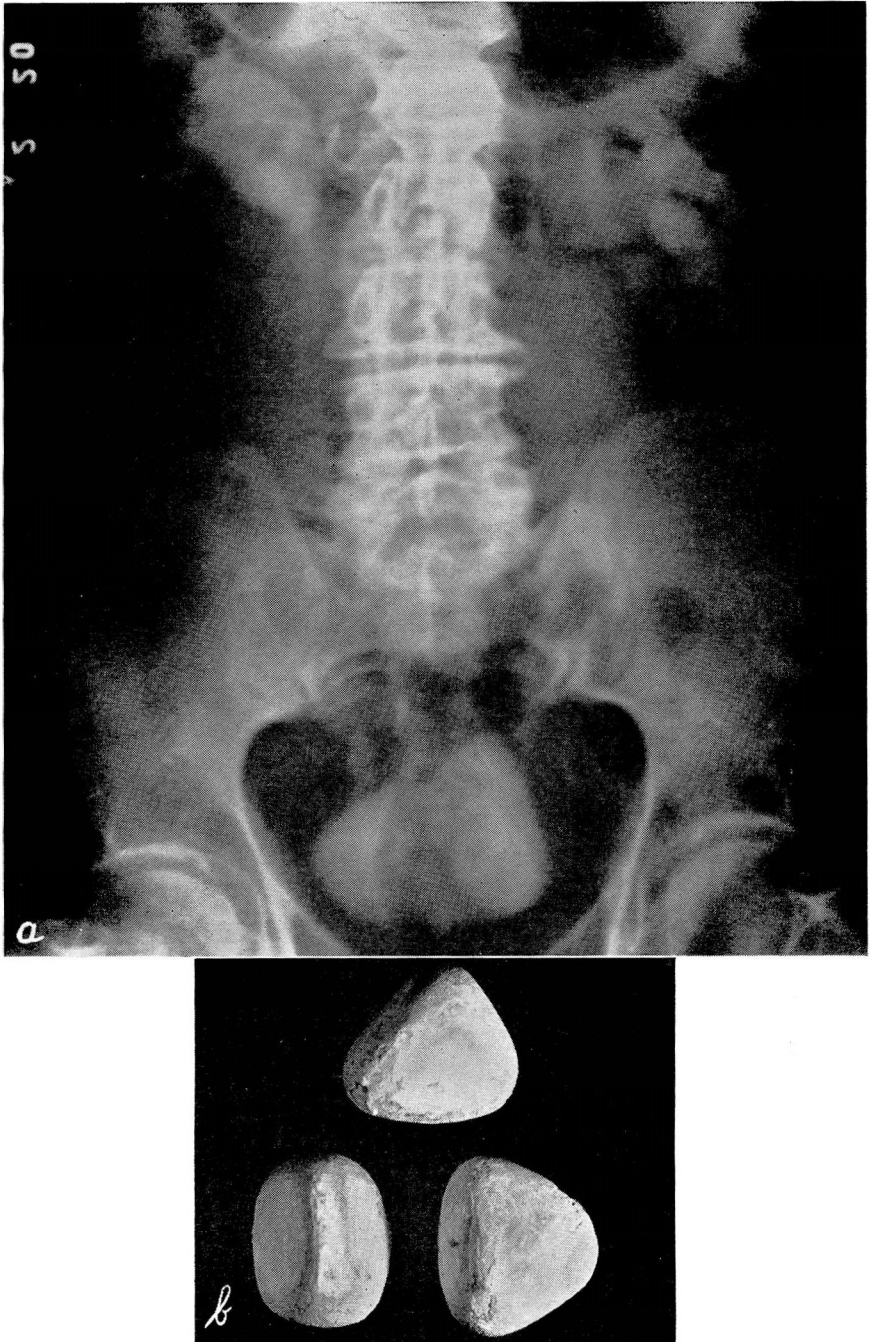


FIGURE 2: a. Roentgenogram showing three large calculi present in the bladder and the resultant ureteral and kidney disease.
b. Photograph of calculi removed by cystolithotomy.

neck and through the urethra, intensifying itself near the end of the penis. It is nearly always accompanied by terminal hematuria. Sudden cessation of the stream is a common complaint and occurs when the stone falls into the bladder outlet. The patient often states that he is more comfortable when lying down. This position, of course, allows the stone to fall back into the bladder, away from an already severely irritated bladder neck. The presence of calculi in the bladder may be definitely established by roentgenographic or cystoscopic examination. Nonopaque calculi are sometimes encountered in the bladder.

Distinct changes may occur in both the bladder and upper urinary tract due to longstanding bladder neck obstruction with calculi. The bladder wall becomes markedly thickened and heavily trabeculated. A perivesical cellulitis may develop. The ureters may become dilated and tortuous and the kidneys hydronephrotic. Ascending infection is almost inevitable and a diffuse pyelonephritis results (Fig. 2).

Two essential procedures are necessary in the treatment of this condition. First, the bladder neck obstruction must be adequately corrected and second, the stone should be completely removed. Inadequate resection of the prostate or incomplete removal of the stone predispose to recurrent formation of stones. The size of the prostatic enlargement or stone may determine the type of surgical procedure to be used. The general physical health of the patient is also of importance. Perhaps the age and general health do not warrant a time-consuming procedure such as litholopaxy might be if the stone is in the upper limits of size or of firm composition. Calculi often are removed much more rapidly by lithotomy with less harm to the patient than by difficult litholopaxy.

The condition of the bladder or upper urinary tract may demand adequate and longstanding bladder drainage which would warrant open operation and removal of the calculi. Following this, the obstructing portion of the prostate may be removed by resection transurethrally or by complete enucleation of the gland. If the obstructing prostate is of such size that relief of the obstruction can be obtained only by complete enucleation of the gland, removal of the calculi becomes very simple. Variations in the management must be applied according to the indications in the individual case.

These patients spontaneously fall into rather distinct groups according to the type of calculus present. First are those patients whose obstructive symptoms can be relieved by transurethral resection and the calculi are small enough to be removed through the sheath of the resectoscope. Nine patients of this group were cared for in this manner. Sometimes it may be necessary to employ the evacuating bulb or perhaps a grasping forceps. If the prostate is cleanly resected so that the beak of the instrument dips well down into the post-prostatic pouch which is present in so many of these cases, small calculi, as a rule, will pass spontaneously.

The second group consists of patients whose symptoms of obstruction can be adequately treated by transurethral resection, and the calculi are sufficiently large to necessitate the use of a small rongeur. These calculi are considered small but require crushing with a rongeur that can be introduced through the large resectoscope sheath. The remaining fragments may then be evacuated.

In the third group are those patients whose obstructive symptoms can be relieved by transurethral resection, the calculi being of sufficient size to require the use of a lithotrite. This procedure was carried out in twenty-four patients in this group. Two distinct procedures are necessary and may become time-consuming if both are attempted at one sitting. As in the two preceding groups, the obstructing portion of the prostate should be removed first. If time allows, litholopaxy may then follow this procedure or it may be carried out later at a second operation. Resection of the prostate is of great importance in this group and must be done first, as it facilitates the introduction and manipulation of the lithotrite. A number of instruments are available for this purpose. The visual type of lithotrite is perhaps the most applicable; however, the nonvisual Bigelow lithotrite still continues to be useful. Even though one may be skilled in the use of these instruments, this procedure may become quite involved and care must be taken not to injure the bladder wall.

The fourth group includes patients in whom the calculi are so large that litholopaxy becomes impossible, although the prostate is still amenable to resection. As a rule, complete enucleation of the gland is not warranted because of age or of general health. The calculi may be present in a diverticulum, making them inaccessible to the lithotrite. Where large calculi are present, marked infection often exists and perhaps considerable damage has been rendered the upper urinary tract. This may be alleviated by open operation and bladder drainage over a period of time. On several occasions in our series where the obstructing portion of the prostate was distinctly a middle lobe, removal of the calculi and the middle lobe of the prostate have been accomplished through a cystotomy. In such an instance, the obstructing portion of the gland is resected by means of a high frequency loop. Cystotomy and continuous drainage of the bladder simplifies transurethral resection of the prostate and often shortens considerably the convalescence of the patient.

The fifth group is comprised of those patients in whom both the calculi and the prostate are exceedingly large, or perhaps the prostate alone is very large, in which case the calculi become a secondary consideration. In this series of forty cases, prostatectomy was done in five cases. On four occasions, a one-stage suprapubic prostatectomy was performed and removal of the calculi was accomplished. In one case, a

VESICAL LITHIASIS

cystolithotomy was done and bladder drainage was established. This was followed later by a prostatectomy.

Certain contraindications to litholopaxy exist and should be observed. The presence of a diverticulum, marked trabeculation of the bladder, severe cystitis, and upper urinary tract infection are contraindications. The prostate or the stone itself may be too large. Urethral obstruction such as a stricture may prevent the use of any type of transurethral procedure. If no contraindications exist, however, litholopaxy is a very useful procedure and a boon to the patient suffering from coexisting vesical lithiasis and benign enlargement of the prostate.

SUMMARY

Urinary stasis is the most important predetermining factor in the formation of primary vesical calculi, as is evidenced by their frequent occurrence in association with prostatism. Of one hundred cases of vesical calculi, forty were found to be associated with benign enlargement of the prostate.

Variations in the findings render each case an individual problem. However, the majority of patients are amenable to transurethral resection of the prostate and litholopaxy.

Prevention of the recurrent formation of calculi is of prime importance. This may be accomplished by establishing a free flow of urine from the bladder and complete removal of the calculi. Accurate determination of the chemical constituents of the calculi should be made and adequate measures instituted to control the level of the pH of the urine.