

# IDIOPATHIC SPONTANEOUS PNEUMOTHORAX

H. SCOTT VAN ORDSTRAND, M.D.

In the minds of the medical profession, the diagnosis of pneumothorax too often infers the stigmata of tuberculosis in spite of increasing reports of numerous non-tuberculous cases, many without proved etiology. The association of tuberculosis with pneumothorax undoubtedly arises from its relative frequency in sanatoriums. Pneumothorax rarely occurs in the early stages of clinical tuberculosis, and if present, it is a late complication. In general medical practice, it is encountered in many non-tuberculous diseases as a complication of such entities as pure silicosis, asthma, pneumonia, lung abscess, lung tumor, etc. It has been reported following the administration of lipiodol, and one writer has emphasized its familial tendency in a few cases.

Although we have known for over fifty years that pneumothorax may occur in the apparently healthy, only in the past few years has much attention been paid to this fact. Hall,<sup>1</sup> in 1887, reported the first series of spontaneous pneumothorax in the healthy. Riesman and Fussel<sup>2</sup>, in 1902, and Emerson<sup>3</sup>, in 1903, were the first to report non-tuberculous pneumothorax in this country. Since these dates increasing numbers of cases in apparently normal people have been reported.

Many terms have been applied to this type of pneumothorax, including benign spontaneous pneumothorax, pneumothorax in the apparently healthy, and pneumothorax simplex. We prefer the term "idiopathic spontaneous pneumothorax," although it is not an entirely satisfactory designation.

The etiology of this form of pneumothorax is much debated. Kirshner<sup>4</sup> summarizes the most common theories as: (1) infectious, (2) congenital, and (3) emphysematous blebs on the surface of the pleura. He excludes the infectious theory because there is no pleural reaction (i.e. no subsequent effusion or empyema), and ordinarily no need for specific treatment (as in tension pneumothoraces complicating pulmonary infection). The relative frequency of the accident (spontaneous pneumothorax) as compared with the rarity of congenital defects argues against the second theory.

Rupture of subpleural blebs is the most practicable and widely accepted explanation of the etiology. Gordon<sup>5</sup> has described five cases in which he could delineate bullae on the roentgenogram after reexpansion had occurred. Kirshner<sup>4</sup> noted a ruptured pleural bleb at necropsy in one case of fatal termination and believed it to be an area of localized emphysema from collections of air under the pleura which can come only from the lungs. According to Kirshner, a rupture of an alveolus or a terminal bronchiole must occur, with the escape of air into the interstitial tissue and dissecting along the septum to cause a localized bleb on the

## IDIOPATHIC SPONTANEOUS PNEUMOTHORAX

pleura. The constant gliding of the parietal over the visceral pleura in this area gradually thins the pleura over the bleb which may rupture on cough or mild exertion.

Kjaergaard<sup>6</sup>, in 1932, reviewed the literature and found six cases in which the lesion had been "elucidated anatomically at autopsy." In these six cases, the pneumothorax was caused by rupture of the superficial air vesicles at the apices of otherwise healthy lungs. Three of these vesicles resulted from multiple congenital malformations of the lung, and in the other three, from solitary air vesicles on the bases of cicatricial changes.

The true incidence of idiopathic spontaneous pneumothorax is hard to determine because it may occur with little or no symptoms. Blackford<sup>7</sup> has found an approximate ratio of one case for every thousand students in session at the University of Virginia.

The symptoms, when present, are usually brought on by exertion. Coughing, sneezing, laughing, and straining at stool have been reported as precipitating factors. A third of Perry's<sup>8</sup> patients were seized with pain in the early morning. The symptoms vary ordinarily in direct proportion to the degree of collapse and the displacement of the trachea and mediastinal structures. The onset of pain may or may not be associated with dyspnea. In its location, the pain may simulate angina or coronary occlusion, with characteristic radiation to the neck and down an arm.

The diagnosis of pneumothorax may be suspected from the history and confirmed by physical findings and subsequent roentgen examinations. The radiographic exclusion of any parenchymal pathology as well as negative sputum examinations (if any is obtainable) are of primary importance in classifying the case as idiopathic. Our experience is in agreement with Friesdorf<sup>9</sup> and Olbrechts<sup>10</sup> in finding the average frequency of negative tuberculin tests as noted in other apparently healthy individuals. Likewise, the sedimentation rate of the erythrocytes usually is normal. The electrocardiogram may show an axis shift indicative of mediastinal cardiac rotation.

In simple idiopathic spontaneous pneumothorax, the prognosis is excellent. The condition may recur once or several times, but the patients survive with but few exceptions. Other than a week's rest in bed, no treatment is indicated with the rare exception of a tension pneumothorax which necessitates withdrawal of air. No after care is necessary because recurrences cannot be prevented by any known treatment.

### ANALYSIS OF CASES

Over the past four year period, forty-nine cases of pneumothorax have been observed at the Cleveland Clinic. In ten of these patients a final diagnosis of idiopathic spontaneous pneumothorax was made. In the remaining thirty-nine cases, the pneumothorax was found to be a compli-

## H. SCOTT VAN ORDSTRAND

cation of the following diseases: silicosis, chronic pulmonary fibrosis with emphysema, asthma, lung abscess, pneumonia, atelectasia, tumors (both primary and metastatic), osteomyelitis of a rib, and tuberculosis. Tuberculosis was present in only ten cases.

Of the ten cases of idiopathic spontaneous pneumothorax, there were eight men and two women. The average age was twenty-eight years, the youngest patient being sixteen and the oldest, forty-three years of age.

Seven of the patients had experienced single attacks only. Of the other three, one had had two attacks, one, four, and the other, eight. The cases were evenly divided as to the side of predilection; four cases experienced right sided pneumothoraces, four, left sided, and one, bilateral.

The presenting symptoms in five cases so accurately simulated a coronary accident that a tentative diagnosis of this entity was made by the initial physician attending the case. In two cases the electrocardiogram revealed an axis shift compatible with mediastinal rotation with lung collapse (these two cases experienced extensive degrees of collapse). The tracings were entirely negative otherwise. The symptoms occurred during exertion in six of the ten cases: (1) A sixteen year old boy noted the onset of left chest pain with dyspnea while sprinting a 100-yard dash. (2) A twenty-six year old mechanic noted right sided symptoms while turning a wrench at work. (3) A forty-three year old mortician experienced right sided chest symptoms while carrying a casket. (4) A thirty year old salesman noted the onset of left chest pain while coughing. (5) A thirty-two year old man noted onset of right chest symptoms while running up stairs. (6) A thirty-six year old man, a window trimmer by occupation, noted the onset of his left chest symptoms immediately following a short fall from a ledge. He did not strike his chest and experienced no kind of fracture.

### CASE REPORTS

The following two cases illustrate (1) a typical single idiopathic spontaneous pneumothorax, and (2) a patient experiencing multiple bilateral attacks.

*Case 1:* A twenty year old college student experienced sudden pain in the right anterior chest while eating breakfast on July 28, 1939. He had been feeling perfectly well, had been symptom-free prior to the onset of the pain, and had had no kind of injury. The pain became progressively worse and was associated with dyspnea and some nausea. He was confined to bed for three or four days with a constant "pleurisy pain." Following that date, he felt quite well except for a recurrence of the original symptoms for a lesser duration while playing tennis, ten days prior to being seen at the Clinic on August 22, 1939. He had experienced no cough at any time, and his past and family history were non-contributory. There was no family or contact history of tuberculosis.

Examination of the chest revealed a decreased expansion of the right lung with a hypersonorous percussion note over the upper and outer right chest, and decreased breath sounds in the same area. No rales were heard. The tempera-

## IDIOPATHIC SPONTANEOUS PNEUMOTHORAX

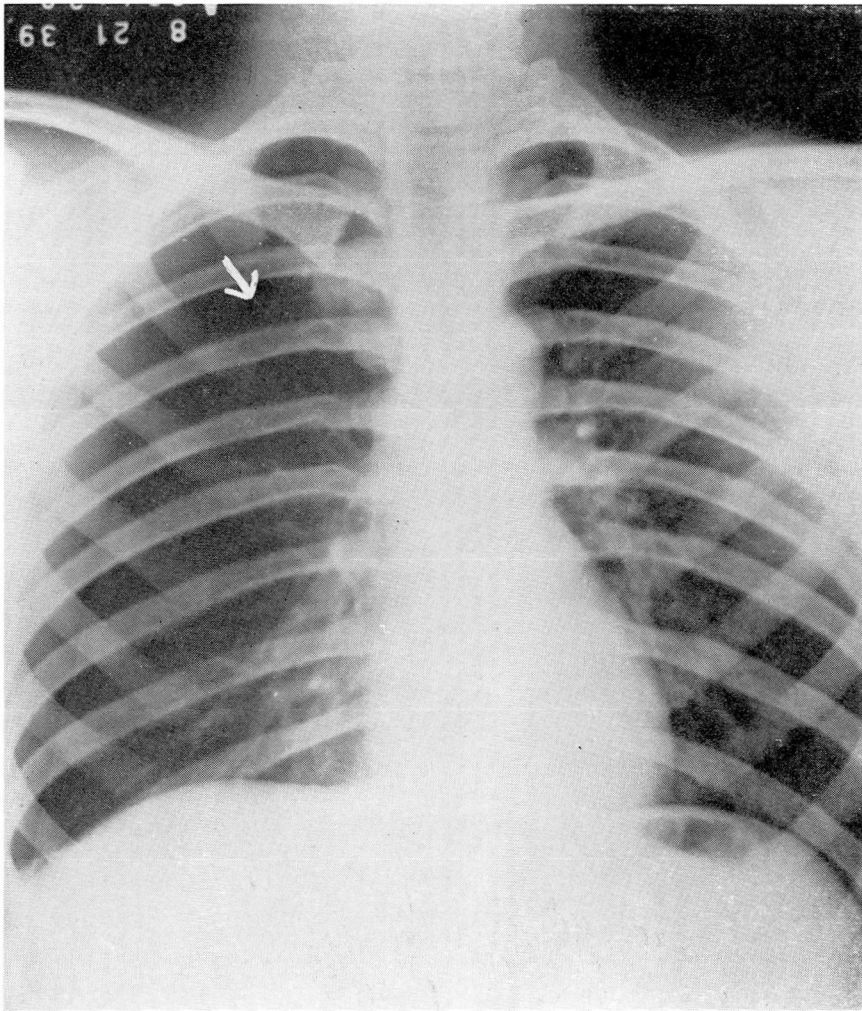


FIGURE 1: Roentgenogram showing 40 per cent collapse of the right lung. Arrow points to irregularity which might be interpreted as a ruptured pleural bleb.

ture and pulse rate were normal. The remainder of the examination was entirely negative. Tuberculin tests were negative in all strengths.

The roentgen examination (Fig. 1) revealed a 40 per cent collapse of the right lung. At one point on the apical lateral aspect of the visceral pleura of the collapsed lung was observed a small irregularity, which might be interpreted as a ruptured pleural bleb (note arrow). The lung parenchyma was entirely clear bilaterally.

A roentgenogram taken fifteen days later (Fig. 2) revealed complete reexpansion of the affected lung with no sign of any parenchymal infiltration. He has remained perfectly well to the present time.

*Case 2:* A forty-three year old mortician was first seen at the Clinic in

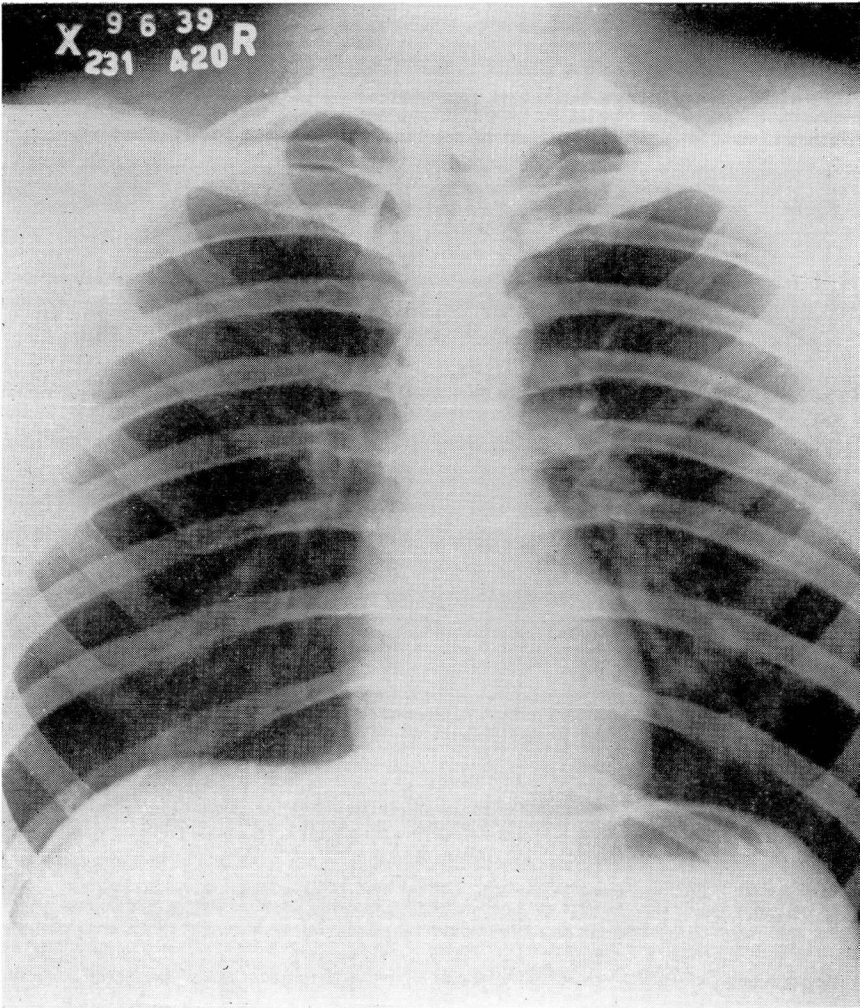


FIGURE 2: Roentgenogram taken fifteen days later showing complete reexpansion of the right lung and no parenchymal infiltration.

October, 1936. He dated the onset of dull mid-anterior chest pain with marked dyspnea to lifting a casket one week previously.

He had had a right chest pain with dyspnea while playing golf in 1923. At that time, a spontaneous pneumothorax was confirmed by roentgen examination, and he was confined to bed for six weeks. In 1928, during a short illness which was diagnosed as influenza, he again experienced a right spontaneous pneumothorax, and was confined to bed for six weeks.

In the intervals between the above attacks and prior to the attack which brought the patient to the Clinic, he apparently had enjoyed the best of health. He never had had a chronic cough or hemoptysis. He stated that three sputum specimens (examined at the time of colds and the influenza) had been negative. The family history was negative.

## IDIOPATHIC SPONTANEOUS PNEUMOTHORAX

The physical examination, substantiated by roentgen studies, revealed evidence of bilateral pneumothorax. There was a complete collapse of the right lung, and a 30 per cent collapse of the left lung. No demonstrable parenchymal infiltration was present. The remainder of the examination and various other diagnostic and laboratory studies were negative. A sputum specimen was negative, and the sedimentation rate was normal.

The patient recovered satisfactorily from this attack and remained symptom-free until he experienced a recurrence on the right side in May, 1937, while walking up a hill. He recovered from this attack and apparently has remained free from attacks on restricted activities to the present. Since his initial visit, he has been seen at frequent intervals, and all examinations have failed to reveal any evidence of tuberculosis or other explanation for the repeated spontaneous pneumothoraces.

### SUMMARY

Idiopathic spontaneous pneumothorax apparently is unrelated to tuberculosis, and occurs in healthy individuals in whom there is no demonstrable evidence of tuberculosis. Series of cases reported in the literature would indicate that: (1) The incidence of negative tuberculin tests is proportionate to apparently healthy individuals not experiencing this pleural accident and (2) there is no higher incidence of subsequent development of tuberculosis than in the average non-tuberculous population.

At present there are three theories to explain the etiology of the condition: (1) Infectious (non-tuberculous), (2) congenital, and (3) rupture of emphysematous (subpleural) blebs. The latter is the most practicable and the most widely accepted theory and is discussed in detail.

The prognosis is excellent in simple idiopathic pneumothorax, with few exceptions. There is no indicated treatment other than a week's rest in bed with the rare exception of a case with tension pneumothorax which necessitates withdrawal of air. No after care is necessary because recurrences cannot be prevented by any known treatment.

A series of cases is reviewed, and two cases are reported in detail.

### REFERENCES

1. Hall, F. de H.: On cases of pneumothorax in persons apparently healthy, *Tr. Clin. Soc. Lond.*, 20:153-161, 1886-7.
2. Fussel, M. H. and Riesman, D.: Spontaneous non-tuberculous pneumothorax, *Am. J. M. Sc.*, 124:218-235, (August) 1902.
3. Emerson, C. P.: Pneumothorax; a histological, clinical, and experimental study, *Johns Hopkins Hosp. Rep., Balt.*, 11:1-450, 1903.
4. Kirshner, J. J.: Spontaneous pneumothorax; aetiological considerations, *Am. Rev. Tuberc.*, 40:477-481, (October) 1939.
5. Gordon, I.: Benign spontaneous pneumothorax, *Lancet*, 2:178-181, (July) 1936.
6. Kjaergaard, H.: Spontaneous pneumothorax in apparently healthy, *Acta Med. Scandinav.*, supp. 43:1-159, 1-93, 1932.
7. Blackford, S. D.: Spontaneous pneumothorax in college students, *J.A.M.A.*, 113:737-739, (August 26) 1939.
8. Perry, K. M. A.: Spontaneous pneumothorax, *Quart. J. Med.*, 8:1-21, (January) 1939.
9. Friesdorf, C.: Ein Beitrag zur Aetiologie und Pathogenese des nichttuberkulösen Spontanpneumothorax, *München med. Wshnschr.*, 74:1672-1674, (September) 1927.
10. Olbrechts, E.: Le pneumothorax spontane "idiopathique," Benin, *Ann. de med.*, 27:429-483, (May) 1930.