

ESOPHAGEAL HIATUS HERNIA ASSOCIATED WITH HYPOCHROMIC ANEMIA AND ANGINA PECTORIS

Report of a Case

A. CARLTON ERNSTENE, M.D. and FRANK J. MCGURL, M.D.

The association of esophageal hiatus hernia with severe hypochromic anemia has been reported by a number of observers^{1, 2, 3, 4, 5, 6}. The anemia is due to loss of blood from the gastro-intestinal tract, probably the result of congestion or erosion of the gastric mucosa proximal to the constricting ring of the hernia. In the case reported by Schiro and Benjamin⁶, however, gastroscopic examination revealed no erosions and no differences in the mucosa above and below the diaphragm, although some of the gastric rugae were abnormally red. A review of fifty-nine cases of esophageal hiatus hernia at the Cleveland Clinic revealed two with hypochromic anemia. Since no examinations of the stool were made in one case, one cannot be certain that the anemia in this case was secondary to bleeding from the gastro-intestinal tract. The other case is the subject of this report.

REPORT OF CASE

A white married woman, sixty years of age, was admitted to the hospital on April 30, 1939, because of dyspnea on the least activity, palpitation, weakness and fatigability, and attacks of pain in the chest. Twelve years earlier, she had fallen down a basement stairway and had been unconscious for a period somewhat less than an hour. There had been no fracture. Dyspnea on exertion had been noticed for the first time after this accident and had become gradually but progressively worse. At the time of admission to the hospital, even the act of getting into or out of bed caused severe shortness of breath and palpitation. During the four months prior to admission, the patient had experienced attacks of pressure-like pain in the mid-substernal region with radiation to the right and left anterior chest and upward into the neck. These attacks were brought on only by exertion and were relieved within a few minutes by rest. Weakness and fatigability had been complained of for several years and had increased in severity for six weeks. A slight, unproductive cough had been present for six weeks, and for one week there had been some edema of the feet and ankles.

Physical examination revealed a moderately overweight individual with marked pallor of the skin and mucous membranes. The tongue was normal. "Spoon nails" were present. The lungs were clear on percussion and auscultation. The area of relative cardiac dullness extended 13 cm. from the midsternal line in the fifth intercostal space. The heart rhythm was regular, and the rate, 80 beats per minute. A moderate systolic murmur was heard in the third left intercostal space. The arterial blood pressure was 148 mm. systolic and 90 mm. diastolic. The liver edge could be felt just below the costal margin and was somewhat tender. There was slight pitting edema of the ankles.

The red blood cell count was 2,840,000 per cu. mm. and the hemoglobin content 28 per cent (4.4 gm. per 100 cc.). The color index of the erythrocytes was 0.49, the volume index 0.70, and the saturation index 0.70. The white blood cell count 4,400 per cu. mm. Examination of stained blood films showed severe pallor of the erythrocytes and marked anisocytosis and poikilocytosis. There were 2.5

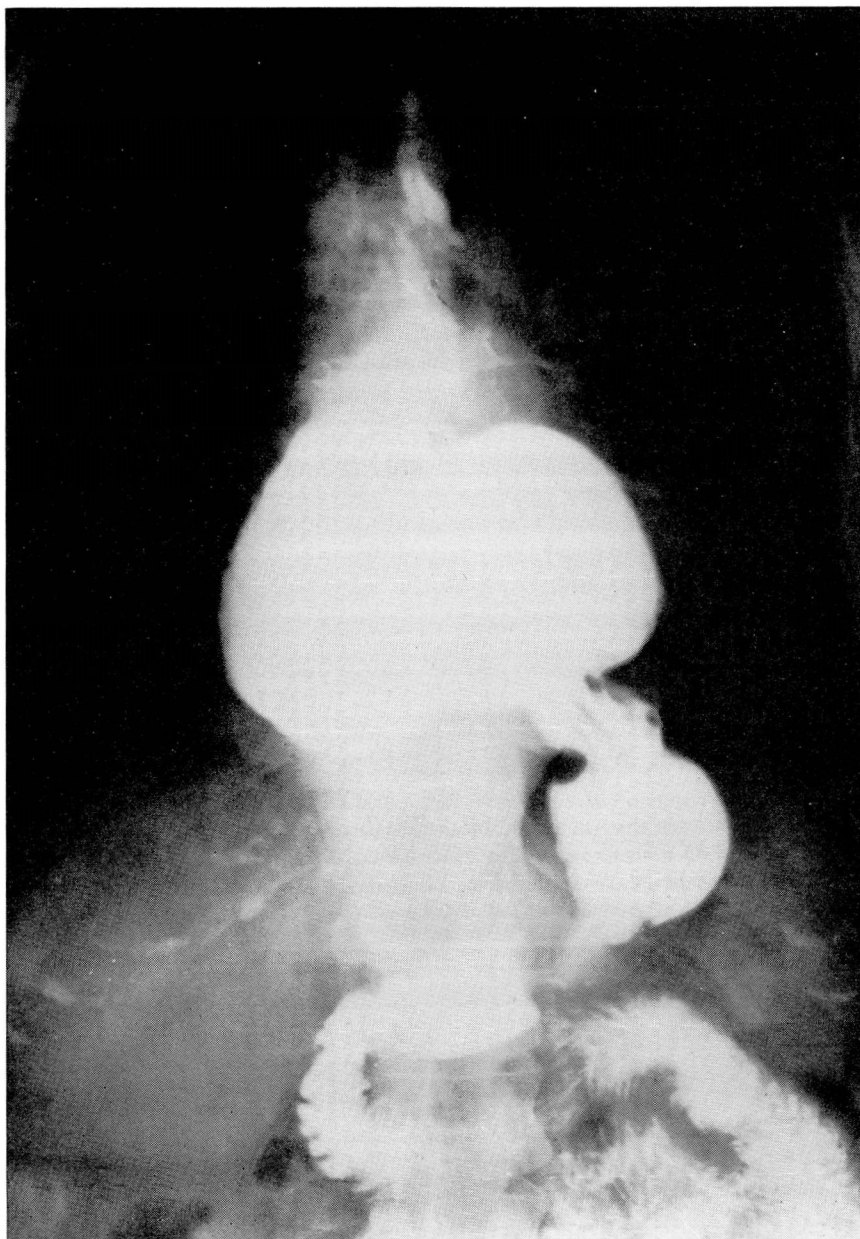


FIGURE 1: Roentgenogram showing a large esophageal hiatus hernia.

per cent reticulocytes. The icterus index was 3. The Wassermann and Kahn tests of the blood gave negative reactions. Urinalysis gave normal findings. Examinations of the stools showed from one plus to four plus occult blood.

Roentgenograms of the chest revealed that approximately four-fifths of the

ESOPHAGEAL HIATUS HERNIA

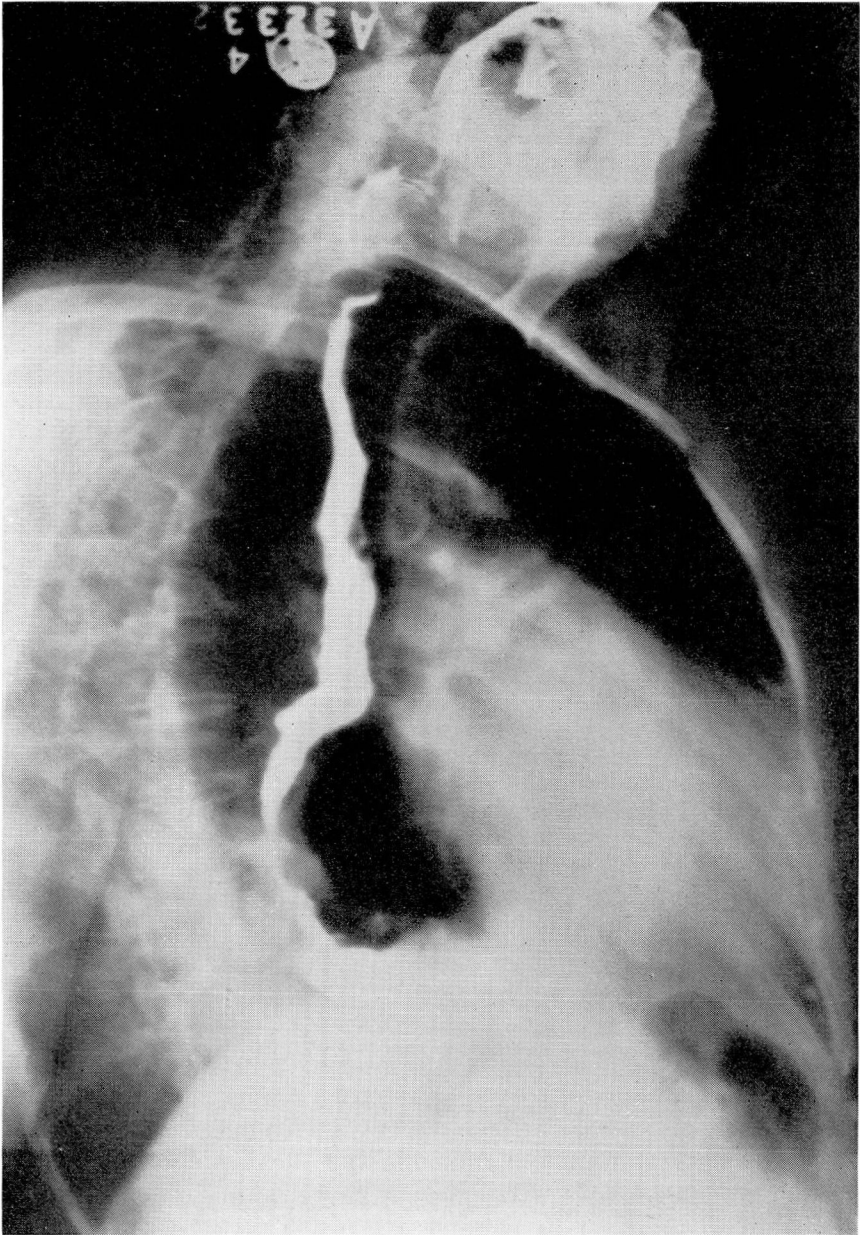


FIGURE 2: Roentgenogram showing esophagus of normal length.

stomach was in the thorax. The heart was enlarged. Further roentgenographic studies, after the administration of barium mixture, confirmed the presence of a large esophageal hiatus hernia (Fig. 1). The stomach was normal otherwise. The esophagus was of normal length (Fig. 2). The duodenum and the colon were normal except for a few small diverticula in the sigmoid region. The gall

A. CARLTON ERNSTENE AND FRANK J. MCGURL

bladder was visualized after the administration of cholecystographic dye and contained no stones. An examination of the gastric contents one hour after the administration of an Ewald meal showed a free acid content of 20 and a total acidity of 30.

An electrocardiogram revealed sinus rhythm with a rate of 84 per minute. Except for left axis deviation and slight depression of the S-T intervals in Lead I, the tracing was within normal limits in all respects. A precordial tracing (Lead IV F) was normal.

The following diagnosis was made: (1) Esophageal hiatus hernia, (2) arteriosclerotic heart disease with enlargement of the heart and angina pectoris, and (3) hypochromic microcytic anemia.

The patient remained in the hospital for nineteen days. Four transfusions of 500 cc. of whole blood were given, and Blaud pills were administered by mouth in doses of 30 grains (2 gm.) three times a day. In addition, thiamin chloride, 10 mgm., and liver extract, at first 3 cc. and later 1 cc., were administered daily by intramuscular injection. Seventeen days after admission to the hospital, the red blood cell count was 5,080,000 per cu. mm. and the hemoglobin content 78 per cent (12 gm. per 100 cc.). The color index of the erythrocytes was 0.76, the volume index 0.89, and the saturation index 0.86. With the correction of the anemia, there was striking symptomatic improvement. Weakness and fatigability diminished rapidly and a general sense of well-being replaced the earlier malaise. Dyspnea no longer occurred when the patient walked at an ordinary gait, and there were no further attacks of substernal pain. At the time of discharge from the hospital, the patient was advised to follow a high vitamin, low carbohydrate diet with extra vitamins. Blaud pills were continued for ten weeks in doses of twenty grains (1.3 gm.) three times a day. The clinical course has been entirely uneventful and the patient has been able to carry out all ordinary activities without dyspnea or anginal pain. On a few occasions, however, excessive exertion has caused mild dyspnea which has been relieved promptly by rest. The roentgenographic studies of the stomach were repeated on May 27, 1940, and the size of the hernia was found to be unchanged. An electrocardiogram taken on the same day also was unchanged, and the stools contained no occult blood.

The course of the erythrocyte count and hemoglobin content of the blood are shown in Table 1. Because of the slightly reduced values recorded in May, 1940, the administration of Blaud pills was resumed and will be continued periodically from now on.

DISCUSSION

The presence of occult blood in the stool indicates that the severe anemia in this case must have resulted from the loss of small amounts of blood from the gastro-intestinal tract over a long period of time. The exact site of the bleeding is unknown but the fact that anemia is a recognized complication of esophageal hiatus hernia makes its gastric origin almost certain. Congestion or erosion of the gastric mucosa, therefore, would seem to be the most probable cause of the hemorrhage. The incidental presence of diverticula in the sigmoid introduces some uncertainty, but diverticula seldom are responsible for blood loss sufficient to cause severe anemia.

The relief of the patient's symptoms with the correction of the anemia makes it evident that neither the dyspnea nor the attacks of substernal

ESOPHAGEAL HIATUS HERNIA

pain were due directly to the presence of a large part of the stomach in the thorax. Esophageal hiatus hernia occasionally gives rise in a purely mechanical way to symptoms which are highly suggestive of angina pectoris^{7,8}, but in such cases a careful analysis of the symptoms usually enables one to differentiate the pain from that of angina pectoris. In the present case, the pain met all of the requirements for a diagnosis of angina pectoris, and the clinical course indicated that the attacks were

TABLE I
EFFECT OF TREATMENT ON THE ERYTHROCYTE COUNT
AND HEMOGLOBIN CONTENT OF THE BLOOD

<i>Date</i>	<i>Red Blood Cells</i>	<i>Hemoglobin</i>
	<i>millions</i>	<i>per cent</i>
5/1/39	2.84	28
5/9/39	4.00	41
5/12/39	4.46	65
5/18/39	5.08	78
6/20/39	5.19	81
8/22/39	4.83	81
11/20/39	4.73	84
5/27/40	4.36	78

due primarily to the presence of severe anemia in an individual who probably has only slight coronary artery disease. The role of anemia in producing angina pectoris in patients who have but little coronary artery disease is well known.

SUMMARY

A case in which a patient with a large esophageal hiatus hernia experienced attacks of angina pectoris and dyspnea on slight activity has been reported. Severe hypochromic anemia due to loss of blood from the gastro-intestinal tract also was present, and correction of the anemia resulted in relief of the patient's symptoms.

REFERENCES

1. Segal, H. L.: Secondary anemia associated with diaphragmatic hernia, *New York State J. Med.*, 31:692-695, (June) 1931.
2. Weitzen, M.: Diaphragmatic hernia with severe anemia, *Am. J. Roentgenol.*, 28:808-812, (December) 1932.
3. Bock, A. V., Dulin, J. W. and Brooke, P. A.: Diaphragmatic hernia and secondary anemia; 10 cases, *New England J. Med.*, 209:615-625, (September) 1933.
4. Eisen, D.: Oesophageal hiatus hernia (with special reference to its x-ray diagnosis), *Canad. M. A. J.*, 39:207-213, (September) 1938.
5. Corn, A., Calton, R. and Claisse, R.: Grave anemia with hernia of stomach in adult case, *Bull. et Mem. Soc. Med. d hop. de Paris*, 55:1130-1135, (July) 1939.
6. Schiro, H. S. and Benjamin, J. E.: Severe anemia associated with diaphragmatic hernia, *Ohio State M. J.*, 36:164-166, (February) 1940.
7. Ernstene, A. C.: Differential diagnosis of coronary artery disease, *J. Kansas M. Soc.*, 36:441-446, (November) 1935.
8. Jones, C. M.: *Tr. Am. Clin. and Clim. Assoc.*, 55:1939 (In Press).