

# THROMBOSIS OF THE PULMONARY ARTERIES

## *Report of a Case*

H. O. SCHNEIDER, M.D. and H. SCOTT VAN ORDSTRAND, M.D.

Circulatory failure of an extracardiac nature caused by pulmonary emphysema, kyphoscoliosis, sclerosis of the pulmonary arterioles, and Ayerza's disease is not too uncommon to warrant intensive clinical investigation. The classical syndrome of dyspnea, cyanosis, pain in the chest with or without cardiac signs, and a normal blood count may tax the acumen of the clinician to differentiate between pulmonary or heart disease. A patient who recently entered the Cleveland Clinic presented this syndrome.

### CASE REPORT

A forty-seven year old white woman entered the Clinic on April 29, 1940, with the complaint of cough, pain in the chest, loss of weight, nervousness, fever, and shortness of breath. The patient dated the onset of her illness to a difficult labor four years previously. Her only symptom was dyspnea on moderate exertion until September, 1939, when she began to have nervousness, palpitation, and increasing dyspnea on lessened exertion. Two months later, the patient noticed "knots" on the abdomen which were not sensitive to touch, and swelling of the veins on the posterior aspect of the thighs and over each buttock. Associated symptoms were loss of weight and swelling of the ankles. The basal metabolic rate taken at that time was plus 40 per cent. Roentgen examination of the chest was normal. Her symptoms were not alleviated by the use of digitalis, Lugol's solution, and bed rest, but they improved spontaneously, and she was quite active for four months.

Four weeks before examination at the Clinic, the patient began to cough, producing about one cup of sputum daily which recently became pink-stained and foamy, but did not contain gross blood. Two weeks later, fever developed, and she complained of a dull pain over the right side of the chest anteriorly and posteriorly, which was not related to respiration. The patient had noticed increased perspiration and had been told that she had a heart murmur and a fast pulse. The menses had been scanty during the previous six months.

*Physical examination* revealed a well-developed woman who weighed 120 pounds, representing a loss of sixty pounds during the previous eight months. She was acutely ill and apprehensive. The eyes had a glassy appearance. Cyanosis of the lips and nail beds, and ptosis of the eyelids were present. The skin was soft, velvety, and moist. The thyroid was palpable. The lungs were normal throughout, except for bronchophony and whispering pectoriloquy with numerous moist râles in a small area in the right infraclavicular space. Examination of the heart revealed a rate of 120 beats per minute and gallop rhythm. The area of cardiac dullness extended 11 cm. to the left of the midsternal line in the fifth interspace. All sounds were forceful. There was a moderate systolic and a rumbling diastolic murmur at the apex. A moderate systolic murmur was heard over the base, being louder over the aortic area;  $A_2$  was greater than  $P_2$ . A mitral flush was present.

The veins over the abdomen were distended and filled from below. The liver was firm and nontender and extended three fingers breadth below the right costal margin. The spleen was not palpable. There was moderate edema of both legs and a fine tremor of the hands.

## THROMBOSIS OF THE PULMONARY ARTERIES

On admission, the diagnosis was: (1) Nodular goiter with possible hyperthyroidism, (2) rheumatic heart disease with mitral stenosis and insufficiency, (3) pulmonary tuberculosis, and (4) cirrhosis of the liver.

*Laboratory studies* revealed a normal urine except for a trace of albumin. Blood studies revealed 4,180,000 red cells with marked central pallor, 75 per cent hemoglobin, and 14,600 white cells (of which 96 per cent were neutrophils, 2 per cent lymphocytes, and 2 per cent monocytes). The icterus index was 4, and the platelets numbered 280,000. The coagulation time, bleeding time, clot retraction, and prothrombin time were normal. The sedimentation rate was moderately elevated, the blood sugar while fasting was 91 mg. per 100 cc., and the blood cholesterol was 83. Wassermann and Kahn tests of the blood gave negative reactions. Examination of the stool was negative. Sputum examinations were negative for tubercle bacilli and spirochetes. The bromsulphalein liver function test showed 32 per cent retention of the dye after thirty minutes. Gastric aspirations for tubercle bacilli were negative. The basal metabolic rate was plus 68 per cent.

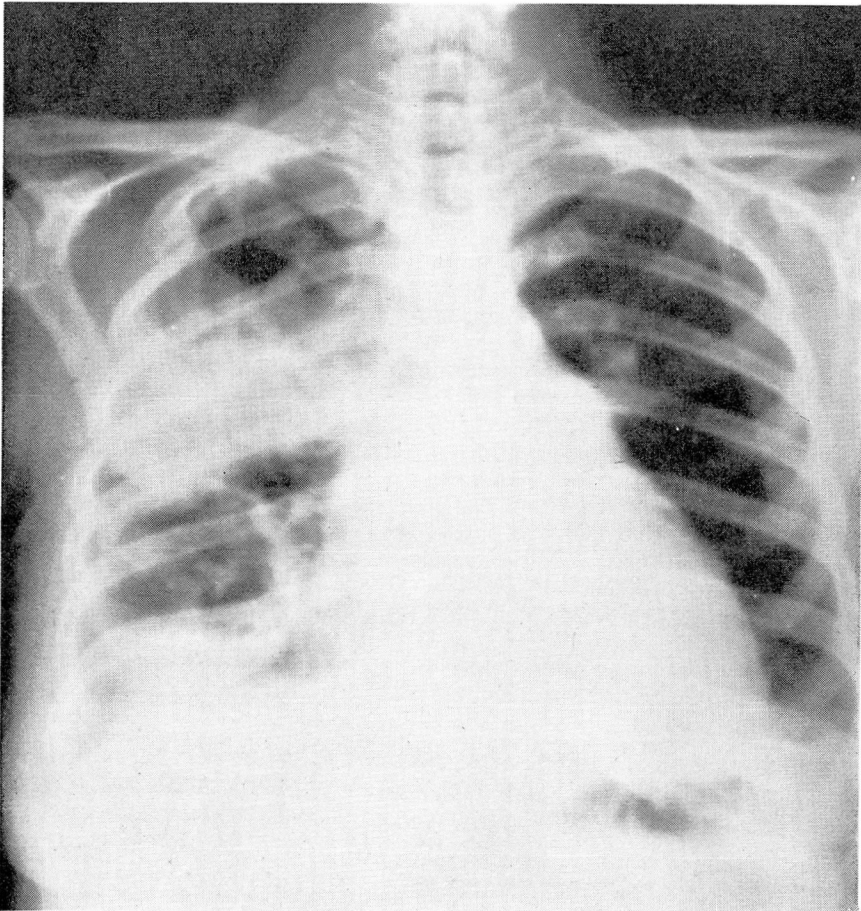


FIGURE 1: Roentgenogram of the chest showing large cavities in the right lung. These proved to be abscesses caused by ischemic necrosis.

Roentgen examination of the chest (Fig. 1) revealed an enlarged heart, an inflammatory process with cavitation in the upper right lung, partial pneumothorax on the right side, and a large cavity containing fluid in the lower lobe of the right lung. The mediastinum was obscured.

On admission to the hospital, the temperature was 101.3° F., the pulse rate 120, and respirations 26 per minute. On the third day, roentgen therapy was administered to the region of the thyroid gland, 200 r being given at that time. Two additional treatments of 200 r each were given, making the total dose 600 r. The temperature returned to normal following the first administration of roentgen therapy.

The first strength tuberculin test (purified protein derivative) was negative, but the second strength tuberculin (P. P. D.) was strongly positive. On May 7, 1940, the seventh day in the hospital, numerous petechiae appeared on both legs and the abdomen. Special blood studies revealed no evidence of blood dyscrasia. On this day, the patient became more dyspneic, acutely cyanotic, and suddenly expired.

*Necropsy* revealed that the right lobe of the liver was grossly enlarged and extended to the level of the iliac crest. The left lobe of the liver was absent. The remaining abdominal organs occupied their normal positions and were not grossly enlarged. The abdominal cavity contained no free fluid.

The iliac veins were thin, fibrous cords and were densely adherent to the surrounding structures, apparently from an old phlebitis. Section showed the veins to be occluded up to the inferior vena cava. Canalization was evident, particularly on the left side.

The right pleural cavity contained about 200 cc. of turbid, yellow fluid lying in its lower lateral part. Most of the right lung was adherent to the chest wall. On removing it, a part of the lower lateral wall was torn, revealing a large cavity in the lower lobe. Except for a thin shell of pleura and underlying tissue, almost the entire upper quarter of the lung was absent. At the lower limit was an irregular necrotic wall of an abscess cavity. In the anterior part of the lower lobe was a grossly irregular abscessed cavity which also involved the greater part of the middle lobe. It measured 6 x 6 x 4.5 cm., contained little pus, and consisted primarily of necrotic tissue.

At the entrance to the branch of the pulmonary artery supplying the upper lobe, a moderately large, partly calcified thrombus measuring 1.5 x 0.8 cm. was firmly attached to the wall of the vessel, completely occluding it. There was marked narrowing of the branches of the pulmonary artery which supplied the anterior portion of the lower lobe. The cavities in areas supplied by these vessels resulted from ischemic necrosis.

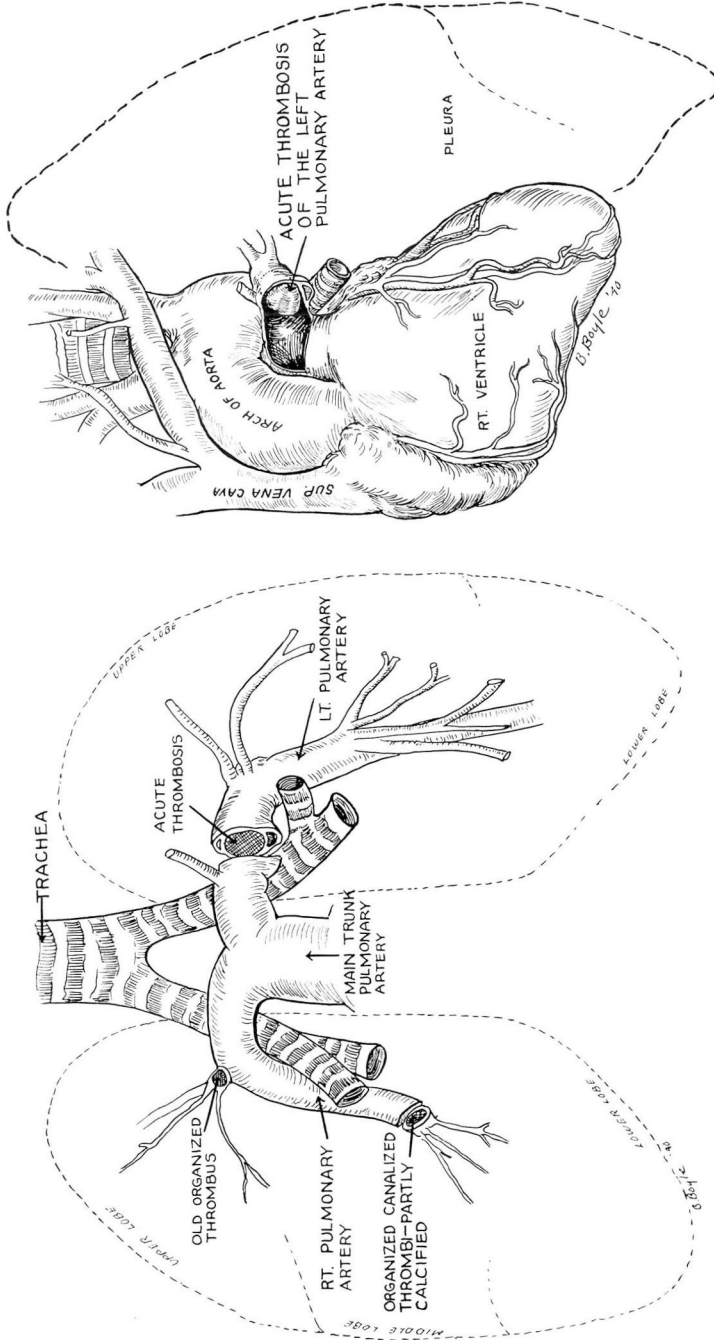
In the left lung, there were no infarcts or gross pneumonic areas. Throughout the lower lobe were areas of partial atelectasis, congestion, and edema. In the branch of the pulmonary artery which led to the lower lobe there was a large organized thrombus measuring 3 x 1.5 cm. which almost completely occluded the vessel (Fig. 2 A and B). The upper lobe was normal.

The heart weight 350 grams. The right auricle and ventricle were markedly dilated. The left side of the heart was normal. The appearance and measurement of the valves were normal.

Gross and microscopical section of the liver showed well-advanced, diffuse, fatty degeneration.

The thyroid gland was finely lobulated and showed some increase in colloid. The right lobe weighed 28 grams and the left lobe, 15 grams. Some small adenomas were present on the upper pole of the right lobe. Sections from both lobes showed slight hyperplasia.

THROMBOSIS OF THE PULMONARY ARTERIES.



A.  
B.

FIGURE 2: A. Drawing of pulmonary arterial supply from necropsy specimen. Note the partial obliteration of the peripheral arteries on the right side from old thrombi occluding the branches to the anterior part of the upper lobe and anterior portion of the lower lobe.  
B. Necropsy finding of the secondary, acute, almost complete, occlusion of the left pulmonary artery.

## DISCUSSION

Sclerosis of the pulmonary arterioles, and the pulmonary artery with or without general arteriosclerosis is not uncommon. Montgomery<sup>1</sup> described a case of thrombosis of the pulmonary artery similar to the case presented above. In his case, the patient died of circulatory failure. At necropsy the essential lesions were thrombi obstructing the branches of the pulmonary artery. The following explanation for the etiology of the thrombi was given: "It is conceivable that the thrombus in the left main branch of the pulmonary artery had resulted from partial organization of an embolus arrested here after parturition eight years ago, for according to the history the patient had never been completely well since that time." This corresponds with our case, as our patient dated the onset of her symptoms to a difficult labor four years previously. In Montgomery's case, there were 4,500,000 red cells with 60 per cent hemoglobin and 16,000 white cells. As all cases he reviewed developed extreme hypertrophy of the right ventricle, he concluded: "Pulmonary artery obstruction whether of the larger or smaller branches induces a hypertrophy of the right ventricle greatly in excess of that ordinarily produced by long standing mitral disease." Characteristic findings in thrombosis of the pulmonary arteries are: cyanosis and dyspnea, erythrocytosis in long standing disease, a high percentage of hemoglobin, and a color index less than 1.

No case similar to ours with regard to the presence of hypermetabolism could be found in the literature. The pathological condition in the liver might be explained by the obliteration of the iliac vessels. The rare condition of obliterating arteritis may lead to pulmonary infarction. Rothchild and Goldbloom<sup>2</sup> described a case of obliterating arteritis of the smaller pulmonary arteries in which on two occasions there was an elevation of the basal metabolic rate to plus 27 and plus 37. In their patient, the thyroid gland was not palpable, but the thyrotoxicosis was suggested when the patient was first examined. Hence, the surgeon is confronted not only with the differential problem of circulatory failure because of the cyanosis and dyspnea, but also with the problem of possible thyrotoxicosis because of the elevated metabolic rate. However, these authors believed that thyrotoxicosis was not likely since the blood volume, circulatory time, and cardiac output were not increased as they usually are in thyrotoxicosis.

Brenner<sup>3</sup>, who has made an intensive study of the pulmonary circulation, does not mention an elevation of the basal metabolic rate in pulmonary artery thrombosis. In his estimation, it is difficult to determine whether or not symptoms of cyanosis, dyspnea, hemoptysis, and pain are due to pulmonary thrombosis or to underlying heart disease. He points out that the patient does not die with this disease until 86 per cent of the vessels have been occluded. This accounts for the relative period of

## THROMBOSIS OF THE PULMONARY ARTERIES

chronicity of the disease. He also stated that the condition is rarely diagnosed during life because the symptoms are those of ordinary congestive failure. Brenner found many reported cases of thrombosis of the pulmonary arteries, but few cases in which both were occluded. In these cases, the occlusion was completed by an acute thrombosis superimposed on a chronic one. Sudden death was accompanied by pain in the chest, dyspnea, and increasing cyanosis caused by sudden thrombosis of the remaining unoccluded vessels.

### SUMMARY

1. A case with the symptoms and signs of circulatory failure and definite cardiac findings has been presented. However, other findings were superimposed upon the cardiac findings to make a diagnosis of heart disease questionable. Clinical and laboratory studies showed evidence suggestive of hyperthyroidism, pulmonary pathology and cirrhosis of the liver.

2. Necropsy findings of obliterated iliac vessels producing a peripheral edema, thrombosis of the pulmonary arteries with subsequent pulmonary infarctions, necrosis, and ultimate cavitation placed the diagnosis in an entirely different category. The enlargement of the right side of the heart was caused by the thrombosis of the pulmonary vessels.

The degree of thyroid hyperplasia did not seem sufficient to produce the marked elevation in the basal metabolic rate. The enlargement of the liver probably was caused by the disturbance of the iliac circulation. The absence of the left lobe would account for hypertrophy of the remaining lobe. There was no evidence of cirrhosis of the liver at necropsy.

3. We were unable to find a parallel case in the literature. Montgomery's case was similar to the one presented, but evidence of an increased metabolic rate, pulmonary cavitation, or enlargement of the liver was not mentioned. The case presented by Rothschild and Goldbloom was one of obliterating arteritis of the smaller pulmonary vessels with the same clinical picture as our case and the one presented by Montgomery, but with an increased metabolic rate of plus 27 per cent and plus 37 per cent on two occasions.

### CONCLUSIONS

Thrombosis of the pulmonary arteries is rarely diagnosed before death because the symptoms and signs are those of ordinary congestive failure. The condition is not too uncommon to warrant consideration in all cases presenting cyanosis and dyspnea in the presence or absence of cardiac findings or erythrocytosis.

### REFERENCES

1. Montgomery, G. L.: Case of pulmonary artery thrombosis with Ayerza's syndrome, *J. Path. and Bact.*, 41:221-230, (September) 1935.
2. Rothschild, M. A. and Goldbloom, A. A.: Clinical studies in circulatory adjustments; obliterating pulmonary arteritis with secondary pulmonary changes and right ventricular hypertrophy; report of a case with autopsy, *Arch. Int. Med.*, 61:600-608, (April) 1938.
3. Brenner, O.: Pathology of the vessels of pulmonary circulation, *Arch. Int. Med.*, 56:211, Aug.; 457, Sept.; 724, October; 976, November; 1189, December, 1935.