



ASHISH ATREJA, MD, MPH

Department of Internal Medicine,
The Cleveland Clinic

CYNTHIA ABACAN, MD

Department of Internal Medicine,
The Cleveland Clinic

ANGELO LICATA, MD, PhD

Department of Endocrinology,
The Cleveland Clinic

A 51-year-old woman with debilitating cramps 12 years after bariatric surgery

A 51-YEAR-OLD WOMAN is admitted to the hospital because of generalized muscle cramps that began 6 months ago and increasing right leg pain that began a few weeks ago. The muscle cramps are intermittent and are more pronounced in the abdomen and legs. She rates the leg pain as 10 on a scale of 10, and the pain makes her nearly bedridden at the time of admission. Other symptoms include increased anxiety, labile mood, and scalp pruritus.

About 12 years ago, the patient underwent partial gastrectomy with biliopancreatic diversion and duodenal switch for morbid obesity. At that time she weighed 690 pounds, but her weight has steadily decreased to 290 pounds now.

She has been taking multivitamins and calcium 500 mg/day since her bariatric surgery. Her primary care doctor recently diagnosed her with fibromyalgia and prescribed a selective serotonin reuptake inhibitor, a non-steroidal anti-inflammatory drug, and a fentanyl patch.

Physical examination

The patient appears anxious and seems to be in distress due to pain.

Vital signs. Afebrile, pulse 99, respiratory rate 22, blood pressure 140/69 mm Hg.

Head and neck. Conjunctival pallor, scratch marks on the scalp.

Chest. Clear to auscultation, normal heart sounds without murmurs or clicks.

Abdomen. Gastrectomy scar, no tenderness, good bowel sounds.

Musculoskeletal system. Tenderness over the ribs bilaterally. The right hip is painful and tender with limited range of motion. The pain increases with any active or passive

movement of the leg. She is having intermittent muscular cramps in her trunk and lower extremities, which seem to be increased with touch and movement.

Nervous system. Higher mental functions and cranial nerves are intact. A positive Chvostek sign (contraction of the ipsilateral facial muscles on tapping the facial nerve) and a positive Trousseau sign (induction of carpal spasm by reducing blood flow with a tourniquet or blood pressure cuff) both indicate hypocalcemia. Deep tendon reflexes are symmetric with normal plantar flexion bilaterally.

Serum laboratory values

- Calcium 5.1 mg/dL (normal 8.5–10.5)
- Phosphorus 2.3 mg/dL (normal 2.5–4.5)
- Magnesium 1.5 mg/dL (normal 1.6–2.4)
- Albumin 3.7 g/dL (normal 3.5–5.5)
- Alkaline phosphatase 498 U/L (normal 20–120)
- Normal aspartate aminotransferase, alanine aminotransferase, bilirubin, and gamma-glutamyl transpeptidase levels
- Hemoglobin 10.3 g/dL (normal 12–16)
- Mean corpuscular volume 110 fL (normal 86–98)
- Creatinine 0.5 mg/dL (normal 0.7–1.4)
- Normal amylase and lipase levels.

DIFFERENTIAL DIAGNOSIS

1 Which of the following can most likely explain the hypocalcemia in this patient?

- ☐ Hypoalbuminemia
- ☐ Pancreatitis
- ☐ Hypoparathyroidism
- ☐ Magnesium deficiency
- ☐ Vitamin D deficiency

She has:

- Weakness
- Cramps
- Calcium 5.1
- Phosphorus 2.3

Hypoalbuminemia is the most common cause of low total serum calcium. The level of metabolically active calcium (ie, serum ionized calcium) can be measured directly, or it can be estimated from the total serum calcium level by adjusting for albumin. The serum calcium concentration is adjusted upward by 0.8 mg/dL for each 1 g/dL decrease in serum albumin below a value of 4 g/dL.

Our patient's corrected calcium level is calculated to be 5.34 mg/dL (normal 8.5–10.5). Thus, hypoalbuminemia fails to account for the clinically severe hypocalcemia in this patient.

Acute pancreatitis leads to tissue necrosis and causes calcium to precipitate in the retroperitoneum. A serum calcium level lower than 8 mg/dL is a criterion of severity in acute pancreatitis.¹

However, this patient did not present with acute symptoms typical of pancreatitis, nor did she have any elevation of serum amylase or lipase.

Hypoparathyroidism can also lead to hypocalcemia accompanied by hyperphosphatemia. It can either be primary or secondary.

Primary hypoparathyroidism is often associated with disorders of the autoimmune system.

Acquired hypoparathyroidism is most commonly seen after neck surgery. Hungry-bone syndrome, in which available calcium goes into bones during episodes of relative hypoparathyroidism, is also seen in this situation. Other causes of acquired hypoparathyroidism include neck irradiation, infiltrative diseases of the parathyroid glands, and human immunodeficiency virus infection in some cases.²

The patient does not have any history of head and neck surgery or radiation, which decreases our suspicion for secondary hypoparathyroidism. However, this still needs to be further evaluated.

Magnesium depletion is an often overlooked cause of hypocalcemia. It can lead to functional hypoparathyroidism due to resistance to parathyroid hormone (PTH) and decreased PTH secretion. However, hypocalcemia only occurs in severe magnesium depletion—serum magnesium concentrations below 0.96 mg/dL.

This patient has mild hypomagnesemia, but it is not sufficient to explain all of the clinical features seen.

Vitamin D deficiency leads to hypocalcemia by decreasing calcium absorption from the gastrointestinal tract and increasing urinary loss of calcium. Severe cases may present with neuromuscular irritability such as clumsiness, myalgia, cramps, muscle spasms, and possibly the Chvostek sign and the Trousseau sign. In addition, it can lead to osteomalacia, which may present with diffuse bone and muscle pain with elevated alkaline phosphatase levels.³

Our patient has a history of bariatric surgery, muscle spasms, and pain and has abnormal levels of serum calcium, phosphorus, and alkaline phosphatase, suggesting vitamin D deficiency and associated osteomalacia as the underlying cause.

Other causes of hypocalcemia include acute and chronic hyperphosphatemia, acute respiratory alkalosis, and intravenous complexing of calcium with citrate or ethylenediaminetetraacetic acid (EDTA), as in multiple blood transfusions. Acute hyperphosphatemia may occur in rhabdomyolysis, tumor lysis syndrome, and acute renal failure. Chronic hyperphosphatemia is nearly always due to chronic renal failure.

This patient does not have any such predisposing conditions and her renal function is normal. Moreover, her serum phosphorus level is not elevated, suggesting a cause of hypocalcemia other than hyperphosphatemia or chronic renal failure.

■ ADDITIONAL TESTING CONSIDERED

2 Which serum laboratory measurement would help distinguish osteomalacia from other metabolic bone diseases?

- ☐ Calcium
- ☐ Alkaline phosphatase
- ☐ 25(OH)-vitamin D
- ☐ PTH
- ☐ All of the above

Metabolic bone diseases

Metabolic bone diseases—osteoporosis, osteitis fibrosis cystica, Paget disease, and osteomalacia—result in low bone density or

**Low albumin
is the most
common cause
of low calcium**

TABLE 1

Serum laboratory abnormalities in metabolic bone diseases

DISEASE	CALCIUM	PHOSPHORUS	ALKALINE PHOSPHATASE
Osteoporosis	Normal	Normal	Normal
Osteitis fibrosa cystica*	Increased	Decreased or normal	Increased or normal
Paget disease	Normal	Normal	Increased or normal
Osteomalacia	Decreased or normal	Decreased or normal	Increased

*The parathyroid hormone level is increased in this condition

strength or both. They can be differentiated on the basis of various laboratory abnormalities (TABLE 1) and radiographic features. All of the above measurements are helpful.

Osteoporosis is defined as a low bone mass that results in a fragile bone structure. Serum calcium, phosphate, and alkaline phosphatase levels are typically normal in osteoporosis, in contrast to osteomalacia.

Osteitis fibrosa cystica (cystic bone destruction) is a pathologic condition associated with hyperparathyroidism.⁴ Primary hyperparathyroidism is diagnosed by demonstrating hypercalcemia in the presence of normal to elevated parathyroid hormone levels.

Paget disease (osteitis deformans) is a disorder characterized by aberrant bone metabolism. It is often an incidental finding on a radiograph. Serum calcium and phosphorus levels are usually within normal limits. However, alkaline phosphatase may be elevated, suggesting high bone turnover in these patients. Many patients have no symptoms and often do not require therapy.

Osteomalacia (inadequate or delayed mineralization of osteoid in mature cortical and spongy bone) may be asymptomatic or present with diffuse bone pain and tenderness and muscle weakness. The bone pain is usually most pronounced in the lower spine, pelvis, and lower extremities where fractures have taken place, and may be associated with tenderness to palpation.

Radiographically, the most common findings are reduced bone density with thinning of the cortex, but they are very nonspecific. More specific abnormalities are Looser zones and changes in vertebral bodies.

Looser zones are narrow radiolucent lines that are perpendicular to the cortical margins of bones. They are often bilateral and symmetric. They are usually found at the femoral neck or shaft, but may also occur in the ulna, scapula, clavicle, rib, and metatarsal bones.

Radiographs of the vertebral bodies show loss of radiologic distinctness of the bony trabeculae and concavity of the vertebral bodies ("codfish vertebrae").

If the clinical presentation is compatible with osteomalacia, a thorough history and physical examination in combination with noninvasive tests such as serum calcium, phosphorus, and alkaline phosphatase levels and radiographs may be sufficient for diagnosis.⁵

This patient has low serum calcium and phosphorus and elevated alkaline phosphatase. Her radiographs show multiple fractures of the ribs, a recent fracture of the right inferior pubic ramus, and a healing fracture of the right proximal femur. A bone scan shows evidence of Looser zones with multiple areas of increased uptake in the ribs bilaterally, thoracic vertebrae, left ischial tuberosity, and right proximal femur.

Up to 1/3
of healthy
people develop
vitamin D
deficiency in
winter



FINDING THE UNDERLYING CAUSE OF THE OSTEOMALACIA

Osteomalacia can be due to many conditions (TABLE 2). Of these, vitamin D deficiency is the most common, especially among the elderly, those living in nursing homes, and in northern climates.

Vitamin D comes from dietary sources such as fish liver, fortified milk, infant formula, and cereals. It is also synthesized in the skin after exposure to the ultraviolet rays in sunlight. Addition of the 25(OH) group in the liver and the 1(OH) group in the kidneys converts vitamin D to 1,25(OH)₂D (calcitriol), the most active form of vitamin D (FIGURE 1).

The mechanisms of osteomalacia can often be distinguished on the basis of a complete history and laboratory testing. Levels of 25(OH)D and 1,25(OH)₂D can be measured in the laboratory; levels of 25(OH)D correlate better with the clinical signs and symptoms of vitamin D deficiency and should therefore be measured when vitamin D deficiency is suspected.

Our patient has a 25(OH)D level less than 3 ng/mL (normal 8.9–46.7). This suggests that a defect in intake or absorption of vitamin D is responsible for her osteomalacia.

As the body depletes its store of vitamin D, deficiency states develop, resulting in hypocalcemia, secondary hyperparathyroidism, and a low plasma calcium-phosphorus product. The consequences include increases in unmineralized osteoid, which is the hallmark of osteomalacia in adults and rickets in children.

Malabsorption of vitamin D is one of the major factors leading to osteomalacia among patients who have undergone gastrectomy.⁶ Reduced solubility of calcium and rapid passage of food through the duodenum also contribute to it.

Bariatric surgery and vitamin D deficiency

Bariatric surgery promotes weight loss by decreasing absorption of nutrients (by removing or rerouting part of the small intestine), restricting the amount of food that can be eaten (by banding or stapling part of the stomach), or both. For people who are morbidly obese, these procedures can take weight off and keep it off, but they can also lead to nutritional deficiencies.

TABLE 2

Causes of osteomalacia

Vitamin D-related

- Deficient intake or production
 - Dietary
 - Inadequate sunlight exposure
- Decreased absorption
 - Small-intestinal malabsorption
 - Gastrectomy
 - Hepatobiliary disease
 - Chronic pancreatic deficiency
- Defective metabolism
 - Cirrhosis
 - Anticonvulsants
 - Chronic renal failure
 - Tumor-associated osteomalacia
- Defective target-organ response
 - Hereditary vitamin D-resistant rickets

Other causes

- Hypophosphatemia
- Hypercalcemia
- Acidosis
- Fanconi syndrome
- Chronic total parenteral nutrition

Gastrectomy and intestinal bypass surgery are now among the leading causes of osteomalacia in the United States.⁷ In some series, up to 30% of patients developed osteomalacia after undergoing gastrectomy. In addition, the surgery can also lead to osteoporosis and its accompanying complications.

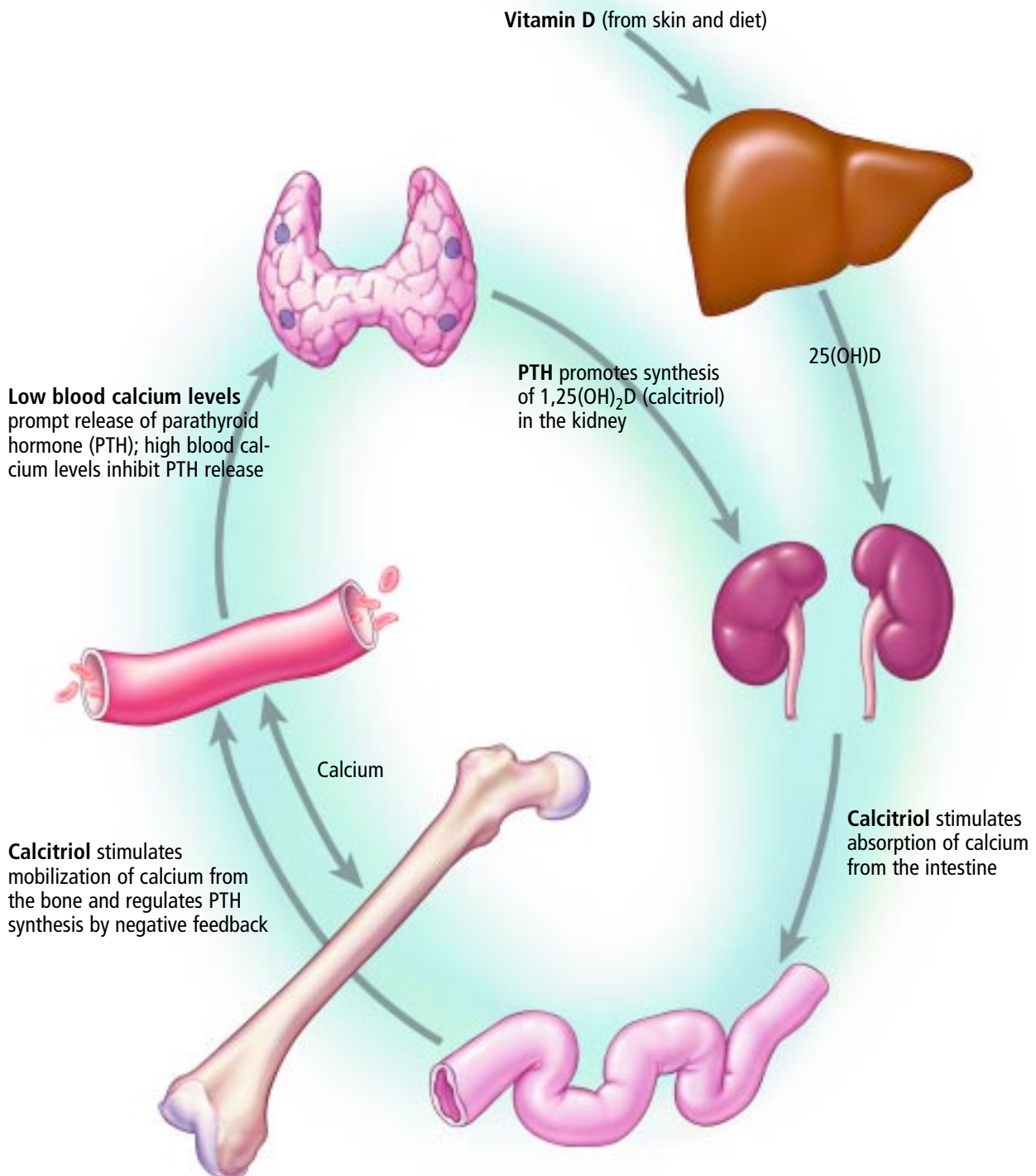
Though the number of gastrectomies and jejunoileal bypass procedures has declined with the advent of better alternatives, gastric restrictions, gastric bypasses, and biliopancreatic diversions for morbid obesity are still widely performed and are in fact gaining in popularity.

Our patient underwent biliopancreatic diversion, which involves transection of the stomach and anastomosis of the proximal part with a segment of ileum. The food passes from the stomach to the distal ileum without being adequately digested, leading to malabsorption.

In addition, she may also have had decreased endogenous production of vitamin D as a result of reduced exposure to sunlight while she was bedridden. In a recent study, Rucker et al⁸ found that as many as 34% of healthy people can develop vitamin D deficiency during fall and winter.

Patients taking vitamin D need at least 1 to 1.5 g of supplemental calcium a day

Hormonal control loop for vitamin D metabolism



ADAPTED FROM HOLICK F, KRANE S. INTRODUCTION TO BONE AND MINERAL METABOLISM. IN: BRAUNWALD E, FAUCI AS, KASPER DL, HAUSER SL, LONGO DL, JAMESON JL, EDITORS. HARRISON'S PRINCIPLES OF INTERNAL MEDICINE, 15TH ED. NEW YORK: MCGRAW HILL, 2001:2192-2205.

CCF
©2003

FIGURE 1



■ OTHER NUTRIENT DEFICIENCIES

3 This patient is likely to have a deficiency of which of the following nutrients, in addition to vitamin D?

- ☐ Vitamin A
- ☐ Vitamin K
- ☐ Vitamin B₁₂
- ☐ Trace elements
- ☐ All of the above

In any malabsorption syndrome or severe vitamin deficiency, other vitamin or mineral deficiencies should be looked for. Our patient underwent biliopancreatic diversion, which leads to malabsorption of fat and fat-soluble vitamins. Hence, she is predisposed to deficiencies of vitamins A, D, E, and K.

Gastrectomy and duodenal bypass also predispose to deficiency of vitamin B₁₂ (due to deficiency of intrinsic factor), iron, and trace metals (due to less absorptive area).

Deficiency of trace elements can lead to varied manifestations, eg:

- Zinc deficiency—hypogonadism, impaired wound healing
- Selenium deficiency—cardiomyopathy, skeletal muscle dysfunction, mood disorders
- Copper deficiency—disorders of metabolism such as defects in collagen formation, the electron transport chain, and erythropoiesis
- Chromium deficiency—impaired glucose tolerance and unfavorable lipid profiles.

Case continued

This patient is found to be deficient in vitamin A, selenium, zinc, and chromium, in addition to vitamin D. Recall that she also has anemia with macrocytosis, which is suggestive of vitamin B₁₂ deficiency, and this is confirmed by low serum vitamin B₁₂ levels. She has normal serum levels of copper, manganese, iron, and folate.

■ MANAGEMENT OF OSTEOMALACIA

The management of osteomalacia is directed towards correcting hypocalcemia and vitamin D deficiency and rectifying the underlying cause if possible. The goal of treatment is to achieve bone healing as evidenced by increased bone mineral density and normal

rates of urinary calcium excretion and levels of markers of bone turnover.

In cases of acute symptomatic hypocalcemia, rapid repletion of serum calcium is warranted. An intravenous calcium bolus should be infused in 10 to 20 minutes and repeated as necessary. For a prolonged effect, a continuous infusion of calcium should then be started at a rate of 15 mg of elemental calcium per kg over 4 to 6 hours, which will raise the serum calcium level by 2 to 3 mg/dL. This is continued until the patient is on an effective oral regimen of calcium and vitamin D.

Commercial preparations of vitamin D and its metabolites are many and include vitamin D₂ (ergocalciferol), vitamin D₃ (cholecalciferol), 1,25(OH)₂D (calcitriol), and synthetic vitamin D (dihydrotachysterol). Of these, ergocalciferol and calcitriol are most widely available. The dose varies with the disease, its etiology and severity, and the form of vitamin D used.

Ergocalciferol (Calciferol; Drisdol) is the cheapest form of vitamin D and can be given orally or intramuscularly. Severe malabsorption associated with gastrointestinal, liver, or biliary disease requires higher doses and intramuscular injection for adequate repletion. A disadvantage of ergocalciferol is that it may take as much as 1 month for its effect to be seen.

Calcitriol (Rocaltrol) has a faster onset of action (4–6 hours) and is most useful when rapid correction of vitamin D is required (as in our case) and in chronic renal failure (with decreased 1-alpha-hydroxylase). It can be given orally or intravenously.

Of importance: patients taking vitamin D supplements need to take at least 1 to 1.5 g of supplemental calcium a day.

■ HOSPITAL COURSE

The patient receives a bolus of intravenous calcium and a continuous calcium infusion for her symptomatic hypocalcemia. She is also started on intravenous calcitriol and vitamin B₁₂. Her pain, spasms, and anxiety improve considerably over the next 2 to 3 days. She is discharged home taking oral ergocalciferol, a multivitamin that contains trace elements, and high oral doses of cobalamin and calcium.

In acute symptomatic hypocalcemia, rapid calcium repletion calcium is warranted



In addition, she is scheduled to receive weekly intramuscular injections of ergocalciferol 50,000 IU for the first month.

■ OSTEOMALACIA, LOW VITAMIN D OFTEN ELUDE DIAGNOSIS

Metabolic bone diseases predispose to spontaneous fractures and are of great public health significance because of their effect on morbidity and mortality. Many of these diseases can be diagnosed early in their course and treated before the onset of major complications.

Osteomalacia and vitamin D deficiency, however, often elude early diagnosis because their symptoms of pain and fatigue are vague and nonspecific. Patients with bariatric surgeries are especially prone to develop these disorders. Awareness of the risk factors and laboratory abnormalities (such as hypocalcemia and increased alkaline phosphatase) may help early diagnosis and treatment.

Patients who undergo malabsorptive or distal bypass surgeries require long-term follow-up and supplementation with fat-soluble vitamins.



Acknowledgments. The authors thank Colleen Thomas, MD, Jennifer Wojtowicz, DO, and Robert Schurmar, DO, for their valuable feedback.

■ REFERENCES

1. Corfield AP, Cooper MJ, Williamson RC, et al. Prediction of severity in acute pancreatitis: prospective comparison of three prognostic indices. *Lancet* 1985; 2:403-407.
2. Lehmann R, Leuzinger B, Salomon F. Symptomatic hypothyroidism in acquired immunodeficiency syndrome. *Horm Res* 1994; 42:295-299.
3. Holick F, Krane S. Introduction to bone and mineral metabolism. In: Braunwald E, Fauci AS, Kasper DL, Hauser SL, Longo DL, Jameson JL, editors. *Harrison's Principles of Internal Medicine*, 15th ed. New York: McGraw Hill, 2001:2192-2205.
4. Khan A, Bilzekian J. Primary hyperparathyroidism: pathophysiology and impact on bone. *CMAJ* 2000; 163:184-187.
5. Bingham C, Fitzpatrick L. Noninvasive testing in the diagnosis of osteomalacia. *Am J Med* 1993; 95:519-522.
6. Efsthadiadou Z, Bitsis S, Tsatsoulis A. Gastrectomy and osteomalacia: An association not to be forgotten. *Horm Res* 1999; 52:295-297.
7. Tovey FI, Hall ML, Eli PJ, Hobsley M. A review of postgastrectomy bone disease. *J Gastroenterol Hepatol* 1992; 7:639-645.
8. Rucker D, Allan JA, Fick GH, Hanley DA. Vitamin D insufficiency in a population of healthy western Canadians. *CMAJ* 2002; 166:1517-1524.

ADDRESS: Angelo Licata, MD, Department of Endocrinology, A53, The Cleveland Clinic Foundation 9500 Euclid Avenue, Cleveland, OH 44195.