

**AMAN ALI, MD**Department of Internal Medicine,
The Cleveland Clinic Foundation**JANICE M. SANTISI, RN**Department of Gastroenterology and
Hepatology, The Cleveland Clinic
Foundation**JOHN VARGO, MD, MPH**Department of Gastroenterology and
Hepatology, The Cleveland Clinic
Foundation

Video capsule endoscopy: A voyage beyond the end of the scope

ABSTRACT

Video capsule endoscopy (VCE), an important innovation in diagnostic endoscopy, was approved in 2001 and is now widely available. In this system, the patient swallows a miniature high-resolution camera that is propelled by peristalsis through the gastrointestinal tract. It is particularly useful in examining the small intestine, which is difficult to visualize by conventional endoscopic techniques.

KEY POINTS

Because VCE can view the entire small intestine without pain, sedation, or air insufflation, it has many advantages over traditional diagnostic studies.

VCE's major clinical application is in the evaluation of obscure gastrointestinal bleeding, in which it is superior to push enteroscopy.

Several studies are investigating VCE's role in inflammatory bowel disease and other disorders of the small intestine.

We hope that the diagnostic algorithm for obscure gastrointestinal bleeding will change, with VCE replacing more invasive procedures as the initial investigative tool.

VIDEO CAPSULE ENDOSCOPY (VCE) is an exciting advance, as it can visualize the lumen of the entire small intestine. It is especially useful in finding the source of obscure gastrointestinal (GI) bleeding, and does not have many of the limitations of conventional endoscopic and x-ray procedures.

We will briefly discuss the pros and cons of the various diagnostic procedures and elaborate on the role of VCE.

OBSCURE GI BLEEDING

Of the 60 to 70 million Americans with GI disorders, almost one third have involvement of the small intestine—the most difficult part of the GI tract to view with traditional endoscopic methods.¹ The small intestine is often the suspected source of *obscure GI bleeding*, defined as chronic bleeding from a source not found on traditional endoscopy or small bowel radiography.²

Obscure GI bleeding can be occult or overt: *obscure occult bleeding* is characterized only by recurrent iron-deficiency anemia or recurrent positive fecal occult blood testing or both, while *obscure overt bleeding* is the recurrent passage of visible fecal blood.

Although obscure GI bleeding accounts for only 3% to 5% of all cases of GI bleeding,^{3,4} it has a significant economic impact on health resource utilization, with an estimated cost per patient of \$35,000.⁵

DRAWBACKS OF CONVENTIONAL PROCEDURES

Many procedures are used to detect and treat lesions in the small bowel. All of them have drawbacks, however (TABLE 1).

TABLE 1

Endoscopic techniques to view the small intestine

	PUSH ENTEROSCOPY	SONDE ENTEROSCOPY	INTRAOPERATIVE ENDOSCOPY	CAPSULE ENDOSCOPY
Diagnostic yield for obscure GI bleeding	30%–50% ^{10,11}	26%–77% ^{14,15}	58%–80% ^{16,17}	50%–70% ^{5,21–29}
Invasiveness	Invasive	Very invasive	Extremely invasive	Noninvasive
Testing location	Inpatient or outpatient	Inpatient	Inpatient	Ambulatory
Patient discomfort	Moderate	Severe	Extreme	No or mild
Can view the entire small intestine	No	Yes	Yes	Yes
Endotherapy potential	Yes	No	Yes	No
Can take biopsies	Yes	No	Yes	No
Sedation and analgesia needed	Mild	Moderate	Heavy	Not needed
Physician time	15–45 minutes ^{10,11}	Up to 4 hours ¹³ (average)	30–75 minutes ¹⁶ (endoscopy)	1 hour
Complications and limitations	Intestinal perforation Sedation Apnea Bleeding Infection	Epistaxis Perforation Bleeding Infection	General anesthesia Exploratory laparotomy Serosal tears Perforation Bleeding Infection	Capsule retention if there is an obstruction or stricture Capsule failure

**GI blood loss
must be at
least 0.1–0.4
mL/minute to
show up on
nuclear scans**

Esophagogastroduodenoscopy (EGD) goes only as far as the proximal small bowel.

Colonoscopy can only go as far up as the distal part of the terminal ileum—and going even that far can be challenging.⁶

Small bowel follow-through, in which the patient swallows a quantity of barium contrast and then undergoes a series of radiographs at intervals as the barium advances through the GI tract, is the most commonly used investigation for obscure GI bleeding. Although it can detect strictures and raised lesions such as tumors, its diagnostic yield for obscure GI bleeding is only 5%.⁷ Further, it cannot demonstrate mucosal details or flat vascular lesions such as angiodysplasias, which are one of the most common types of lesions in patients with obscure GI bleeding.⁸

Enteroclysis is similar to small bowel follow-through except that a special radiopaque mixture is introduced directly into the small bowel via a tube. Its diagnostic yield for small-bowel tumors and Crohn disease is about 90%, but its yield for obscure GI bleeding is only 10%. Further, it is time-consuming, must be done by a skilled radiologist, and exposes the patient to prolonged radiation, discomfort, and possibly the need for sedation.⁹

Nuclear scans and **angiography** are useful in locating active bleeding. The difficulty with scans is that they are very sensitive but sometimes not very specific. The sensitivity of nuclear scans in locating the approximate bleeding site can range from 40% to 90%. Additionally, blood loss must be at least 0.1 to 0.4 mL/minute for nuclear scans to achieve



■ Video capsule endoscopy goes where conventional endoscopy cannot

Most of the small intestine is inaccessible by conventional endoscopy, but a new diagnostic system called video capsule endoscopy can obtain images of the entire small intestine and is especially useful in finding the source of obscure gastrointestinal bleeding.

Esophagogastroduodenoscopy can reach the proximal small bowel.



Actual size

Push enteroscopy can go 80 to 120 cm past the ligament of Treitz, but is uncomfortable and time-consuming.

Colonoscopy can reach the distal part of terminal ileum.

Video capsule endoscopy.

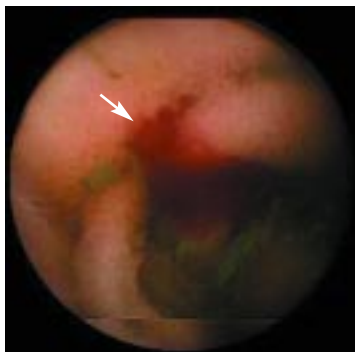
A miniature video camera is propelled by peristalsis through the gastrointestinal system. The capsule is used once and is not recovered.

Bleeding

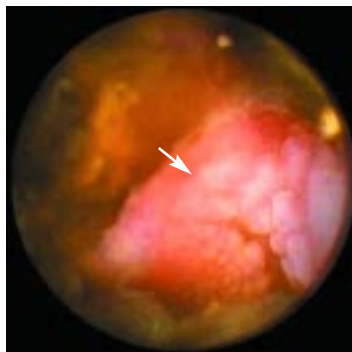CCF
©2004

FIGURE 1

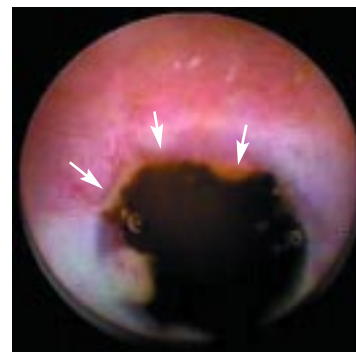What video capsule endoscopy can show



Active bleeding



Jejunal mass



Stricture

FIGURE 2

adequate sensitivity, and 0.5 to 1.0 mL/minute for angiography.² Therefore, these studies can be falsely negative if bleeding is intermittent.

Push enteroscopy uses a long endoscope (200–270 cm) to view the small intestine beyond the reach of a standard EGD scope. The diagnostic yield for push enteroscopy in evaluating obscure GI bleeding ranges from 30% to 50%.^{10,11}

Push enteroscopy offers the advantage of visualizing small mucosal lesions, angiodysplasias, and flat lesions in greater lengths of small intestine. Furthermore, it allows one to take biopsies and perform therapeutic interventions.

However, the procedure takes around 45 minutes and must be performed by a skilled endoscopist in an endoscopy suite. It is often uncomfortable for patients and usually requires sedation and analgesia.¹² Furthermore, at most, the enteroscope can go only 80 to 120 cm beyond the ligament of Treitz, hence leaving the distal small intestine unexamined.¹² Complications include bleeding and infection. Perforation, which is infrequent, is usually related to the use of an overtube to stabilize the scope in the stomach.

Sonde enteroscopy uses a long endoscope (270–400 cm), which is inserted transnasally into the stomach and then pushed through the pylorus with a gastroscope passed through the mouth. A balloon at the tip of the scope is then inflated, and peristalsis propels the scope through the small intestine.

In theory, sonde enteroscopy can examine the entire small intestine, although in

reality it fails to visualize the distal ileum in 75% of cases.¹³ The diagnostic yield of sonde enteroscopy varies from 26% to 77%.^{14,15}

This technique has been largely abandoned because it takes 6 to 8 hours, is uncomfortable, does not allow biopsies or therapeutic interventions, and can cause complications including bleeding and perforation.¹³ Additionally, the tip cannot be deflected, limiting examination of the mucosa.

Intraoperative endoscopy is the most invasive endoscopic technique for examining the small intestine. Highly effective, it is now often used for diagnosing and treating obscure GI bleeding, especially when less-invasive methods have failed to find the source of bleeding. However, it exposes the patient to the hazards of exploratory laparotomy and general anesthesia.^{16,17}

■ WHAT IS THE IDEAL SMALL-BOWEL TEST?

The ideal test would be minimally invasive and comfortable for patients, require minimal sedation or analgesia, visualize the entire small intestine, and make it possible to perform biopsy and therapeutic interventions.

Although we are still looking for the perfect test, VCE meets many of these criteria (FIGURE 1) and has a much higher diagnostic yield than traditional enteroscopy of the small bowel (FIGURE 2).

■ THE VIDEO CAPSULE SYSTEM

The VCE system (Given M2A, Given Imaging Limited, Yoqneam, Israel) has four

Patients must fast for 12 hours before swallowing the capsule

main components: the capsule, eight sensors similar to electrocardiographic leads pasted to the patient's abdomen, a data recorder worn on the patient's belt, and a computer workstation.

The capsule contains a color camera, six light-emitting diodes, a radio transmitter, an antenna, and two batteries (with an 8-hour life). It measures only 11 x 23 mm.

Propelled by peristalsis through the GI tract, the capsule acquires two high-quality video images per second. These images are transmitted to the sensors, which are connected to the data recorder. When the study is completed, the stored images are downloaded to the computer workstation, which can display the images as a video film.

■ HOW TO USE THE VIDEO CAPSULE

Patients must fast for 12 hours before the study and refrain from taking any medicines that could delay gastric emptying. No bowel preparation is necessary.

At the medical center, the sensors, data recorder, and battery pack are attached (**FIGURE 3**). Then, after swallowing the capsule with a small amount of water, patients are free to leave for their usual activities. They are allowed to drink clear liquids 2 hours after capsule ingestion and to eat a light meal 4 hours later.

Patients return to the hospital after approximately 8 hours, the data recorder is removed, and the images are downloaded and processed. Patients can resume their regular diet and activities afterwards but are advised to avoid magnetic resonance imaging (MRI) and radio transmitters until the disposable capsule passes in the stool, typically within 10 to 48 hours.¹⁸ They are told to notify the physician if they develop nausea, vomiting, or abdominal discomfort or if they do not see the capsule passed in the stool within 1 week.

■ STUDIES WITH VCE

Numerous experimental and clinical studies of VCE have shown encouraging results.

Iddan et al¹⁸ determined the safety of VCE in 10 healthy human volunteers in May 2000.

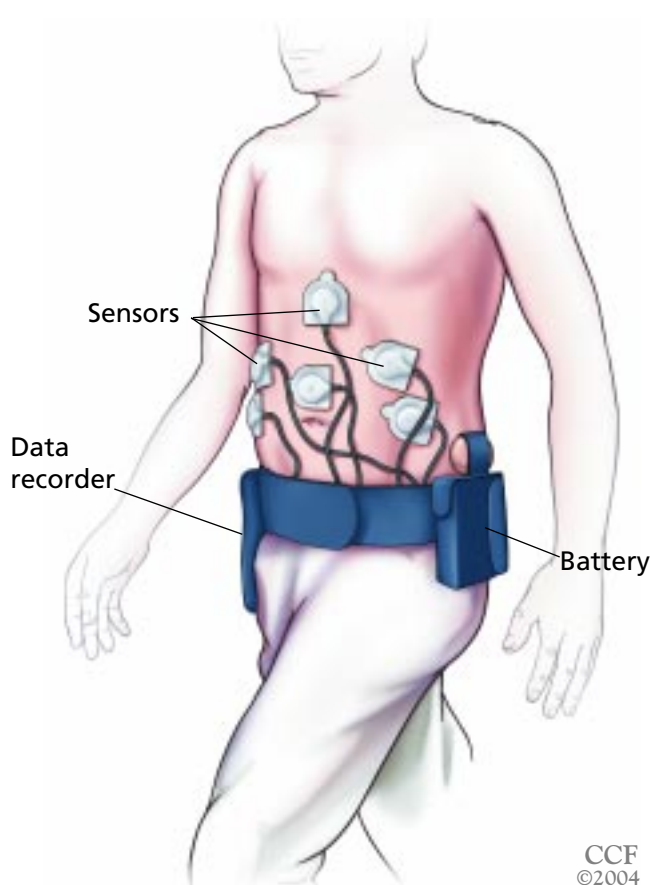


FIGURE 3. Images from the capsule are transmitted to the sensor array and stored in a data recorder worn on the patient's waist.

Appleyard et al¹⁹ demonstrated that VCE is more sensitive than push enteroscopy in detecting colored beads sewn into the small intestine of dogs (64% vs 37%, $P < .001$). The capsule detected beads that were beyond the reach of the push enteroscope.

VCE and obscure GI bleeding

Appleyard et al²⁰ first used VCE in four patients with recurrent GI bleeding and described it as a useful diagnostic tool for detecting lesions in the small intestine, ie, it yielded images of bleeding sources comparable to standard endoscopic images.

Scapa et al²¹ evaluated VCE in 35 patients with obscure GI bleeding. All had undergone radiography of the small bowel and some had undergone EGD and colonoscopy, all with normal results. VCE detected abnormal findings in 29 (83%) of the 35 patients.

Ulcers, erosions, and angiodysplasias were the most frequent lesions. Of these 29 patients, the definite bleeding source was found in 22 (76%). The overall diagnostic yield was therefore 63% (22 of 35 patients), which is higher than the yield of push enteroscopy (30%–50%).

Several other trials^{5,22–29} demonstrated that VCE is highly effective in diagnosing obscure GI bleeding. The diagnostic yield was between 55% and 83%.^{5,24–29} VCE was successful even when extensive diagnostic studies such as EGD, colonoscopy, push enteroscopy, small bowel radiography, enteroclysis, tagged red blood cell scans, angiography, computed tomography, and MRI failed to show the bleeding source.

Limitations of the trials. Although the results are encouraging, we must bear in mind that these trials had certain limitations, eg:

- Most of them were retrospective and uncontrolled.
- Many were published in abstract form only.
- Data are not available about long-term outcomes, eg, in how many patients did VCE provide a definitive diagnosis, how many had recurrent bleeding or needed further diagnostic workups, and what were the complication rates.
- The studies failed to explain if the lesions detected by VCE were the actual source of bleeding.

VCE vs push enteroscopy

Several clinical trials^{23,28,30–36} found VCE superior to push enteroscopy in detecting lesions of the small intestine.

Lewis and Swain,³⁰ in a pilot study, compared VCE and push enteroscopy in 21 patients with obscure GI bleeding who had previously undergone extensive diagnostic procedures with negative results.

The diagnostic yield for VCE was 55%, vs 30% for push enteroscopy ($P = .0625$). Although this difference did not reach statistical significance, VCE displayed the distal bleeding source that was missed by push enteroscopy in 5 of 14 patients. Neither procedure caused any complications.

Ell et al³¹ compared VCE with push enteroscopy in 32 patients with chronic GI

bleeding in a prospective controlled trial. The patients had undergone multiple procedures, including EGD, colonoscopy, enteroclysis, nuclear scans, angiography, and Meckel scan. The conventional studies detected the bleeding source in 5 (16%) of the 32 patients, whereas VCE detected the source in 21 (66%), and push enteroscopy detected the source in 9 (28%) ($P < .001$). Neither VCE nor push enteroscopy caused any complications.

Other clinical trials^{23,28,32–36} demonstrated a higher diagnostic yield for VCE (50%–80%) than for push enteroscopy (20%–45%). Although the results favor VCE, all but two of these studies^{30,31} were published in abstract form only.

VCE vs small-bowel radiography

Costamagna et al³⁷ prospectively compared VCE and radiographic studies in 20 patients with suspected diseases of the small bowel, including 13 with obscure GI bleeding. All had undergone multiple diagnostic procedures before the study, with negative results.

Barium studies were negative in 17 (85%) of the 20 patients and demonstrated ileal nodularity in 3 (15%). VCE identified abnormalities in 17 (85%) of the 20 patients, mostly angioectasias (47%) and polyps of the small bowel (24%).

After the authors applied strict criteria to determine if the angioectasias were the actual source of bleeding, they classified the VCE findings as suspicious in 8 (40%) of 17 patients and diagnostic in 9 (45%). On the other hand, small-bowel radiography was diagnostic in only 4 (20%) of 20 patients. The difference in diagnostic yield became more obvious when both techniques were compared for evaluating obscure GI bleeding (31% vs 5%, $P < .05$).

Liangpunsakul et al³⁸ found VCE more sensitive than enteroclysis (performed by experts in the technique) for detecting ulcers in the small intestine.

Leighton et al³⁹ found VCE to be superior to small bowel follow-through and CT.

VCE in diagnosing Crohn disease

Crohn disease involves the small intestine in 30% to 40% cases. In most patients it can be diagnosed by EGD, colonoscopy, and barium

After
swallowing
the video
capsule,
patients can
go about their
business

radiography. However, in a minority of cases these techniques fail to reveal any involvement of the small intestine despite a high clinical suspicion.

Fireman et al⁴⁰ demonstrated that VCE is highly effective for diagnosing small intestinal involvement in Crohn disease that is frequently missed by conventional tests. Seventeen patients with suspected Crohn disease participated in the study. Symptoms included a combination of iron deficiency anemia, diarrhea, abdominal pain, and weight loss, with a mean duration of symptoms of about 6 years. Patients with a history of small-bowel obstruction, major abdominal operations, radiographic evidence of strictures, or recent use of nonsteroidal anti-inflammatory drugs were excluded.

VCE revealed findings consistent with Crohn disease in 12 (71%) of the 17 patients. The findings included mucosal erosions, ulcers, and strictures (primarily in the distal small bowel).

Katz and Lewis⁴¹ investigated the role of VCE in the diagnosis and treatment of known or suspected Crohn disease. VCE visualized lesions consistent with Crohn disease in 5 of 7 patients with obscure GI bleeding and 2 of 15 patients with other symptoms.

Additionally, 13 (72%) of the 18 referring physicians believed that VCE facilitated the diagnosis, and 11 (61%) felt that it led to a change in subsequent management. Among the patients, 15 (94%) of 16 patients considered it valuable and 14 (88%) of 16 were reassured.

VCE in small-bowel transplant surveillance

Patients with small-bowel transplants are usually monitored with ileoscopy through the ileostomy that is created at the time of transplantation.

Although ileoscopy displays only the distal 15 cm of the transplanted bowel, it offers an opportunity to take biopsies. Furthermore, it helps in monitoring the small-intestinal healing and villous recovery, and in detecting complications such as graft-vs-host disease.

De Franchis et al⁴² reported the use of VCE in five patients with small-bowel transplants. VCE was performed at various intervals ranging from 20 days to 6 months after

the transplantation. VCE displayed posttransplant changes that ranged from blunted white villi seen at day 20 to normal villi observed at 6 months.

■ EMERGING CLINICAL APPLICATIONS

The use of VCE is being evaluated in various clinical situations in adults and children,⁴³ including:

- Diagnosing Meckel diverticulum⁴⁴
- Diagnosing the rare problem of varices in the small bowel in patients with portal hypertension and obscure GI bleeding⁴⁵
- Detecting tumors and polyps in the small bowel.^{22,23,27,28}

Should motility agents be given before VCE?

The capsule's transport time through the GI tract depends entirely on peristalsis, and it can vary from very slow to extremely fast. If the capsule is propelled very slowly, then it may not be able to reach the distal ileum before the battery runs out, hence leading to an incomplete examination. On the other hand, if it is too fast then fewer images will be recorded, increasing the chance that small lesions will be missed. Some patients may therefore need to take a prokinetic drug during the VCE study, but others should not.

Seitz et al⁴⁶ have described a simple method for determining the need for prokinetic drugs. One hour after capsule ingestion, a second recorder/sensor array is held near the patient's abdomen and images are downloaded for 2 minutes. If the gastric mucosa is seen, the capsule is still in the stomach and the patient should receive a prokinetic agent, but not if the mucosa of the small intestine is seen. However, delayed gastric emptying was not validated with solid-phase gastric emptying (the gold standard) in this study.

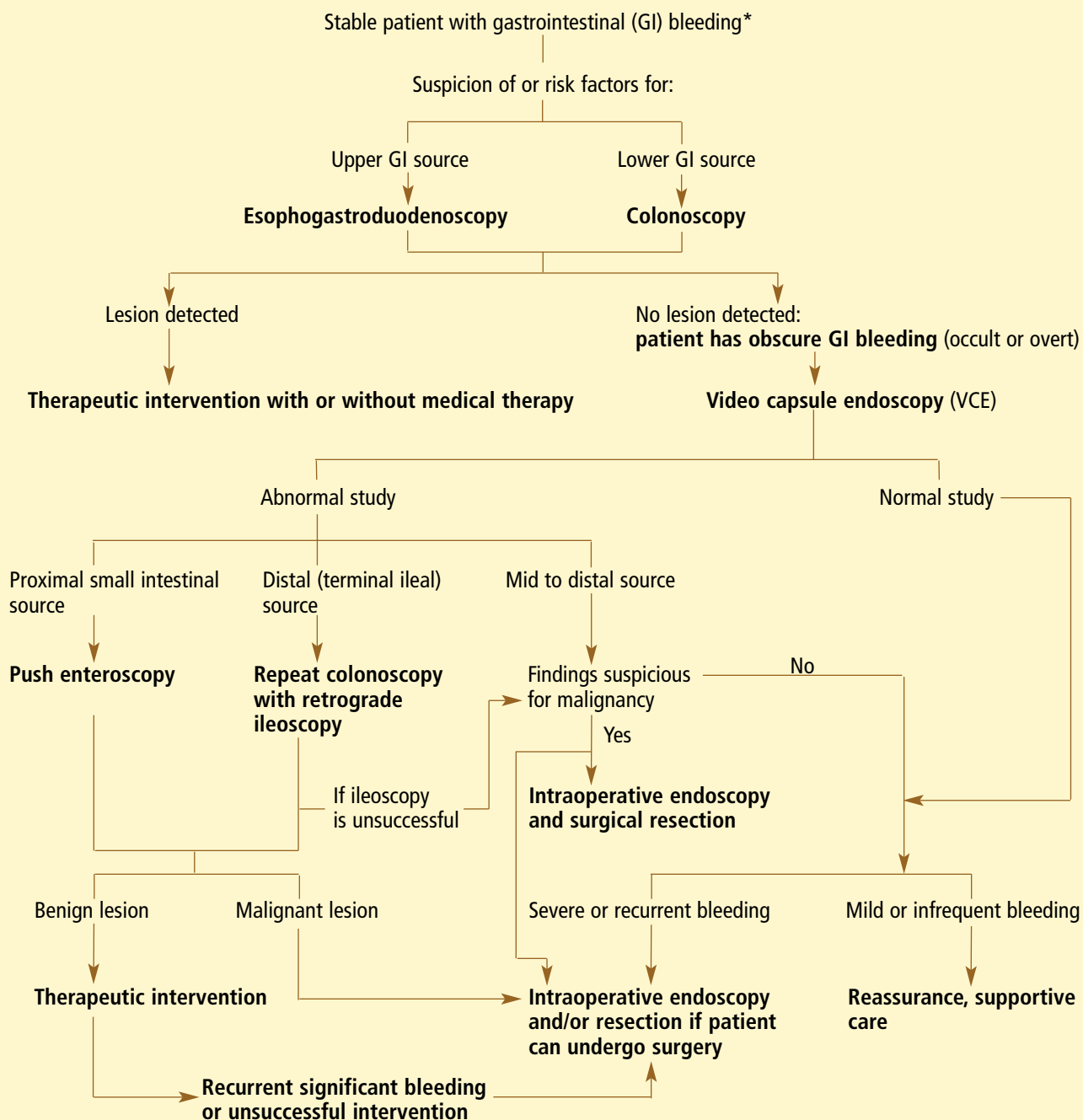
■ LIMITATIONS OF VCE

VCE cannot be used to take biopsy samples or perform therapeutic interventions.

VCE is also labor-intensive for the endoscopist, taking 50 to 100 minutes to review the images from one examination.^{31,47} Personnel other than endoscopists (ie, nurses) may be able to screen the images, however,

**A caveat:
long-term
outcomes of
capsule
endoscopy are
not available**

Proposed algorithm for using video capsule endoscopy for obscure gastrointestinal bleeding



*Unstable patients should be aggressively resuscitated, and angiography should be performed after negative esophagogastroduodenoscopy and colonoscopy in the setting of ongoing bleeding.

FIGURE 4



saving considerable time and money.⁴⁷ In a study performed at our institution, a registered nurse with specialized training in VCE was as accurate as physicians in the interpretation of studies.⁴⁷

In addition, VCE images must be carefully interpreted in the context of the clinical findings, as not all abnormal findings are the actual cause of the patient's symptoms.

VCE is costly, but comparable to other endoscopic procedures. The disposable capsule itself costs about \$450, and the labor time for the physician and nurses and the facility overhead bring the total average cost to around \$850. On the other hand, the potential impact of VCE on decreasing health resource utilization in patients with obscure GI bleeding alone can be significant. This can be achieved by providing a definitive diagnosis earlier and eliminating the need for future hospitalizations and diagnostic and therapeutic procedures.⁵

Technical problems encountered during VCE include capsule failure (defined as transmission time shorter than 30 minutes), transmission gaps, and incomplete visualization of the small bowel due to short battery life or slow propulsion.⁴⁸

Furthermore, none of the published studies has addressed the sensitivity and specificity of VCE, as this calculation would require comparing VCE with a gold-standard test such as intraoperative endoscopy. In the absence of such a comparison, we have to rely on the diagnostic yield. The problem with diagnostic yield is that it cannot differentiate true-positive findings from false-positives. This means that we cannot tell whether a red spot identified during VCE is an incidental angiodysplasia or is the actual cause of the patient's bleeding. Additionally, to learn the physiological variations of the findings detected by VCE, we will need to perform a large study in healthy human volunteers.

■ CONTRAINDICATIONS TO VCE

The main risk during VCE is capsule retention, which may require surgical intervention. The reported incidence of capsule retention is less than 1%.⁴⁹ Nevertheless, VCE is contraindicated in patients with known or sus-

pected GI obstruction, strictures, or fistulae.

Other contraindications include Zenker diverticulum, swallowing disorders, pregnancy, gastroparesis, multiple previous abdominal surgeries, and situations in which patients cannot (or refuse to) undergo surgery.

Although patients with functional gastric outlet obstruction were typically excluded from trials of VCE, Hollerbach et al⁵⁰ reported the successful endoscopic placement of a capsule though the pylorus in two patients with obscure GI bleeding and functional gastric outlet obstruction.

VCE is relatively contraindicated in patients with implanted pacemakers or defibrillators. The initial concern was that the signals from the VCE capsule might interfere with the pacemaker or defibrillator; however, VCE has been safely used in patients with these devices.⁵¹

■ WHAT QUESTIONS REMAIN

To demonstrate that VCE improves patient outcomes, a large clinical trial with long-term follow-up is needed. Such a study may answer a few important questions, eg:

- Does the information gained from VCE lead to therapies that actually reduce or eliminate bleeding?
- Does VCE reduce the need for subsequent diagnostic and therapeutic procedures and hospitalizations in patients with obscure GI bleeding?
- In stable patients with obscure GI bleeding, should VCE be the first diagnostic study after normal EGD and colonoscopy examinations? In evaluating such patients, VCE may replace the more invasive diagnostic techniques, eg, enteroclysis, nuclear scans, and angiography.⁵² If the capsule shows a bleeding source in the proximal small intestine, then push enteroscopy with biopsy may be performed. However, if the capsule evaluation is normal in a stable patient, then push enteroscopy can be avoided (FIGURE 4).

■ TECHNICAL IMPROVEMENTS

VCE continues to improve as technology advances.

Tracking the capsule. An algorithm for

Cost of capsule endoscopy: about \$850

accurately tracking the location of the capsule in the GI tract has been developed and tested.^{47,53}

Predicting whether the capsule will get obstructed. Given Imaging Limited has developed a "Patency Capsule System" consisting of an ingestible, dissolvable capsule the same size as an M2A capsule that contains a small radiofrequency identification tag. A preliminary report⁵⁴ indicates that if the patency capsule is excreted naturally, then an M2A capsule would do the same in 100% of patients, even if small bowel follow-through suggests the presence of a stricture.


Conversely, if the patency capsule is not excreted, then the physician can find the approximate location of the obstruction using a hand-held sensor that detects the signals from the radiofrequency ID tag and can perform subsequent validation by fluoroscopy. Once obstructed, the patency capsule is designed to dissolve and pass naturally in 48 to 72 hours.

■ FUTURE PERSPECTIVES

The complete diagnostic potential of VCE is yet to be determined, though it appears that its diagnostic applications will be extended to a variety of small intestinal disorders.

Controlling the capsule. As the peristaltic propulsion of the capsule can vary considerably, experimental studies are now focusing on remote-control robotic propulsion.⁵⁵ Swain et al⁵⁶ have described the feasibility of using electrostimulation devices in combination with VCE. This would allow the capsule to move both backward and forward, as the examiner wishes.

Experimental uses of VCE in evaluating motility disorders^{57,58} and the response of the GI tract to a variety of stresses⁵⁹ have been described.

Wireless VCE is an exciting beginning of a new chapter in the field of GI endoscopy that may form the basis of remote-control endoscopic imaging of the entire GI tract. 

■ REFERENCES

1. American College of Gastroenterology (ACG). The burden of gastrointestinal disease report. 2001 <http://www.gastro.org/phys-sci/burden.html>.
2. American Gastrointestinal Association. Technical review on the evaluation and management of occult and obscure gastrointestinal bleeding. *Gastroenterology* 2000; 118:201–221.
3. Thompson JN, Salem RR, Hemingway AP, et al. Specialist investigation of obscure gastrointestinal bleeding. *Gut* 1987; 28:47–51.
4. Szold A, Katz L, Lewis B. Surgical approach to occult gastrointestinal bleeding. *Am J Surg* 1992; 163:90–93.
5. Goldfarb NI, Phillips A, Conn M, Lewis BS, Nash DB. Economic and health outcome of capsule endoscopy: opportunities for improved management of the diagnostic process for obscure gastrointestinal bleeding. *Dis Manage* 2002; 5:123–135.
6. Lewis BS. Ileoscopy should be the part of standard colonoscopy: a comparison of radiographic and endoscopic evaluation of the ileum. *J Clin Gastroenterol* 2000; 31:103–104.
7. Bashir RM, Al-Kawas FH. Rare causes of small intestinal bleeding. *Gastrointest Endosc Clin North Am* 1996; 6:709–738.
8. Foutch PG. Angiodysplasia of the gastrointestinal tract. *Am J Gastroenterol* 1993; 88:807–818.
9. Maglinte DD, Kelvin FM, O'Connor K, Lappas JC, Chernish SM. Current status of small bowel radiography. *Abdom Imaging* 1996; 21:245–246.
10. Foutch P, Sawyer R. Push enteroscopy for diagnosis of gastrointestinal bleeding of obscure origin. *Gastrointest Endosc* 1990; 36:337–341.
11. Pennazio M, Arrigoni A, Risio M, Spandre M, Rossini FP. Clinical evaluation of push enteroscopy. *Endoscopy* 1995; 27:164–170.
12. Lewis BS. The history of enteroscopy. *Gastrointest Endosc Clin North Am* 1999; 9:1–11.
13. Seensalu R. The sonde exam. *Gastrointest Endosc Clin North Am* 1999; 9:37–59.
14. Lewis B, Waize JD. Chronic gastrointestinal bleeding of obscure origin. *Gastroenterology* 1988; 94:1117–1120.
15. Gostout CJ, Schroeder KW, Burton D. Small bowel enteroscopy. *Gastrointest Endosc* 1991; 37:5–8.
16. Zaman A, Sheppard B, Katon RN. Total peroral intraoperative enteroscopy for obscure GI bleeding using a dedicated push enteroscope: diagnostic yield and patient outcome. *Gastrointest Endosc* 1999; 50:506–510.
17. Lewis BS, Wenger JS, Wayne JD. Small bowel enteroscopy and intraoperative enteroscopy for obscure gastrointestinal bleeding. *Am J Gastroenterol* 1991; 86:171–174.
18. Iddan G, Meron G, Glukhovskiy A, Swain P. Wireless capsule endoscopy. *Nature* 2000; 405:417.
19. Appleyard M, Fireman ZVI, Glukhovskiy A, et al. A randomized trial comparing wireless capsule endoscopy with push enteroscopy for the detection of small-bowel lesions. *Gastroenterology* 2000; 119:1431–1438.
20. Appleyard M, Glukhovskiy A, Swain P. Wireless capsule diagnostic endoscopy for recurrent small bowel bleeding. *N Engl J Med* 2001; 344:232–233.
21. Scapa E, Jacob H, Lewkowicz S, et al. Initial experience of wireless-capsule endoscopy for evaluating occult gastrointestinal bleeding and suspected small bowel pathology. *Am J Gastroenterol* 2002; 97:2776–2779.
22. Lewis BS. Capsule endoscopy in clinical practice [abstract]. *Gastrointest Endosc* 2002; 55:AB125.
23. Pennazio M, Santucci R, Rondonotti E, et al. Wireless capsule endoscopy in patients with obscure gastrointestinal bleeding: results of the Italian multicenter experience [abstract]. *Gastrointest Endosc* 2002; 55:AB87.
24. Janowski D, Toth L, Wolff R, Mitty R, Lopez M, Cave DR. Video capsule endoscopy: early observations on its role in the diagnosis and management of obscure gastrointestinal bleeding [abstract]. *Gastrointest Endosc* 2002; 55:AB128.
25. Lo SK, Fisher HA, Tabibzadeh S, Papadakis KA, Dea S. Evaluation of bleeding of undetermined origin by wireless endoscopy [abstract]. *Gastrointest Endosc* 2002; 55:AB129.



26. Chutkan RK, Balba NH, Adams TL, Johnson M. Video capsule endoscopy in the evaluation of obscure gastrointestinal bleeding [abstract]. *Gastrointest Endosc* 2002; 55:AB133.
27. Mascarenhas-Saraiva MN, Lopes L. Wireless-capsule endoscopy in obscure gastrointestinal bleeding. Worthwhile? [abstract]. *Gastrointest Endosc* 2002; 55:AB137.
28. Myolnaki M, Ravens AF, Paul S. Clinical results of wireless capsule endoscopy [abstract]. *Gastrointest Endosc* 2002; 55:AB146.
29. Hahne M, Schilling D, Hartmann D, Adamek HE, Riemann JF. Wireless capsule endoscopy: a new dimension in small bowel diagnostics [abstract]. *Gastrointest Endosc* 2002; 55:AB147.
30. Lewis BS, Swain P. Capsule endoscopy in the evaluation of the patients with suspected small intestinal bleeding: results of a pilot study. *Gastrointest Endosc* 2002; 56:349–353.
31. Ell C, Remke S, May A, et al. The first prospective controlled trial comparing wireless capsule endoscopy with push enteroscopy in chronic gastrointestinal bleeding. *Endoscopy* 2002; 34:685–689.
32. Delvaux M, Saurin J-C, Gaudin JL, et al. Comparison of wireless endoscopic capsule and push-enteroscopy in patients with obscure occult/overt digestive bleeding: results of a prospective, blinded, multicenter trial [abstract]. *Gastrointest Endosc* 2002; 55:AB88.
33. Van Gossum A, Francois E, Schmit A, Deviere J. A prospective comparative study between push enteroscopy and wireless video capsule in patients with obscure digestive bleeding [abstract]. *Gastrointest Endosc* 2002; 55:AB88.
34. Lim RM, O'Loughlin CJ, Barkin JS. Comparison of wireless capsule endoscopy (M2A) with push enteroscopy in the evaluation of obscure gastrointestinal bleeding [abstract]. *Am J Gastroenterol* 2002; 97:S83.
35. Beejay UA, Haber GB, Rasul I, et al. A prospective trial comparing the diagnostic utility and reproducibility of Given diagnostic imaging system to conventional enteroscopy in the evaluation of chronic obscure gastrointestinal bleeding [abstract]. *Am J Gastroenterol* 2002; 97:S299.
36. Demedts I, Gevers AM, Hiele M, et al. Wireless capsule eneteroscopy is superior to push enteroscopy for identification of small intestinal source of obscure gastrointestinal bleeding [abstract]. *Gastrointest Endosc* 2002; 55:AB146.
37. Costamagna G, Shah SK, Riccioni ME, et al. A prospective trial comparing small bowel radiographs and video capsule endoscopy for suspected small bowel disease. *Gastroenterology* 2002; 123:999–1005.
38. Liangpunsakul S, Chadawalada V, Maglinte D, Lappas J, Rex DK. Wireless capsule endoscopy detects small bowel ulcers in patients with state of the art normal enteroclysis [abstract]. *Am J Gastroenterol* 2002; 97:S80.
39. Leighton JA, Sharma VK, Hara AK, Fleischer DE. Video capsule endoscopy (CE) compared to small bowel follow through (SBFT) and abdominopelvic CT scan (CT) for detecting lesions in the small intestine (SI) [abstract]. *Am J Gastroenterol* 2002; 97:S80.
40. Fireman Z, Mahanjan E, Broide E, et al. Diagnosing small bowel Crohn's disease with wireless capsule endoscopy. *Gut* 2003; 52:390–392.
41. Katz DZ, Lewis BS. Capsule endoscopy in known or suspected Crohn's disease: the perspective of the referring physician and the patient [abstract]. *Am J Gastroenterol* 2002; 97:S300.
42. De Franchis R, Rondonotti E, Abbiati C, et al. Use of the GIVEN video capsule system in small bowel transplanted patients [abstract]. *Gastrointest Endosc* 2002; 55:AB129.
43. Stiffler HL. Capsule endoscopy: a case study of an 11-year-old girl. *Gastroenterol Nurs* 2003; 26:38–40.
44. Myolnaki M, MacLean D, Fritscher-Ravens A, Swain CP. Wireless capsule endoscopic detection of Meckel's diverticulum after non-diagnostic surgery. *Endoscopy* 2002; 34:1018–1020.
45. Cave DR, Chen W, Pratt D. Detection of small intestinal varices by capsule endoscopy (CE) [abstract]. *Am J Gastroenterol* 2002; 97:S302.
46. Seitz U, Bohnacker S, Soehendra N. A simple method to determine the location of the capsule and thus whether prokinetic drugs are needed during video capsule endoscopy. *Endoscopy* 2002; 34:1027.
47. Levinthal GN, Burke CA, Santisi JM. The accuracy of an endoscopy nurse in interpreting capsule endoscopy. *Am J Gastroenterol* 2003; 98:2669–2671.
48. Smith MS, Mergener K, Schembr DB, et al. Complications and problems with capsule endoscopy [abstract]. *Am J Gastroenterol* 2002; 97:S301.
49. Van Gossum A, Deviere J. Wireless endoscope: methodological features [abstract]. *Gastrointest Endosc* 2002; 55:AB135.
50. Hollerbach S, Kraus K, Willert J, et al. Endoscopically assisted video capsule endoscopy of the small bowel in patients with functional outlet obstruction. *Endoscopy* 2003; 35:226–229.
51. Lewis BS. Complications and contraindications in capsule endoscopy [abstract]. *Gastroenterology* 2002; 122:A330.
52. Fleischer DE. Capsule endoscopy: the voyage is fantastic—will it change what we do? *Gastrointestinal Endosc* 2002; 56:452–456.
53. Jacob H, Levy D, Schreiber R, Glukhovsky A, Fischer D. Localization of the Given M2A ingestible capsule in the given diagnostic imaging system [abstract]. *Gastrointest Endosc* 2002; 55:AB135.
54. Information obtained from www.given.imaging.com.
55. Mosse CA, Mills TN, Appleyard MN, et al. Electrical stimulation for propelling endoscopes. *Gastrointest Endosc* 2001; 54:79–83.
56. Swain CP, Mosse CA, Burke P, et al. Remote propulsion of wireless capsule endoscopes [abstract]. *Gastrointest Endosc* 2002; 55:AB88.
57. Korman LY, Weinstein ML, Washington DC. Wireless capsule endoscopy: video analysis of gastrointestinal motility and transit using given M2A imaging system [abstract]. *Gastrointest Endosc* 2002; 55:AB133.
58. Fisher HA, Lo SK, Deleon VP. Gastrointestinal transit of wireless endoscopic capsule [abstract]. *Gastrointest Endosc* 2002; 55:AB134.
59. Fritscher-Ravens A, Mylonaki M, Swain CP. The effect of stress on gastrointestinal physiology using wireless capsule endoscope observation [abstract]. *Gastrointest Endosc* 2002; 55:AB131.

ADDRESS: John Vargo, MD, Department of Gastroenterology, A30, The Cleveland Clinic Foundation, 9500 Euclid Avenue, Cleveland, OH 44195.