

**VESNA D. GAROVIC, MD**

Division of Nephrology and Hypertension,  
Department of Medicine, Mayo Clinic College  
of Medicine, Rochester, MN

**GARVAN C. KANE, MB, BCh**

Division of Cardiovascular Diseases, Department  
of Medicine, Mayo Clinic College of Medicine,  
Rochester, MN

**GARY L. SCHWARTZ, MD**

Division of Nephrology and Hypertension,  
Department of Medicine, Mayo Clinic College of  
Medicine, Rochester, MN

# Renovascular hypertension: Balancing the controversies in diagnosis and treatment

## ■ ABSTRACT

There is considerable controversy about how to test for renovascular hypertension and, with the development of percutaneous transluminal renal angioplasty (PTRA) and stenting, how to treat it. Which noninvasive diagnostic test should be considered, and when is renal angiography called for? Which patients will benefit from conservative medical therapy, and when is PTRA appropriate?

## ■ KEY POINTS

Duplex renal artery sonography is becoming more popular as a noninvasive screening test, especially in tertiary care institutions. Magnetic resonance angiography and computed tomographic angiography are superior to ultrasonography but more expensive.

The leading indication for renal angioplasty and stenting is now to preserve renal function, with the expectation that revascularization may prevent total occlusion and renal atrophy.

Intervening on renal arteries is not risk-free, and a certain number of patients will experience subsequent deterioration of renal function, potentially leading to end-stage renal disease.

On the other hand, delaying intervention may result in progression of stenosis, kidney atrophy, and cardiovascular complications related to inadequately controlled hypertension.

**R**ENOVASCULAR HYPERTENSION, the most common form of secondary hypertension, seems simple in theory but is fairly complicated in clinical practice.

In theory, if the renal arteries are blocked, the blood pressure will go up and renal function will go down. Unblock the arteries and blood pressure will come down and renal function will be restored.

In practice, however, the clinician must make many highly individualized decisions, for example:

- Should this patient undergo testing for renal artery stenosis and renovascular hypertension? With which test?
- How valid are the results of the test in this patient? If the renal artery or arteries are indeed blocked, is the stenosis causing the high blood pressure, or do the two conditions merely coexist?
- Should this patient undergo a revascularization procedure, and if so, which one? But what of the risk of further renal damage from aggressive treatment?
- Would medical therapy give comparable results with less risk? Or would conservative therapy run the risk of more long-term renal damage?

Some of these decisions, especially whether to treat medically or more aggressively with revascularization, have sparked heated debate among nephrologists and interventionists.

The goal of this paper is to provide a balanced update of current diagnostic and therapeutic options in this field.

TABLE 1

### Causes of renovascular hypertension

Atherosclerosis
Fibromuscular dysplasia
Intimal (1–2%)
Periarterial (1–2%)
Medial (96%+)39
Renal artery aneurysm
Systemic vasculitis
Arteriovenous fistula
Subcapsular intrarenal hematoma (Page kidney)52
Renin-secreting renal tumors
Extrinsic compression of either kidney or renal artery due to tumors or metastases
Aortic coarctation

#### ■ STENOSIS IS REQUIRED BUT NOT SUFFICIENT

To diagnose renovascular hypertension, renal artery stenosis is required but is not sufficient.

When stenosis is severe enough, ie, when it causes at least a 75% reduction in diameter, renal hypoperfusion and functional changes in the affected kidney may ensue, leading to activation of the renin-angiotensin-aldosterone system, which plays a central role in the development of renovascular hypertension.

When the stenosis is due to atherosclerosis, however, it is sometimes difficult or impossible to establish whether the stenosis is actually causing the hypertension, or whether the hypertension is preexisting essential hypertension. Under these circumstances, it may be difficult to predict whether a revascularization procedure will lower the blood pressure.

#### ■ MECHANISM MAY DIFFER IN UNILATERAL VS BILATERAL STENOSIS

The underlying mechanism of renovascular hypertension may be different in unilateral vs bilateral disease (FIGURE 1), as suggested by landmark animal experiments performed by Goldblatt et al in the 1930s.<sup>1</sup>

In critical unilateral renal artery stenosis, the central mechanism is elevated plasma

renin activity arising from the affected kidney. The renin cleaves angiotensinogen, releasing angiotensin I, which is cleaved by angiotensin-converting enzyme (ACE) to release angiotensin II, which causes vasoconstriction. Angiotensin II also stimulates the adrenal cortex to secrete aldosterone, which leads to sodium and volume retention. Hence, this mechanism has been called “angiotensin-dependent hypertension.”<sup>2</sup> The contralateral kidney responds with a pressure diuresis that reduces the expanded plasma volume but is usually insufficient to prevent hypertension.

In bilateral renal artery stenosis, increased levels of angiotensin II lead to volume and sodium retention and, in the absence of a healthy kidney, volume-dependent hypertension. Volume expansion, in turn, suppresses renin secretion in the more chronic phases of hypertension. This volume-dependent hypertension can convert back to angiotensin II dependency by sodium and volume depletion. For example, excessive diuresis can activate the renin-angiotensin system, which inhibits further sodium excretion, leading to resistance to diuretic therapy, commonly seen in these patients.

#### ■ TWO MAIN CAUSES OF STENOSIS

Although renovascular hypertension can be caused by any of a number of diseases that affect renal blood flow (TABLE 1), atherosclerosis accounts for nearly 90% of cases, and fibromuscular dysplasia accounts for nearly 10%.<sup>3</sup>

##### Atherosclerosis

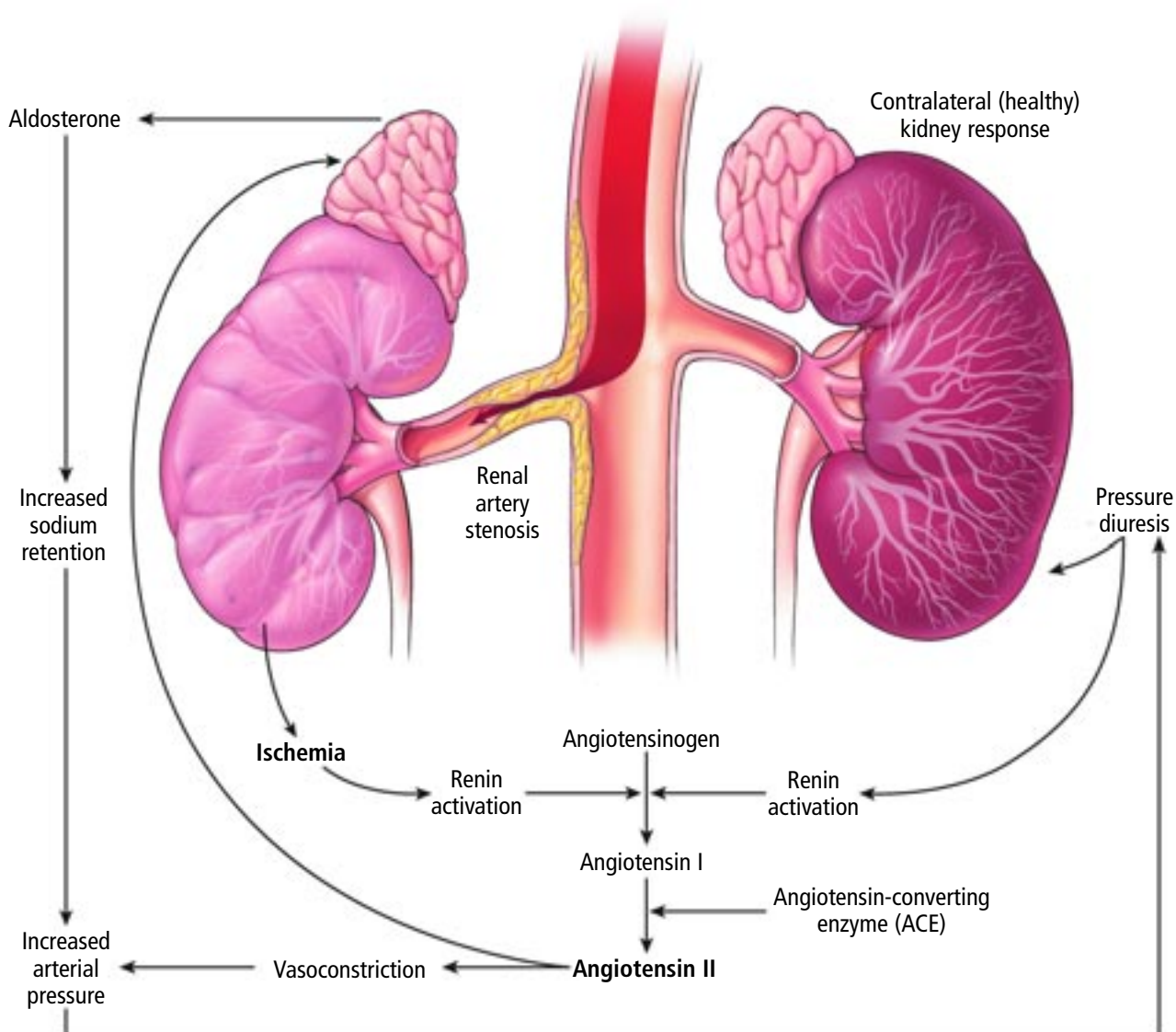
Atherosclerotic renal artery stenosis is increasingly recognized as one of the manifestations of generalized atherosclerosis associated with advanced age, and is commonly diagnosed incidentally during coronary angiography in a “drive-by” renal angiogram. It may affect up to 30% of patients with coronary artery disease<sup>4</sup> and nearly 50% of those with significant peripheral vascular disease.<sup>5</sup>

Atherosclerotic renal artery stenosis tends to involve the proximal segment of the artery and, invariably, its origin (FIGURE 2). Atherosclerotic plaques may either form within the renal artery or, alternatively, originate in the aorta and extend into the renal arteries.<sup>6</sup>

Resistance to diuretics is common in bilateral renal artery stenosis



## ■ Mechanisms of renovascular hypertension



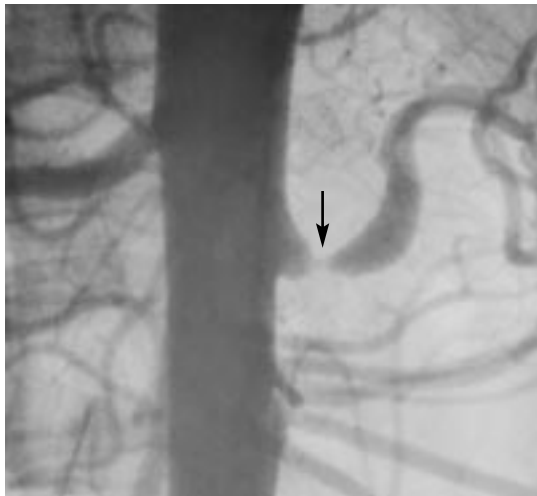**In unilateral renal artery stenosis**, the affected kidney secretes renin, activating the cascade that leads to aldosterone secretion by the adrenal cortex. Aldosterone causes salt and water retention. The healthy kidney responds with pressure diuresis that further stimulates renin secretion, leading to a vicious circle of **angiotensin-dependent hypertension**.

**In bilateral renal artery stenosis**, the mechanism is the same at the outset. In the absence of a healthy kidney that can perform pressure diuresis, volume expansion leads to renin suppression, hence **volume-dependent hypertension**. The model of volume-dependent hypertension can be converted back to angiotensin-dependency by volume depletion. For example, excessive diuretic therapy may reduce volume but restore renin secretion, leading to diuretic-resistant hypertension.

CCF  
Medical Illustrator: Joseph Pangrace ©2005

**FIGURE 1**

### Renal artery stenosis: Atherosclerosis



**FIGURE 2.** Arteriogram with contrast showing atherosclerotic renal artery stenosis of the proximal left renal artery. Atherosclerosis accounts for nearly 90% of cases of renal artery stenosis.

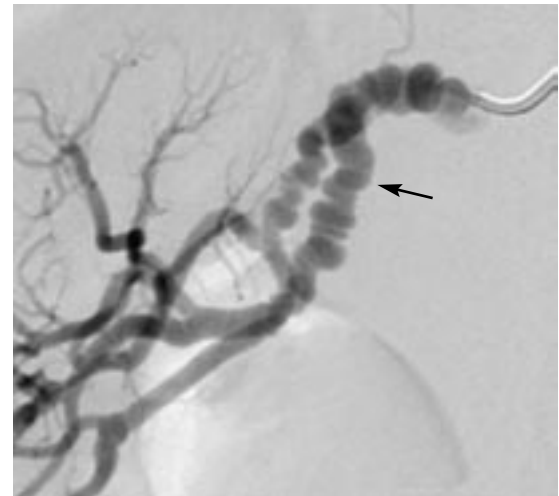Typically, patients with atherosclerotic renal artery disease are older, with a history of smoking, hyperlipidemia, diabetes mellitus, and obesity, and gradually develop renovascular disease in the setting of preexisting essential hypertension. Therefore, even when renal artery stenosis of 75% or greater is present, renal revascularization may fail to achieve clinical benefits. In some patients, successful revascularization may allow control of resistant hypertension, sometimes with a decrease in the number of antihypertensive medications, and it may allow for safer use of ACE inhibitors in patients who may benefit from the cardiorenal protective effects of these drugs, such as those with congestive heart failure or proteinuric renal disease.

### Fibromuscular dysplasia

Medial fibroplasia, the most common form of fibromuscular dysplasia, may significantly compromise renal blood flow, resulting in systemic arterial hypertension. Classically, patients with fibromuscular dysplasia are young (< 30 years) and female, often with a history of smoking.<sup>7</sup>

The lesions are composed of several intravascular webs that have a typical “string

### Fibromuscular dysplasia



**FIGURE 3.** Arteriogram with contrast showing fibromuscular dysplasia of the middle right renal artery.

of beads” appearance on angiography and, in contrast to atherosclerotic lesions, predominantly involve the mid-to-distal segment of the artery (FIGURE 3).

### ■ ISCHEMIC NEPHROPATHY

Like atherosclerosis in other vascular beds, atherosclerotic disease of the renal arteries often progresses and can eventually totally occlude the artery. When the entire renal mass is affected (ie, in bilateral stenosis or stenosis to a solitary kidney), progression of renal artery stenosis may cause deterioration of renal function, often called “ischemic nephropathy.”

Up to 14% of patients on hemodialysis have renal artery stenosis,<sup>8,9</sup> underscoring the potential of renovascular disease to cause renal failure.

Retrospective studies in the 1970s and 1980s reported progression of lesions in up to 50% of patients, with total occlusion affecting 15% to 16% of renal arteries.<sup>10,11</sup> Recent prospective trials have reported lower rates of both progression (35%) and total occlusion (3%) over a 3-year period.<sup>12</sup> The difference in reported rates may merely be due to different study designs or, alternatively, to a change in the natural course of atherosclerotic disease

**The classic patient with fibromuscular dysplasia is a woman younger than 30 years who smokes**



due to aggressive treatment of hyperlipidemia with statins and use of medications that disrupt the renin-angiotensin-aldosterone axis, eg, ACE inhibitors and angiotensin II receptor blockers (ARBs).<sup>13</sup> Based on available data, it is safe to conclude that progression does not occur in all patients, but a subset of patients is clearly at high risk.

However, renal insufficiency appears not to be simply a function of ischemia directly due to renal artery occlusion, as less than 10% of normal renal blood flow is required to meet the metabolic needs of renal tissue.<sup>14</sup> Renal hypoperfusion and stimulation of the renin-angiotensin-aldosterone system are associated with oxidative stress and activation of hormonal and cytokine-mediated inflammatory pathways that may play important roles, leading to tissue injury and parenchymal fibrosis. Thus, some experts prefer the term “azotemic renovascular disease,” which is used interchangeably with “ischemic nephropathy” in the current literature.<sup>15</sup>

**■ DIAGNOSIS: NONINVASIVE TESTING VS ARTERIOGRAPHY**

Several clinical features and distinct clinical presentations, from unexplained renal insufficiency to resistant hypertension, should prompt the physician to evaluate for renal artery stenosis. For some of these presentations, a consensus exists among different specialties that revascularization should generally be considered if renal artery stenosis is found (TABLE 2).

**Arteriography** with contrast remains the gold standard to determine the degree and location of renal artery stenosis. However, it provides no information about the functional role and thus the clinical significance of the lesion. Moreover, this procedure can cause deterioration of renal function due to contrast nephropathy, atheroembolic disease, or both; a few procedure-related deaths have been reported. Consequently, it is generally reserved to confirm the diagnosis, often as a prelude to percutaneous intervention, while the initial workup usually involves noninvasive testing.

**Noninvasive testing** aims to evaluate either the functional role of the lesion or the

**TABLE 2**

**Clinical features of renovascular hypertension**

**Suggestive features**

- Unexplained renal insufficiency
- Abdominal systolic-diastolic bruit
- Unprovoked hypokalemia<sup>53</sup>
- Onset of hypertension at age less than 30 years for fibromuscular dysplasia or greater than 55 years for atherosclerotic renal artery stenosis
- History of flank trauma
- Generalized atherosclerosis
- Smoking
- Difference in kidney size of  $\geq 1$  cm
- Absence of family history of hypertension

**Indications for revascularization if stenosis is present**

- Accelerated hypertension
- Resistant hypertension
- Hypertensive urgency
- Hypertensive emergency
  - Myocardial ischemia
  - Aortic dissection
  - Hypertensive retinopathy
  - Central nervous system abnormalities
  - Acute renal insufficiency
- Worsening renal function during antihypertensive treatment, particularly with angiotensin-converting enzyme inhibitors
- “Flash” pulmonary edema

location and magnitude of anatomical obstruction (TABLE 3). The reported diagnostic accuracy of these commonly used screening tests varies widely. Although many factors are responsible, publication bias and differences in the use of these tests in the setting of strict research protocols vs the “real world” of clinical practice probably play important roles.

Therefore, we cannot recommend any single, ideal noninvasive test. Rather, the choice of an initial screening test should incorporate the availability and expertise at any given institution. In addition, patient-related factors such as body size, concomitant medication use, and underlying renal function should be considered.



TABLE 3

### Tests for evaluating the renal arteries

#### Plasma renin activity

**Rationale:** Central role of renin-angiotensin-aldosterone in the mechanism of renovascular hypertension

**Limitations:** Affected by blood pressure medications, sodium intake, volume status, differences in unilateral vs bilateral disease; relatively low sensitivity and specificity (57% and 66%, respectively)<sup>54</sup>

**Advantages:** Inexpensive, noninvasive

#### Renal vein renin ratio

**Rationale:** Increase in renin release of  $\geq 1.5$  times from the affected kidney compared with suppressed renin levels from the normal kidney

**Limitations:** Invasive, performed mainly in tertiary centers, lacks sensitivity and specificity, influenced by drugs and volume status

**Advantages:** Lateralization highly predictive of beneficial outcomes; may favor nephrectomy for "pressor" kidney<sup>55</sup>

#### Captopril renography

**Rationale:** Captopril releases angiotensin II-induced constriction of the efferent arteriole and causes delayed excretion of the isotope, such as <sup>99m</sup>Tc-mercaptoacetyltriglycine (MAG3)

**Limitations:** Lack of accuracy with serum creatinine  $> 2$  mg/dL and bilateral disease; patients should be off diuretics and ACE inhibitors 1–2 weeks before testing

**Advantages:** Information regarding kidney size and split function, ie, contribution of each kidney to overall glomerular filtration rate; may predict response to revascularization

#### Duplex renal artery sonography

**Rationale:** Acceleration of blood flow through the area of narrowing causes an increase in peak systolic velocity of  $\geq 180$  mm/s and an increase in renal-aortic peak systolic velocity ratio of  $\geq 3.5$

**Limitations:** Highly operator-dependent; limited by obesity, bowel gas interference

**Advantages:** Acceptable price; useful in serial measurements; additional information regarding kidney size, presence of hydronephrosis and resistive index ( $1 - [\text{end-diastolic velocity} / \text{maximal systolic velocity}] \times 100$ )

#### Magnetic resonance angiography

**Techniques:** Time-of-flight is outdated; phase-contrast measures blood flow within the renal arteries

**Limitations:** High cost; signal corruption due to metallic stents

**Advantages:** Low, if any, nephrotoxic potential

#### Computed tomographic angiography

**Technique:** Helical and multiple head scanners and intravenous contrast

**Limitations:** Limited use in renal insufficiency due to high contrast requirement of  $\geq 150$  mL

**Advantages:** Improved visualization of branch vessels

Renal artery sonography is becoming more popular as a screening test

That said, duplex renal artery sonography is becoming more popular as a screening test,<sup>16</sup> especially in tertiary care institutions with large patient referral bases and highly experienced ultrasonographers. In addition, magnetic resonance angiography and computed tomographic angiography have improved, become widely available, and are often considered either for initial screening or for further testing in patients with a high degree of clinical suspicion for renal artery stenosis but

previously negative duplex tests.

As a result, physicians are likely to encounter more patients in whom every attempt has been made to establish or exclude the diagnosis of renal artery stenosis in a noninvasive manner and who have undergone two or more types of noninvasive tests, sometimes with conflicting results. In current practice, the decision to pursue invasive arteriography is frequently limited to patients with positive preliminary noninvasive studies, and

**TABLE 4****Accuracy of tests of the renal arteries**

TEST	SENSITIVITY (%)	SPECIFICITY (%)	PRETEST PROBABILITY FOR RENAL ARTERY STENOSIS			
			20%		50%	
			POSITIVE PREDICTIVE VALUE (%)	NEGATIVE PREDICTIVE VALUE (%)	POSITIVE PREDICTIVE VALUE (%)	NEGATIVE PREDICTIVE VALUE (%)
Captopril renography <sup>19</sup>	74	59	31	90	64	69
Duplex sonography <sup>17*</sup>	76	75	43	93	75	76
Magnetic resonance angiography <sup>18†</sup>	78	88	64	94	87	80
Computed tomographic angiography <sup>18†</sup>	77	88	76	94	93	80

\*Values chosen are intermediate between captopril renal scanning<sup>19</sup> and average of values obtained for magnetic resonance angiography and computed tomographic angiography<sup>18</sup> and based on the summary receiver-operator curves from Vasbinder et al<sup>17</sup>

†Values reported for atherosclerotic renal artery stenosis

thus is heavily dependent on test reliability and accuracy.

But how reliable are these tests? We have calculated the positive predictive values (the probability of the disease being present, given a positive test result), and a negative predictive value (the probability of the disease being absent, given a negative test result) for several noninvasive tests commonly used for screening (TABLE 4). Estimates of sensitivity (the number of true-positive test results divided by the total number of patients with renal artery stenosis) and specificity (the number of true-negative test results divided by the total number of patients without renal artery stenosis) were derived from seminal studies,<sup>17–19</sup> which, in our opinion appropriately reflect clinical practice conditions.

As with other diagnostic tests, the value of noninvasive testing for renal artery stenosis depends upon the pretest probability of the disease in a given patient. For patients at moderate risk, ie, with a 20% pretest probability (a figure often reported in referral series<sup>20</sup>), a positive result on a screening test markedly increases the likelihood that the disease is present, and a negative result markedly decreases it. However, these screening tests have less value when the pretest probability for renal artery disease is high.

For example, as shown in TABLE 4, if the pretest probability is 50%, a negative screening test should be interpreted with extreme caution because the likelihood for renal artery stenosis remains quite high (20%–31%). This argues for use of invasive arteriography either initially or despite negative screening tests in patients who present with several clinical features suggestive of renal artery stenosis and thus a high pretest probability for the disease (TABLE 2).

**MEDICAL THERAPY****ACE inhibitors are preferred**

ACE inhibitors are widely accepted as being superior to other antihypertensive drugs in controlling renovascular hypertension.<sup>21,22</sup> Furthermore, ACE inhibitors have been associated with improved survival of these patients, many of whom carry a heavy burden of generalized atherosclerotic disease.<sup>23</sup>

The major concern about ACE inhibitors is their potential to precipitate acute renal failure in patients with renovascular hypertension.<sup>24</sup> Optimal clinical management calls for close follow-up of kidney function and potassium levels when starting an ACE inhibitor in patients with known renal artery stenosis.

**The value of testing depends on the pretest probability of disease**

Risk factors for ACE inhibitor-induced deterioration of renal function include pre-existing renal insufficiency, congestive heart failure, and concurrent treatment with diuretics, vasodilators, or nonsteroidal anti-inflammatory drugs (NSAIDs).<sup>25</sup> Simple measures such as using diuretics judiciously, withholding NSAIDs, and managing volume during acute illnesses associated with volume depletion (ie, diarrhea, vomiting) may prevent acute reductions in renal function during ACE inhibitor therapy.

At particularly high risk are patients with global renal ischemia due to either bilateral stenosis or stenosis to a solitary kidney; a rise in serum creatinine has been reported in one third of these patients treated with captopril.<sup>26</sup> However, serum creatinine concentrations returned to baseline levels within 7 days of captopril withdrawal. Most experts agree that with long-term therapy, a rise in creatinine during the first 2 months by 30% over baseline and elevation of potassium up to 5.5 mmol/L are acceptable and do not require stopping ACE inhibitors.<sup>27,28</sup> The decrease in glomerular filtration rate is usually reversible and readily responds to stopping the offending drug,<sup>29</sup> with only a few reports of ACE inhibitor-induced irreversible renal insufficiency in cases of renal artery thrombosis.<sup>30</sup>

Not enough physicians appreciate that a decline in renal function with treatment in patients with renovascular disease is not specific to ACE inhibitors and ARBs; any antihypertensive drug that effectively reduces systemic blood pressure has the potential to decrease renal perfusion pressures beyond a stenotic lesion.<sup>31</sup> Therefore, irrespective of their blood pressure regimens, patients with known renal artery stenosis should be closely monitored in terms of their renal size and function.

If more severe renal impairment arises during long-term therapy, reflected in a rise in creatinine of more than 30% over baseline and a serum potassium concentration of 5.6 mmol/L or higher, the ACE inhibitor should be stopped and the patient should undergo evaluation for revascularization.

Of note: although revascularization may improve blood pressure control and patients may need to take fewer antihypertensive drugs

afterward, most patients still require multidrug regimens.

### Consider an ARB if an ACE inhibitor causes cough or hyperkalemia

Similar to ACE inhibitors, ARBs inhibit the renin-angiotensin-aldosterone system and have demonstrated comparable antihypertensive effects. Use of ARBs may be associated with a smaller rise in serum potassium in patients with mild chronic renal failure.<sup>32</sup> One can consider substituting an ARB if a patient develops hyperkalemia or cough during treatment with an ACE inhibitor.

### Treat other risk factors

Atherosclerotic disease of the renal artery should prompt aggressive treatment of other risk factors such as hyperlipidemia and smoking. Aggressive lipid reduction with HMG-CoA reductase inhibitors (statins) is indicated and may lead to regression of the systemic atherosclerotic burden, including that of the renal arteries,<sup>33</sup> regardless of whether intervention is a consideration. Once blood pressure is controlled, patients should be started on low-dose aspirin therapy.

### ■ RENAL ANGIOPLASTY WITH STENTING FOR ATHEROSCLEROSIS

Uncontrolled, retrospective studies of percutaneous transluminal renal angioplasty (PTRA) have provided exciting evidence that intervention can improve blood pressure control and preserve renal function in patients with atherosclerotic renal artery stenosis.<sup>34,35</sup>

Renal artery stenting became increasingly popular in the 1990s for treating atherosclerotic disease after evidence emerged that PTRA without stenting resulted in worse outcomes in atherosclerotic disease than in fibromuscular dysplasia. Renal artery stents improved the rates of initial technical success and long-term vessel patency, as reported by Isles et al<sup>36</sup> in a critical review of 10 descriptive reports published between 1991 and 1997. Immediate technical success rates were 96% to 100%, with restenosis in 16% of the arteries at follow-up of 6 to 12 months.

**Stop the ACE inhibitor if creatinine increases by > 30% or potassium reaches 5.6 mmol/L**





### May improve blood pressure

Long-term improvement in blood pressure control can be expected in up to 50% of patients with atherosclerotic renal artery disease who undergo revascularization for inadequate hypertension control.<sup>37</sup> However, cure is relatively rare, achieved in no more than 9% to 16% of these patients.<sup>36</sup> ACE inhibitors and ARBs have markedly improved blood pressure control in these patients. In fact, wide use of these agents has resulted in adequate blood pressure control in more than 90% of patients with renovascular hypertension, compared with 46% before their use.<sup>21,22</sup> Consequently, the leading indication for intervening is now to preserve renal function, with the expectation that revascularization may prevent total occlusion and renal atrophy.

### May preserve renal function, but results are mixed

Another common presentation of atherosclerotic renal artery stenosis is unexplained renal insufficiency associated with an unremarkable urinary sediment and proteinuria of less than 1 gram per 24 hours in elderly patients with atherosclerotic disease in other vascular beds. For renal insufficiency to develop in the setting of and solely due to renal artery stenosis, both renal arteries need to be involved. Under these circumstances, attempts at revascularization are aimed at improving or preserving renal function. With unilateral renal artery stenosis, kidney function is usually normal unless another disease process is present.

Patients with atherosclerotic renal artery stenosis are at a particularly high risk for small-vessel disease of the kidneys, ie, nephrosclerosis, as both diseases share a common risk factor profile consisting of diabetes, hyperlipidemia, and smoking. If advanced nephrosclerosis is present, revascularization of the affected renal artery will not improve blood pressure control or renal function because the small-vessel changes are irreversible.

Studies of renal outcomes after PTRAs have not been particularly promising. Subgroup analyses in several studies, irrespective of design, have reported measurable and clinically significant improvement in 25% to 30% of patients, no significant change in 45% to 50%, and a steady decline in renal function

in the remaining 20% to 25%.<sup>36,38</sup>

Patients least likely to benefit are those with decreased kidney size,<sup>39</sup> longer duration of renal insufficiency,<sup>40</sup> advanced renal insufficiency with serum creatinine levels above 3.0 mg/dL,<sup>41</sup> and a baseline renal resistive index of more than 80 (this index is a marker of renal small vessel disease, measured by ultrasonography).<sup>42</sup>

Moreover, some patients suffer a poor renal outcome after the procedure, with rapid deterioration in renal function leading to chronic dialysis and increased mortality rates. In addition, these outcomes are hard to predict beforehand.<sup>43,44</sup> Possible reasons for this rapid decline in renal function include reperfusion injury, contrast nephropathy, and atheroembolic disease. Recommended interventions to prevent contrast nephropathy have been recently reviewed.<sup>45</sup> The role of distal protection devices in preventing atheroembolic disease during renal endovascular procedures remains to be determined.

### ■ PTRAs FOR FIBROMUSCULAR DISEASE

Some experts advocate giving an ACE inhibitor for initial therapy for renovascular hypertension due to fibromuscular dysplasia and reserving balloon angioplasty without stenting for hypertension refractory to medical therapy. Another approach is early intervention with the goal of curing hypertension as an alternative to lifelong medical treatment, especially in younger patients.

However, the reported cure rates with PTRAs in the most recent case series do not exceed 50%.<sup>7</sup> Disappointing cure rates may be a reflection of changing demographics: older patients with co-existing atherosclerotic disease or essential hypertension or both are less likely to become normotensive, even after technically successful angioplasty for fibromuscular dysplasia.

Unlike atherosclerotic disease, hemodynamically significant fibromuscular dysplasia rarely leads to loss of renal function.<sup>46</sup> These patients are younger and consequently have a lower prevalence of atherosclerotic disease in other vascular beds and fewer comorbidities, such as diabetes and hyperlipidemia, that are known to potentiate microvascular injury.

**Needed:  
large  
randomized  
studies of  
medical  
therapy vs  
angioplasty for  
renovascular  
hypertension**

## THE HEATED DEBATE OVER MEDICAL TREATMENT VS REVASCULARIZATION

The optimal treatment for renal artery stenosis remains a topic of heated debate and divergent opinions between nephrologists on one side and interventional cardiologists, radiologists, and vascular surgeons on the other. Nephrologists, who ultimately take care of patients who suffer a significant loss of renal function after revascularization procedures, tend to support a more conservative approach. On the other hand, procedure-oriented specialists argue that advanced endovascular techniques have the potential to improve blood pressure control and preserve renal function. Differences in opinions are further amplified by a lack of prospective studies from which to draw.

So far, only three randomized trials have prospectively compared medical management vs PTR, and they reported that intervention offered little if any advantage over medical treatment in blood pressure control.<sup>47-49</sup>

These conclusions must be interpreted within the context of the inherent limitations of these trials. Only 4 of the total of 210 patients in these trials received stents, which is not in keeping with current practice of frequent use of stents in treating atherosclerotic lesions. With respect to renal function, these trials did not include a significant number of the type of patient who in theory has the most to gain from PTR, namely the patient with impaired renal function or with bilateral disease. Other limitations included small sample sizes, short follow-up, and, frequently cited, significant crossover from medical therapy to PTR because of refractory hypertension or progressive renovascular occlusive disease (27%–44%).

These data are frequently used to support the role of PTR in the management of renovascular hypertension that is refractory to medical therapy. Two meta-analyses of these trials independently reported that, compared with medical therapy, PTR was more effective in reducing blood pressure.<sup>50,51</sup>

## THE AUTHORS' PERSPECTIVE

Adequate blood pressure control with ACE inhibitor-based regimens has lessened the need for revascularization for uncontrolled hypertension in patients with renovascular hypertension. Medical management is a reasonable option, particularly for patients with atherosclerotic renal artery stenosis, who are typically poor surgical candidates due to advanced age or multiple comorbidities related to generalized atherosclerosis, or both.

Increasingly, revascularization procedures are being done to preserve renal function. PTR alone for fibromuscular disease and PTR with renal artery stenting for atherosclerotic renal artery stenosis are accepted alternatives to surgery, which is frequently associated with high perioperative risk, and, in current practice, usually limited to a subset of patients who require both renal and aortic reconstructions, and for those for whom endovascular procedures have failed.

Intervening on renal arteries is not risk-free, and a certain number of patients will experience subsequent deterioration of renal function, potentially leading to end-stage renal disease. The opposite can also be true: delaying intervention may result in progression of stenosis, kidney atrophy, and cardiovascular complications related to inadequately controlled hypertension.

The choice of optimal treatment is complicated further by the lack of prospective trials comparing current treatment options and evaluating long-term blood pressure and kidney function outcomes. Needed are prospective, randomized, and likely multicenter trials with adequate power to compare the effects of PTR, surgery, and medical management on blood pressure control and renal function. The National Institutes of Health recently approved a prospective, multicenter trial called Cardiovascular Outcomes in Renal Artery Lesions (CORAL), with anticipated completion in 2011.

Until the results of this and similar trials become available, the optimal form of therapy and timing of revascularization must remain a matter of carefully weighing the risks and benefits for each individual patient, while pursuing aggressive medical treatment of cardiovas-

**The optimal treatment for renal artery stenosis remains a topic of heated debate**

cular risk factors, including hypertension. The decision-making process should incorporate patient preference, options, and expertise that

are available in any given institution, and our current understanding of the natural course and progression of renal artery stenosis.

## REFERENCES

1. Goldblatt HL, Hanzal RF, Summerville WW. Studies on experimental hypertension. I. The production of persistent elevation of systolic blood pressure by means of renal ischemia. *J Exp Med* 1934; 59:347-378.
2. Brunner HR, Kirshman JD, Sealey JE, Laragh JH. Hypertension of renal origin: evidence for two different mechanisms. *Science* 1971; 174:1344-1346.
3. Safian RD, Textor SC. Renal-artery stenosis. *N Engl J Med* 2001; 344:431-442.
4. Harding MB, Smith LR, Himmelstein SI, et al. Renal artery stenosis: prevalence and associated risk factors in patients undergoing routine cardiac catheterization. *J Am Soc Nephrol* 1992; 2:1608-1616.
5. Olin JW, Melia M, Young JR, Graor RA, Risius B. Prevalence of atherosclerotic renal artery stenosis in patients with atherosclerosis elsewhere. *Am J Med* 1990; 88:46N-51N.
6. Cicuto KP, McLean GK, Oleaga JA, Freiman DB, Grossman RA, Ring EJ. Renal artery stenosis: anatomic classification for percutaneous transluminal angioplasty. *AJR Am J Roentgenol* 1981; 137:599-601.
7. Bonelli FS, McKusick MA, Textor SC, et al. Renal artery angioplasty: technical results and clinical outcome in 320 patients. *Mayo Clin Proc* 1995; 70:1041-1052.
8. Mailloux LU, Napolitano B, Bellucci AG, Vernace M, Wilkes BM, Mossey RT. Renal vascular disease causing end-stage renal disease, incidence, clinical correlates, and outcomes: a 20-year clinical experience. *Am J Kidney Dis* 1994; 24:622-629.
9. Greco BA, Breyer JA. The natural history of renal artery stenosis: who should be evaluated for suspected ischemic nephropathy? *Semin Nephrol* 1996; 16:2-11.
10. Schreiber MJ, Pohl MA, Novick AC. The natural history of atherosclerotic and fibrous renal artery disease. *Urol Clin North Am* 1984; 11:383-392.
11. Tollefson DF, Ernst CB. Natural history of atherosclerotic renal artery stenosis associated with aortic disease. *J Vasc Surg* 1991; 14:327-331.
12. Caps MT, Perissinotto C, Zierler RE, et al. Prospective study of atherosclerotic disease progression in the renal artery. *Circulation* 1998; 98:2866-2872.
13. Textor SC. Ischemic nephropathy: where are we now? *J Am Soc Nephrol* 2004; 15:1974-1982.
14. Lerman L, Textor SC. Pathophysiology of ischemic nephropathy. *Urol Clin North Am* 2001; 28:793-803.
15. Textor SC, Wilcox CS. Renal artery stenosis: a common, treatable cause of renal failure? *Annu Rev Med* 2001; 52:421-442.
16. Zucchelli PC. Hypertension and atherosclerotic renal artery stenosis: diagnostic approach. *J Am Soc Nephrol* 2002; 13(suppl 3):S184-S186.
17. Vasbinder GB, Nelemans PJ, Kessels AG, Kroon AA, de Leeuw PW, van Engelshoven JM. Diagnostic tests for renal artery stenosis in patients suspected of having renovascular hypertension: a meta-analysis. *Ann Intern Med* 2001; 135:401-411.
18. Vasbinder GB, Nelemans PJ, Kessels AG, et al. Accuracy of computed tomographic angiography and magnetic resonance angiography for diagnosing renal artery stenosis. *Ann Intern Med* 2004; 141:674-682.
19. Huot SJ, Hansson JH, Dey H, Concato J. Utility of captopril renal scans for detecting renal artery stenosis. *Arch Intern Med* 2002; 162:1981-1984.
20. Krijnen P, van Jaarsveld BC, Steyerberg EW, Man in 't Veld AJ, Schalekamp MA, Habbema JD. A clinical prediction rule for renal artery stenosis. *Ann Intern Med* 1998; 129:705-711.
21. Franklin SS, Smith RD. Comparison of effects of enalapril plus hydrochlorothiazide versus standard triple therapy on renal function in renovascular hypertension. *Am J Med* 1985; 79(3C):14-23.
22. Hollenberg NK. Medical therapy for renovascular hypertension: a review. *Am J Hypertens* 1988; 1:338S-343S.
23. Yusuf S, Sleight P, Pogue J, Bosch J, Davies R, Dagenais G. Effects of an angiotensin-converting-enzyme inhibitor, ramipril, on cardiovascular events in high-risk patients. The Heart Outcomes Prevention Evaluation Study Investigators [erratum appears in *N Engl J Med* 2000; 342:1376]. *N Engl J Med* 2000; 342:145-153.
24. Hricik DE, Browning PJ, Kopelman R, Goorno WE, Madias NE, Dzau VJ. Captopril-induced functional renal insufficiency in patients with bilateral renal-artery stenoses or renal-artery stenosis in a solitary kidney. *N Engl J Med* 1983; 308:373-376.
25. Textor SC. Renal failure related to angiotensin-converting enzyme inhibitors. *Semin Nephrol* 1997; 17:67-76.
26. Jackson B, Matthews PG, McGrath BP, Johnston CI. Angiotensin converting enzyme inhibition in renovascular hypertension: frequency of reversible renal failure. *Lancet* 1984; 1:225-226.
27. Ahmed A. Use of angiotensin-converting enzyme inhibitors in patients with heart failure and renal insufficiency: how concerned should we be by the rise in serum creatinine? *J Am Geriatr Soc* 2002; 50:1297-1300.
28. Palmer BF. Angiotensin-converting enzyme inhibitors and angiotensin receptor blockers: what to do if the serum creatinine and/or serum potassium concentration rises. *Nephrol Dial Transplant* 2003; 18:1973-1975.
29. van de Ven PJ, Beutler JJ, Kaatee R, Beek FJ, Mali WP, Koomans HA. Angiotensin converting enzyme inhibitor-induced renal dysfunction in atherosclerotic renovascular disease. *Kidney Int* 1998; 53:986-993.
30. Devoy MA, Tomson CR, Edmunds ME, Feehally J, Walls J. Deterioration in renal function associated with angiotensin converting enzyme inhibitor therapy is not always reversible. *J Intern Med* 1992; 232:493-498.
31. Veniant M, Heudes D, Clozel JP, Bruneval P, Menard J. Calcium blockade versus ACE inhibition in clipped and unclipped kidneys of 2K-1C rats. *Kidney Int* 1994; 46:421-429.
32. Bakris GL, Siomos M, Richardson D, et al. ACE inhibition or angiotensin receptor blockade: impact on potassium in renal failure. *Kidney Int* 2000; 58:2084-2092.
33. Khong TK, Missouris CG, Belli AM, MacGregor GA. Regression of atherosclerotic renal artery stenosis with aggressive lipid lowering therapy. *J Hum Hypertens* 2001; 15:431-433.
34. Sos TA, Pickering TG, Sniderman K, et al. Percutaneous transluminal renal angioplasty in renovascular hypertension due to atheroma or fibromuscular dysplasia. *N Engl J Med* 1983; 309:274-279.
35. Bell GM, Reid J, Buist TA. Percutaneous transluminal angioplasty improves blood pressure and renal function in renovascular hypertension. *Q J Med* 1987; 63:393-403.
36. Isles CG, Robertson S, Hill D. Management of renovascular disease: a review of renal artery stenting in ten studies. *Q J Med* 1999; 92:159-167.
37. Dorros G, Jaff M, Mathiak L, et al. Four-year follow-up of Palmaz-Schatz stent revascularization as treatment for atherosclerotic renal artery stenosis. *Circulation* 1998; 98:642-647.
38. van de Ven PJ, Kaatee R, Beutler JJ, et al. Arterial stenting and balloon angioplasty in ostial atherosclerotic renovascular disease: a randomised trial. *Lancet* 1999; 353:282-286.
39. Lamawansa MD, Bell R, Kumar A, House AK. Radiological predictors of response to renovascular reconstructive surgery. *Ann R Coll Surgeons Engl* 1995; 77:337-341.
40. Hansen KJ, Starr SM, Sands RE, Burkart JM, Plonk GW Jr, Dean RH. Contemporary surgical management of renovascular disease. *J*



- Vasc Surg 1992; 16:319–330.
41. **Cambria RP, Brewster DC, L'Italien GJ, et al.** Renal artery reconstruction for the preservation of renal function. *J Vasc Surg* 1996; 24:371–380.
  42. **Radermacher J, Chavan A, Bleck J, et al.** Use of Doppler ultrasonography to predict the outcome of therapy for renal-artery stenosis. *N Engl J Med* 2001; 344:410–417.
  43. **Dorros G, Jaff M, Jain A, Dufek C, Mathiak L.** Follow-up of primary Palmaz-Schatz stent placement for atherosclerotic renal artery stenosis. *Am J Cardiol* 1995; 75:1051–1055.
  44. **Harden PN, MacLeod MJ, Rodger RS, et al.** Effect of renal-artery stenting on progression of renovascular renal failure. *Lancet* 1997; 349:1133–1136.
  45. **Gami AS, Garovic VD.** Contrast nephropathy after coronary angiography [erratum appears in *Mayo Clin Proc* 2004; 79:432]. *Mayo Clin Proc* 2004; 79:211–219.
  46. **Pohl MA, Novick AC.** Natural history of atherosclerotic and fibrous renal artery disease: clinical implications. *Am J Kidney Dis* 1985; 5:A120–A130.
  47. **Plouin PF, Chatellier G, Darne B, Raynaud A.** Blood pressure outcome of angioplasty in atherosclerotic renal artery stenosis: a randomized trial. *Essai Multicentrique Medicaments vs Angioplastie (EMMA) Study Group. Hypertension* 1998; 31:823–829.
  48. **van Jaarsveld BC, Krijnen P, Pieterman H, et al.** The effect of balloon angioplasty on hypertension in atherosclerotic renal-artery stenosis. *Dutch Renal Artery Stenosis Intervention Cooperative Study Group. N Engl J Med* 2000; 342:1007–1014.
  49. **Webster J, Marshall F, Abdalla M, et al.** Randomised comparison of percutaneous angioplasty vs continued medical therapy for hypertensive patients with atheromatous renal artery stenosis. *Scottish and Newcastle Renal Artery Stenosis Collaborative Group. J Hum Hypertens* 1998; 12:329–335.
  50. **Nordmann AJ, Woo K, Parkes R, Logan AG.** Balloon angioplasty or medical therapy for hypertensive patients with atherosclerotic renal artery stenosis? A meta-analysis of randomized controlled trials. *Am J Med* 2003; 114:44–50.
  51. **Ives NJ, Wheatley K, Stowe RL, et al.** Continuing uncertainty about the value of percutaneous revascularization in atherosclerotic renovascular disease: a meta-analysis of randomized trials. *Nephrol Dial Transplant* 2003; 18:298–304.
  52. **Oliveira GH, Garovic VD.** 23-year-old man with hypertension and flank trauma. *Mayo Clin Proc* 2002; 77:1229–1232.
  53. **Bunchman TE, Sinaiko AR.** Renovascular hypertension presenting with hypokalemic metabolic alkalosis. *Pediatr Nephrol* 1990; 4:169–170.
  54. **Rudnick MR, Maxwell MM.** Limitations of renin assays. In: Narins RG, editor. *Controversies in Nephrology and Hypertension*. New York: Churchill Livingstone; 1984:123–160.
  55. **Kane GC, Textor SC, Schirger A, Garovic VD.** Revisiting the role of nephrectomy for advanced renovascular disease. *Am J Med* 2003; 114:729–735.
- 
- ADDRESS:** Vesna D. Garovic, MD, Division of Nephrology and Hypertension, Mayo Clinic, 200 First Street SW, Rochester, MN 55905; e-mail [garovic.vesna@mayo.edu](mailto:garovic.vesna@mayo.edu).